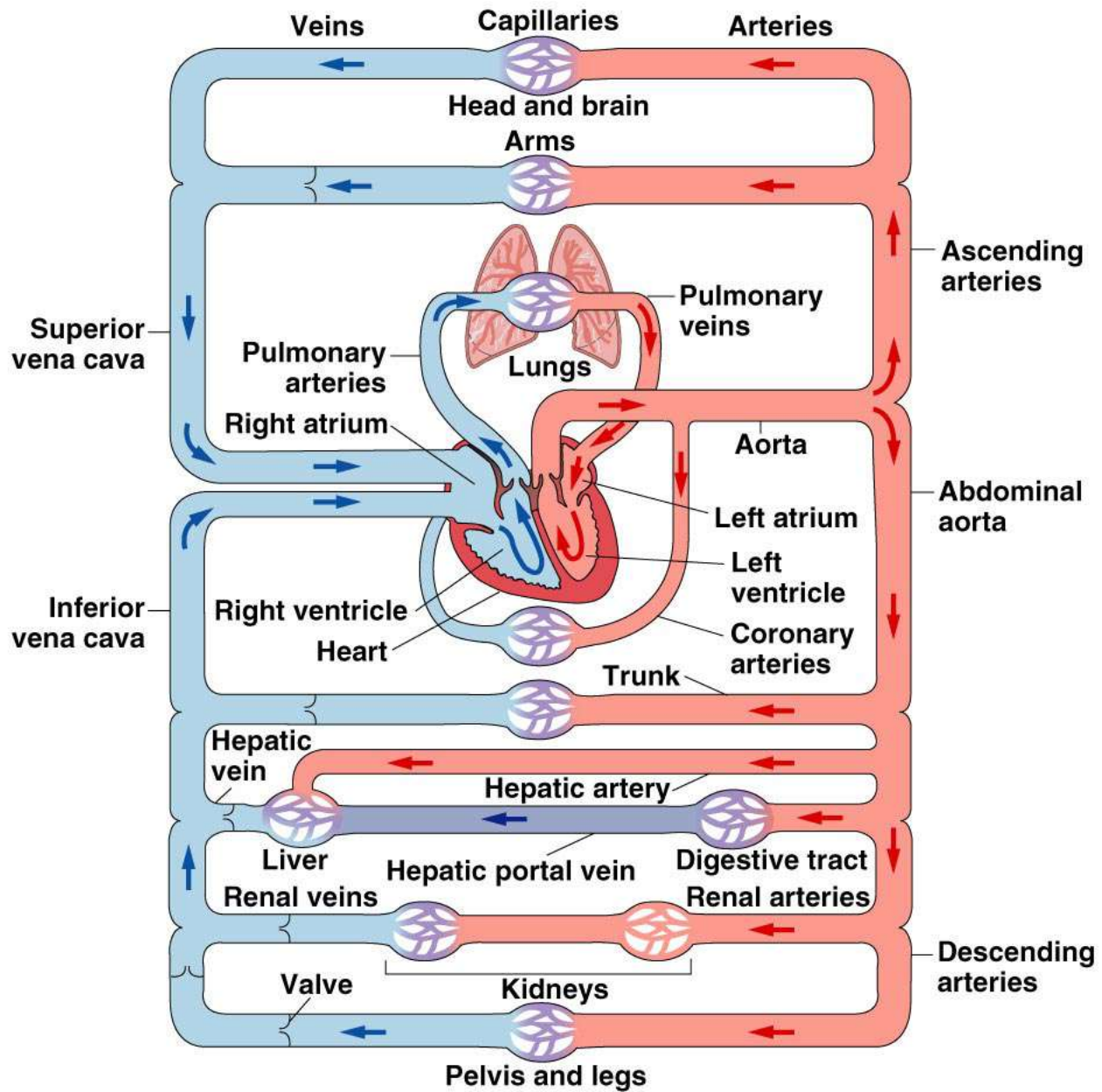
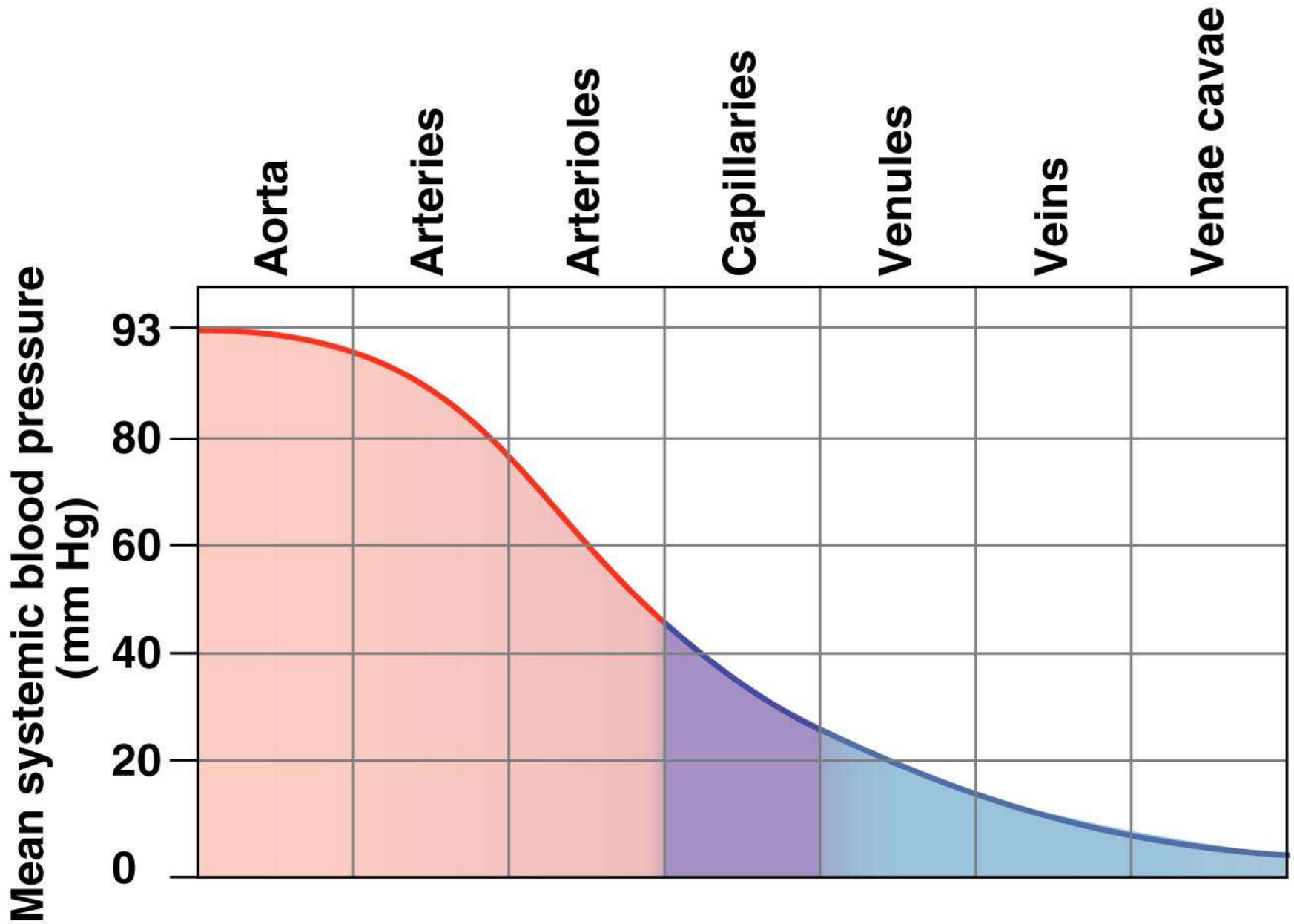


HEART

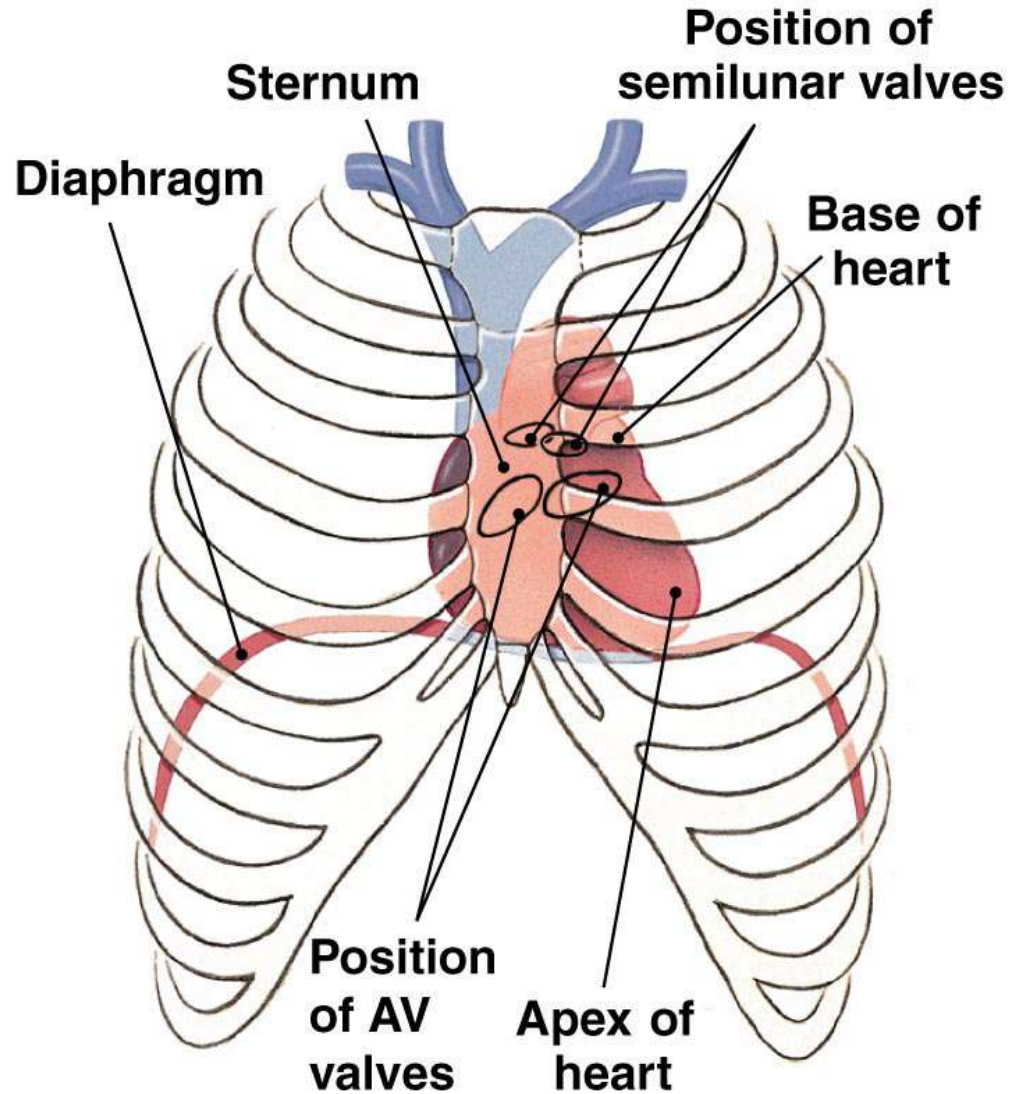


Copyright © 2007 Pearson Education, Inc., publishing as Benjamin Cummings.

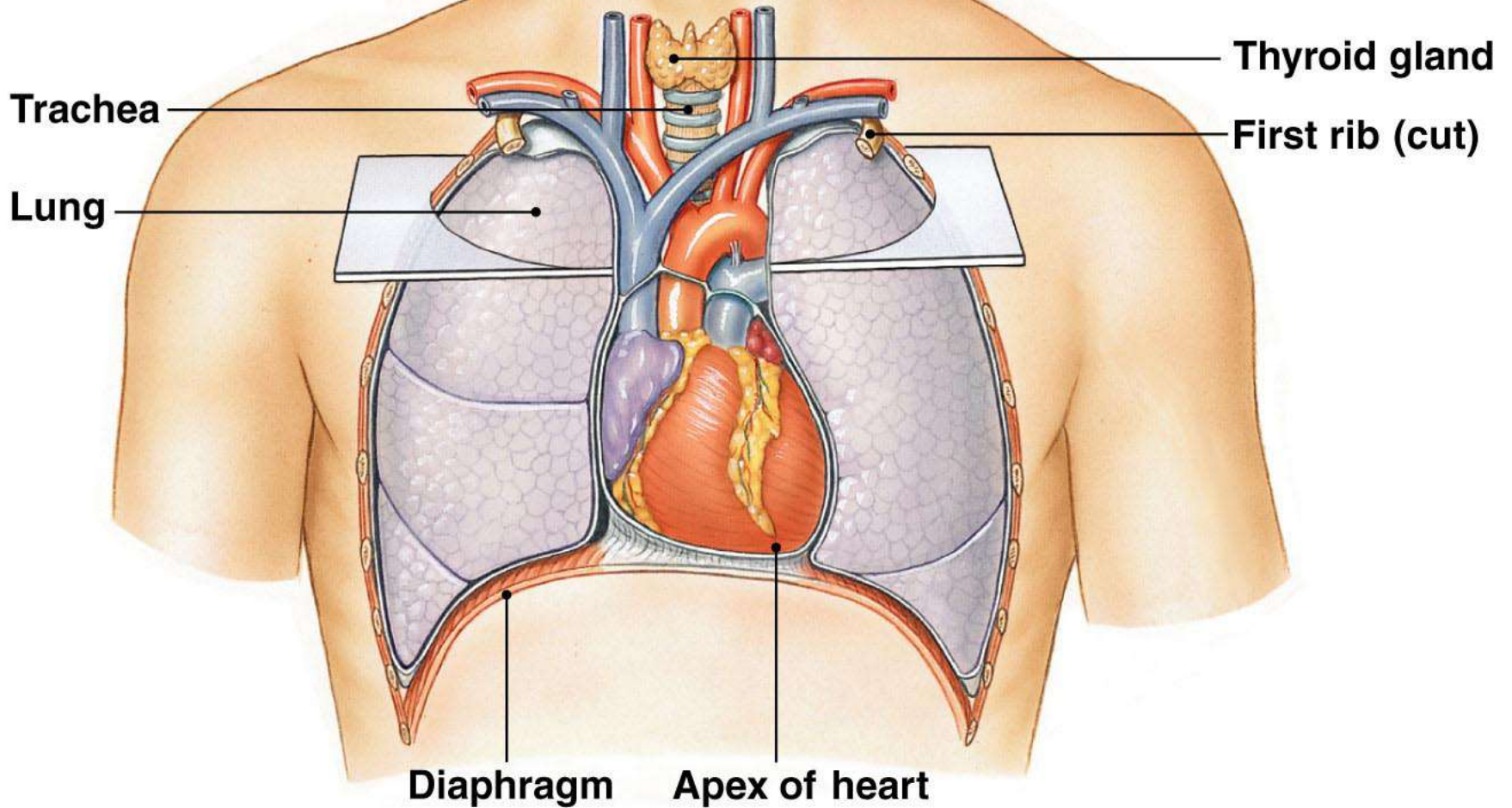
Figure 14-1



(a) The heart lies in the center of the thorax.



(b)

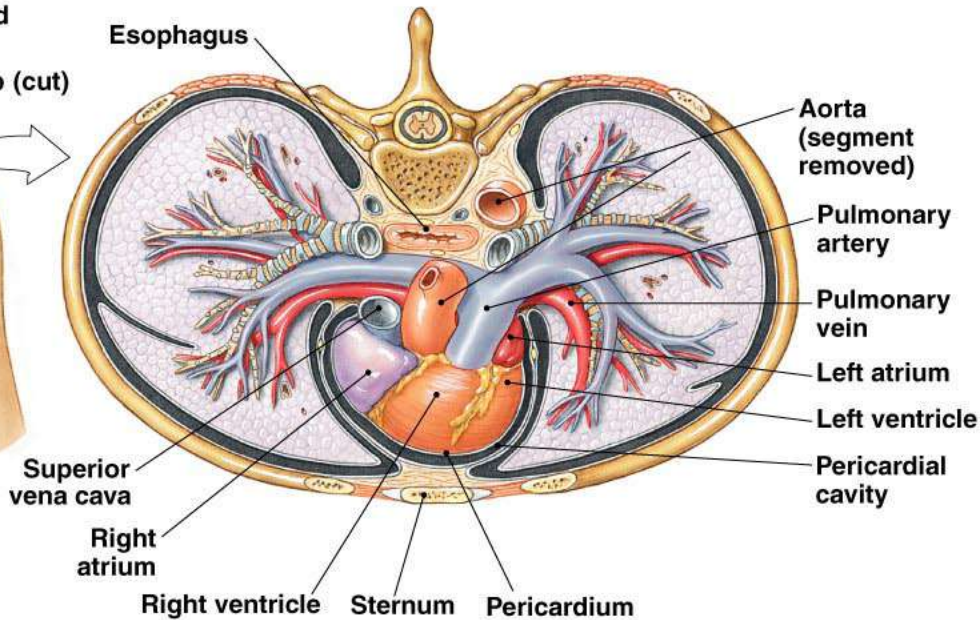
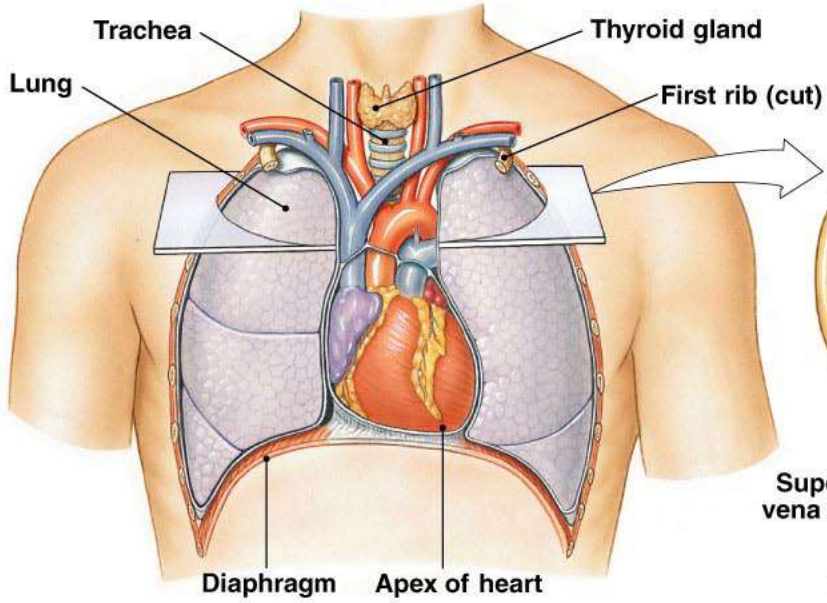


The heart is on the ventral side of the thoracic cavity, sandwiched between the lungs.

Copyright © 2007 Pearson Education, Inc., publishing as Benjamin Cummings.

Figure 14-7b

(b) **(d) Superior view of transverse plane in (b)**

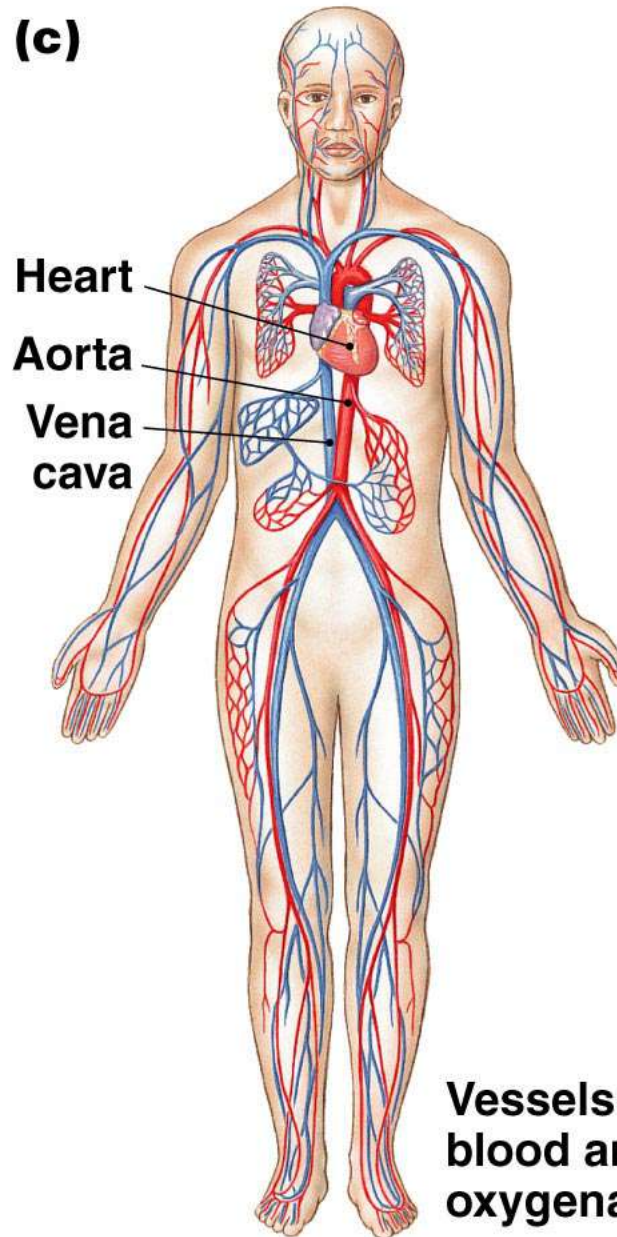


The heart is on the ventral side of the thoracic cavity, sandwiched between the lungs.

Copyright © 2007 Pearson Education, Inc., publishing as Benjamin Cummings.

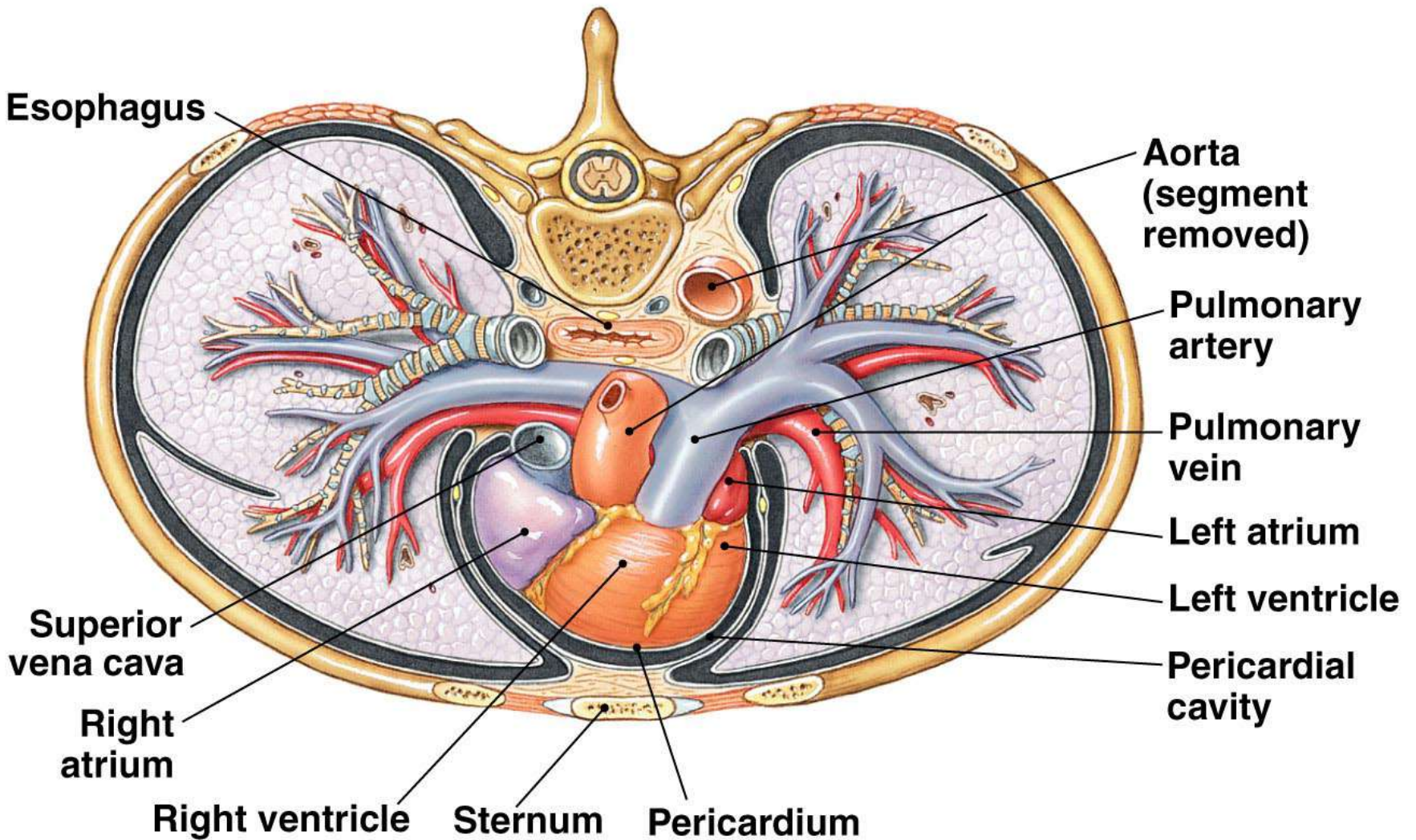
Figure 14-7b,d

(c)



Vessels that carry well-oxygenated blood are red; those with less well-oxygenated blood are blue.

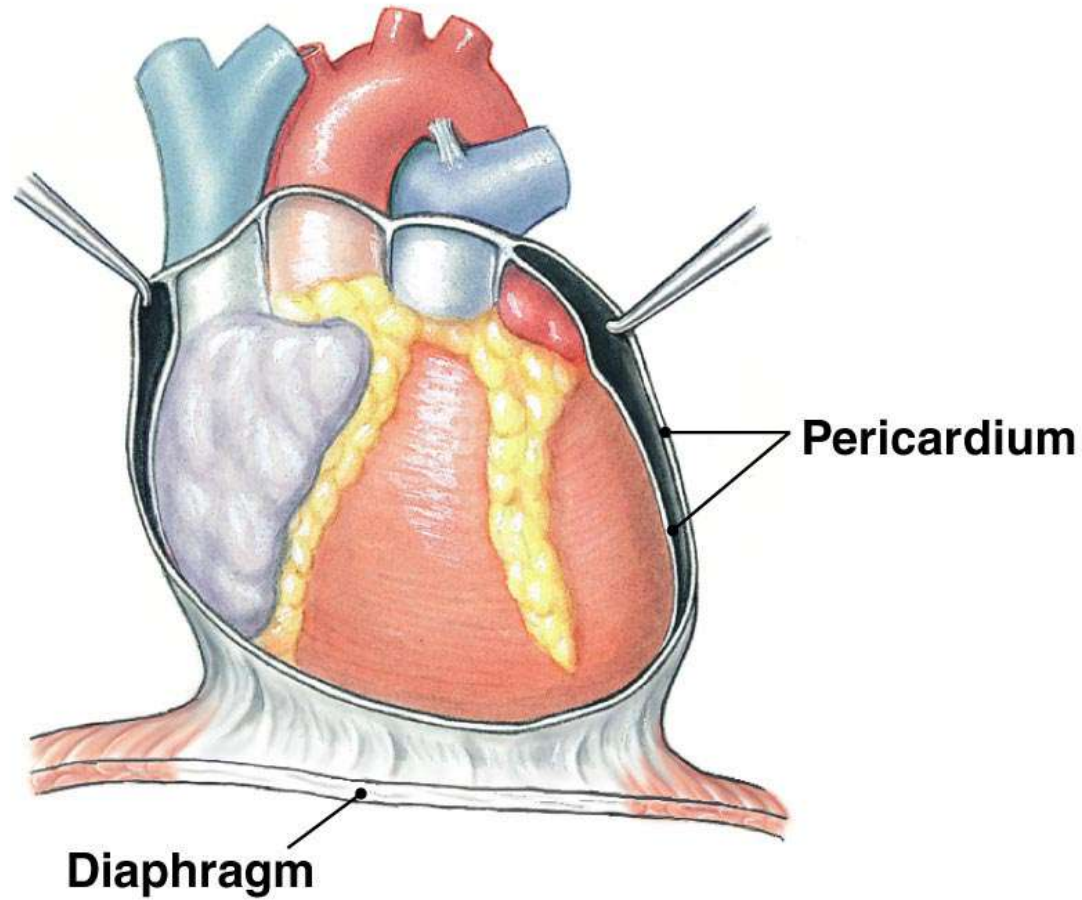
(d) Superior view of transverse plane in (b)



Copyright © 2007 Pearson Education, Inc., publishing as Benjamin Cummings.

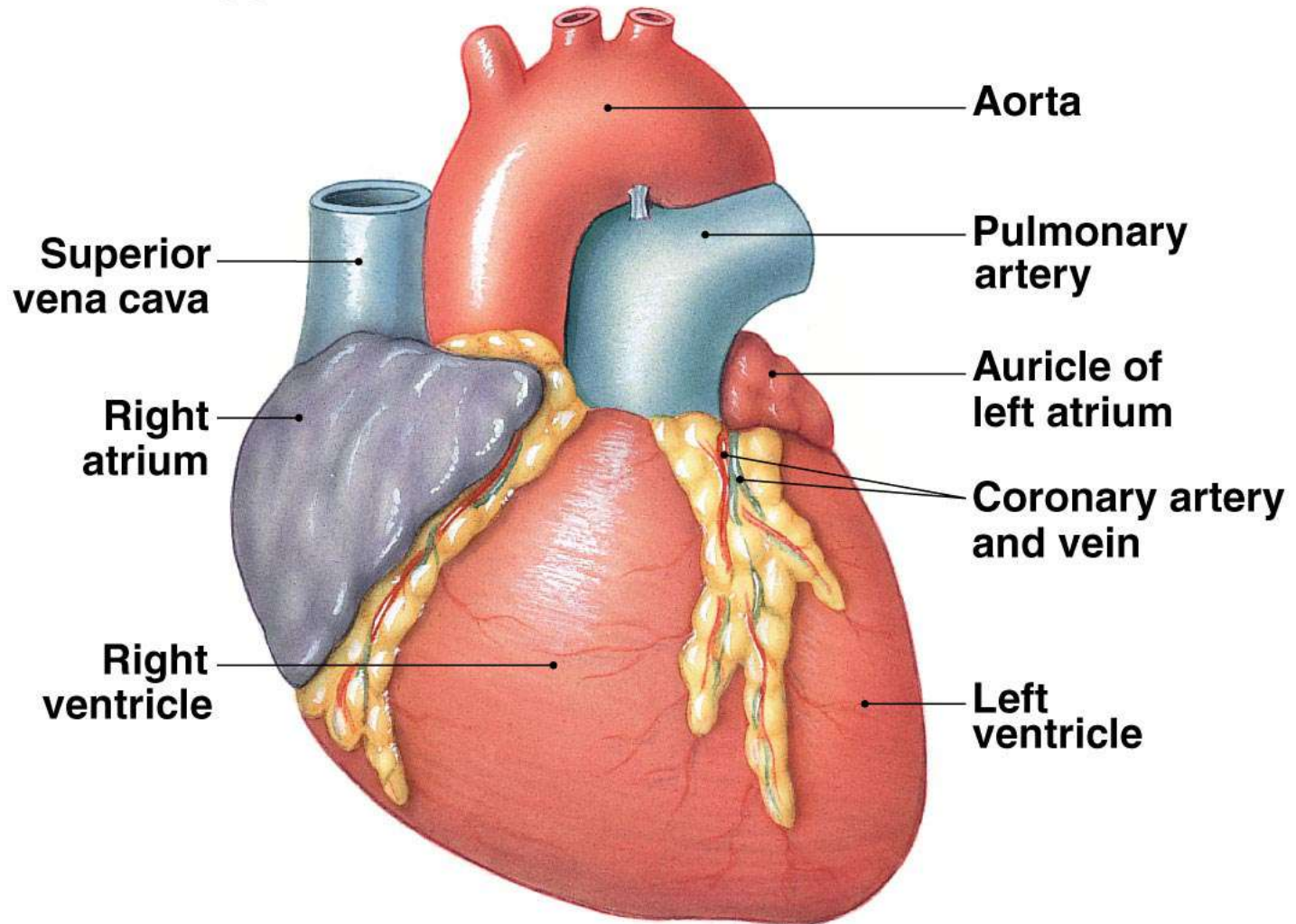
Figure 14-7d

(e)

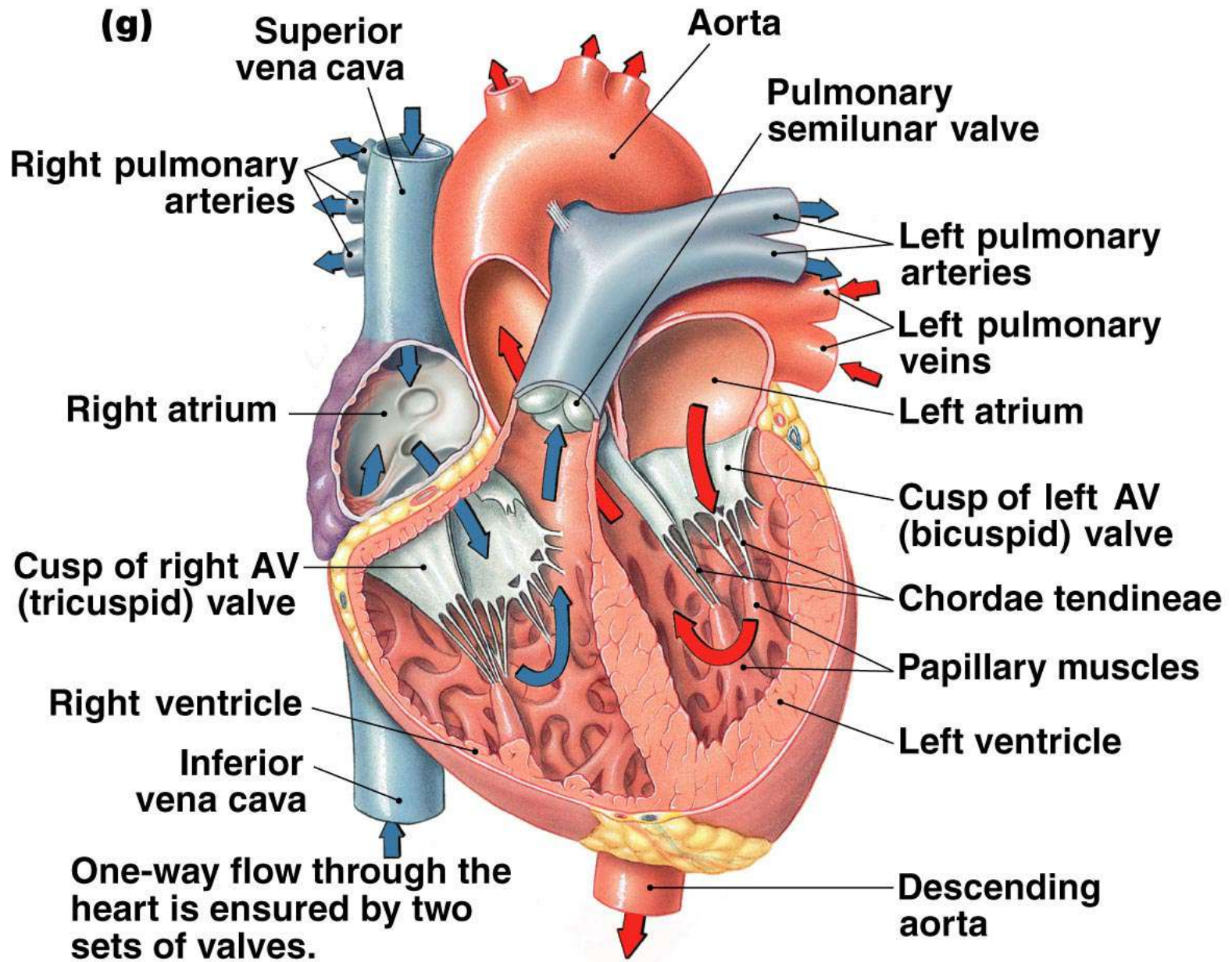


The heart is encased within a membranous fluid-filled sac, the pericardium.

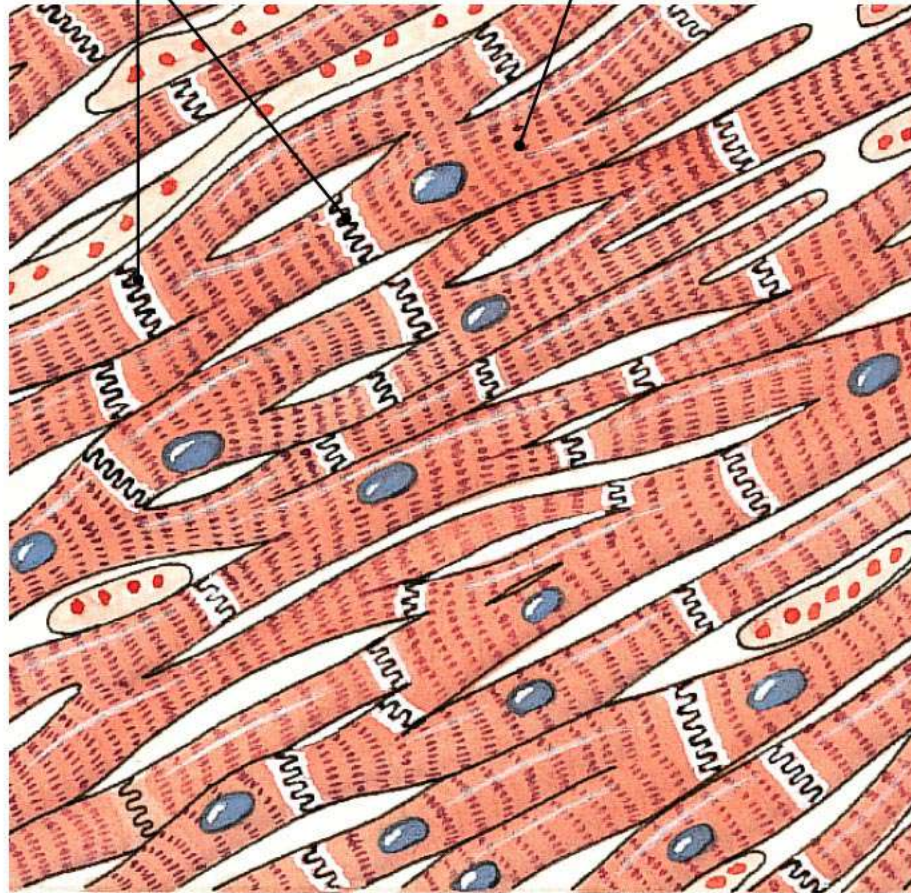
(f)



The ventricles occupy the bulk of the heart. The arteries and veins all attach to the base of the heart.



(h) Intercalated disks Myocardial muscle cell



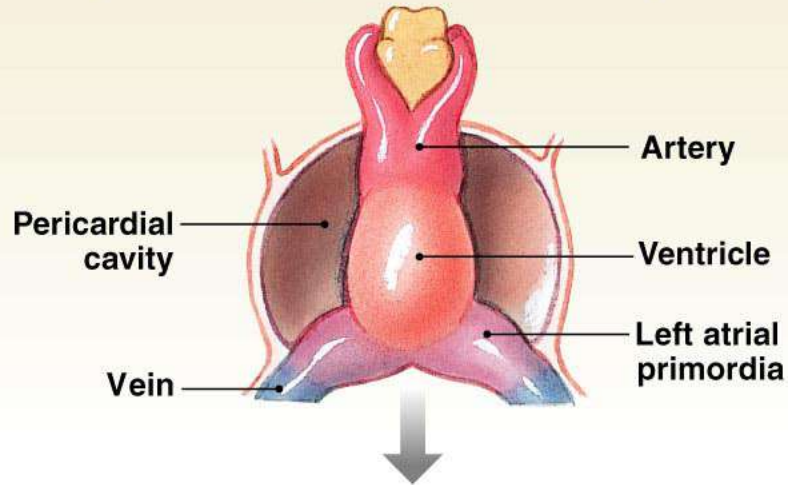
Myocardial muscle cells are branched, have a single nucleus, and are attached to each other by specialized junctions known as intercalated disks.

TABLE 14-2 The Heart and Major Blood Vessels

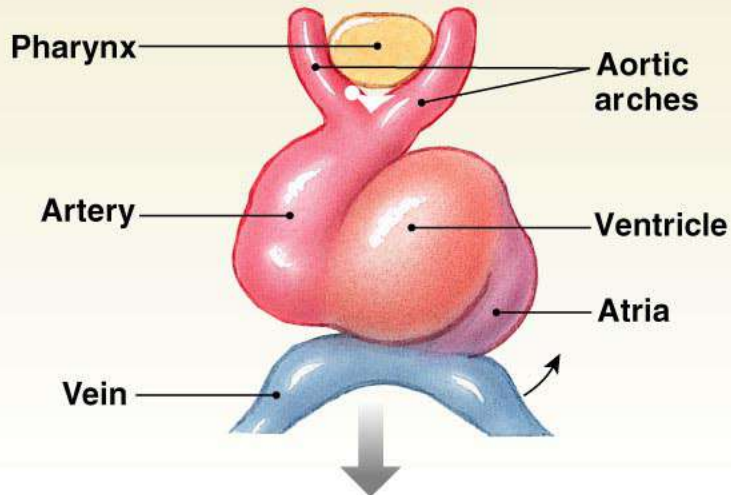
Blue type indicates structures containing blood with lower oxygen content; red type indicates well-oxygenated blood.

	RECEIVES BLOOD FROM	SENDS BLOOD TO
Heart		
Right atrium Right ventricle	Venae cavae Right atrium	Right ventricle Lungs
Left atrium Left ventricle	Pulmonary veins Left atrium	Left ventricle Body except for lungs
Vessels		
Venae cavae Pulmonary trunk (artery)	Systemic veins Right ventricle	Right atrium Lungs
Pulmonary vein Aorta	Veins of the lungs Left ventricle	Left atrium Systemic arteries

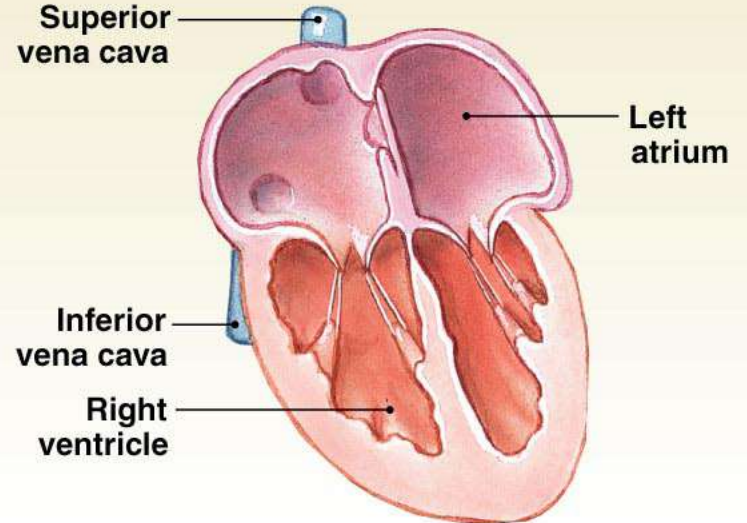
(a) Age: embryo, day 25. The heart is a single tube.



(b) By four weeks of development, the atria and ventricles can be distinguished. The heart begins to twist so that the atria move on top of the ventricles.

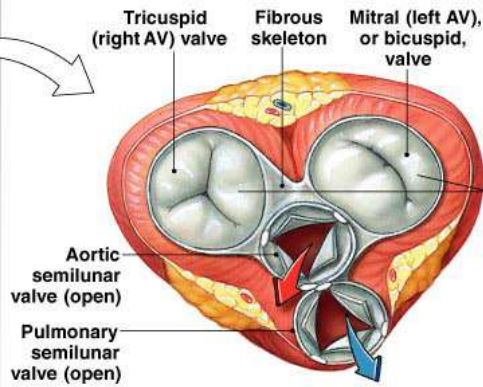


(c) Age: one year (arteries not shown)

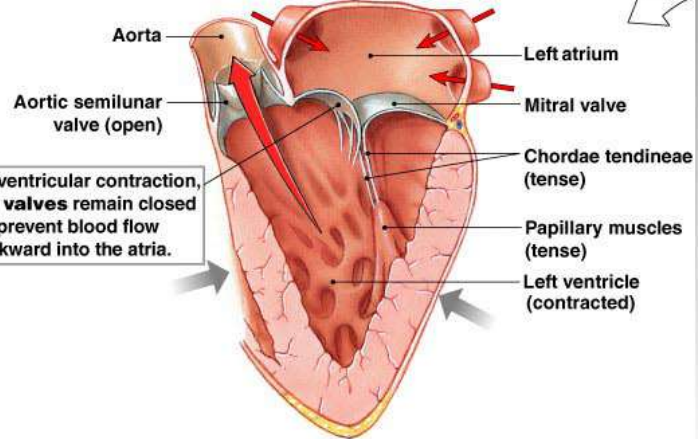


VENTRICULAR CONTRACTION

(a) Transverse section

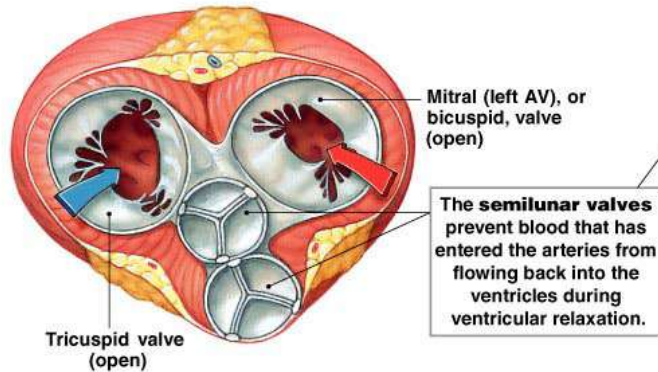


(b) Frontal section

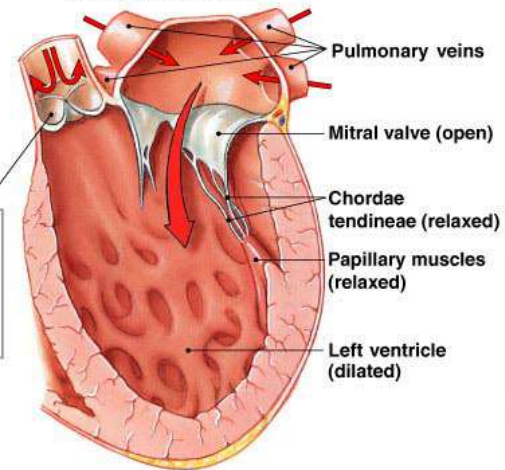


VENTRICULAR RELAXATION

(c) Transverse section



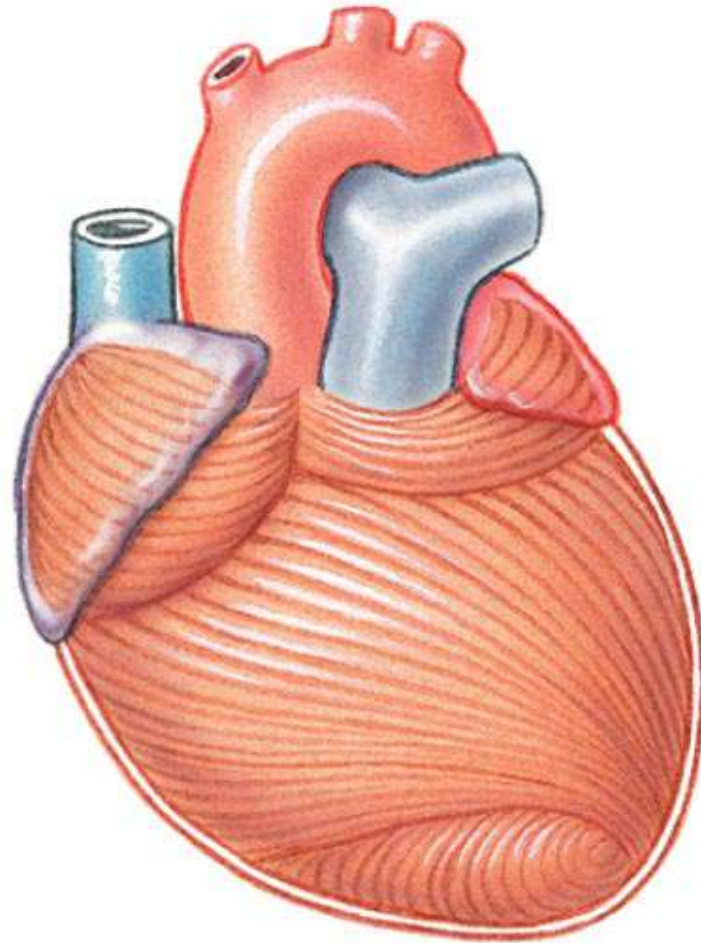
(d) Frontal section



Copyright © 2007 Pearson Education, Inc., publishing as Benjamin Cummings.

Figure 14-9 - Overview

(a) The spiral arrangement of ventricular muscle allows ventricular contraction to squeeze the blood upward from the apex of the heart.



Copyright © 2007 Pearson Education, Inc., publishing as Benjamin Cummings.

Figure 14-10a

(b) Intercalated disks contain desmosomes that transfer force from cell to cell and gap junctions that allow electrical signals to pass rapidly from cell to cell.

Intercalated disk (sectioned)

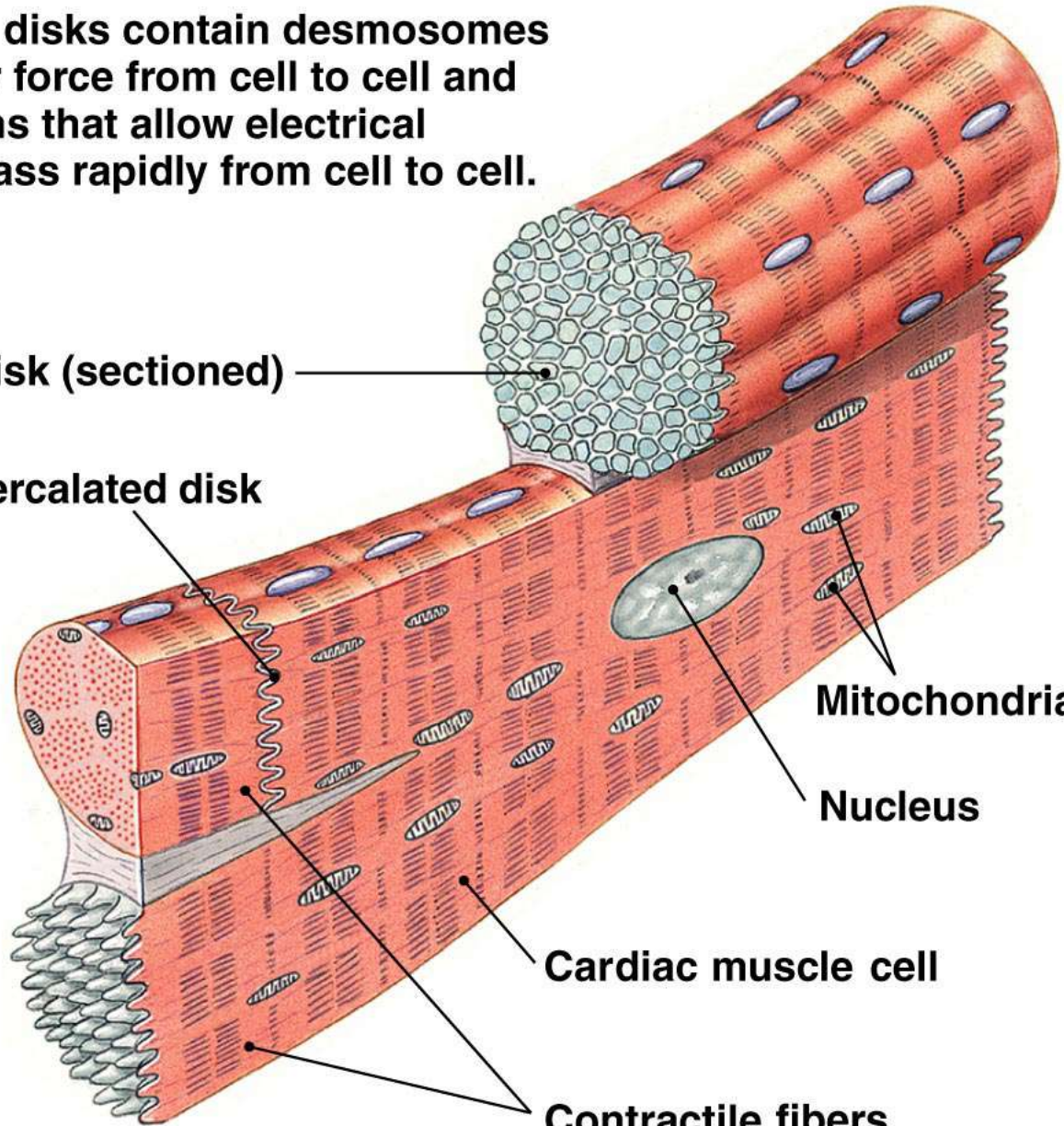
Intercalated disk

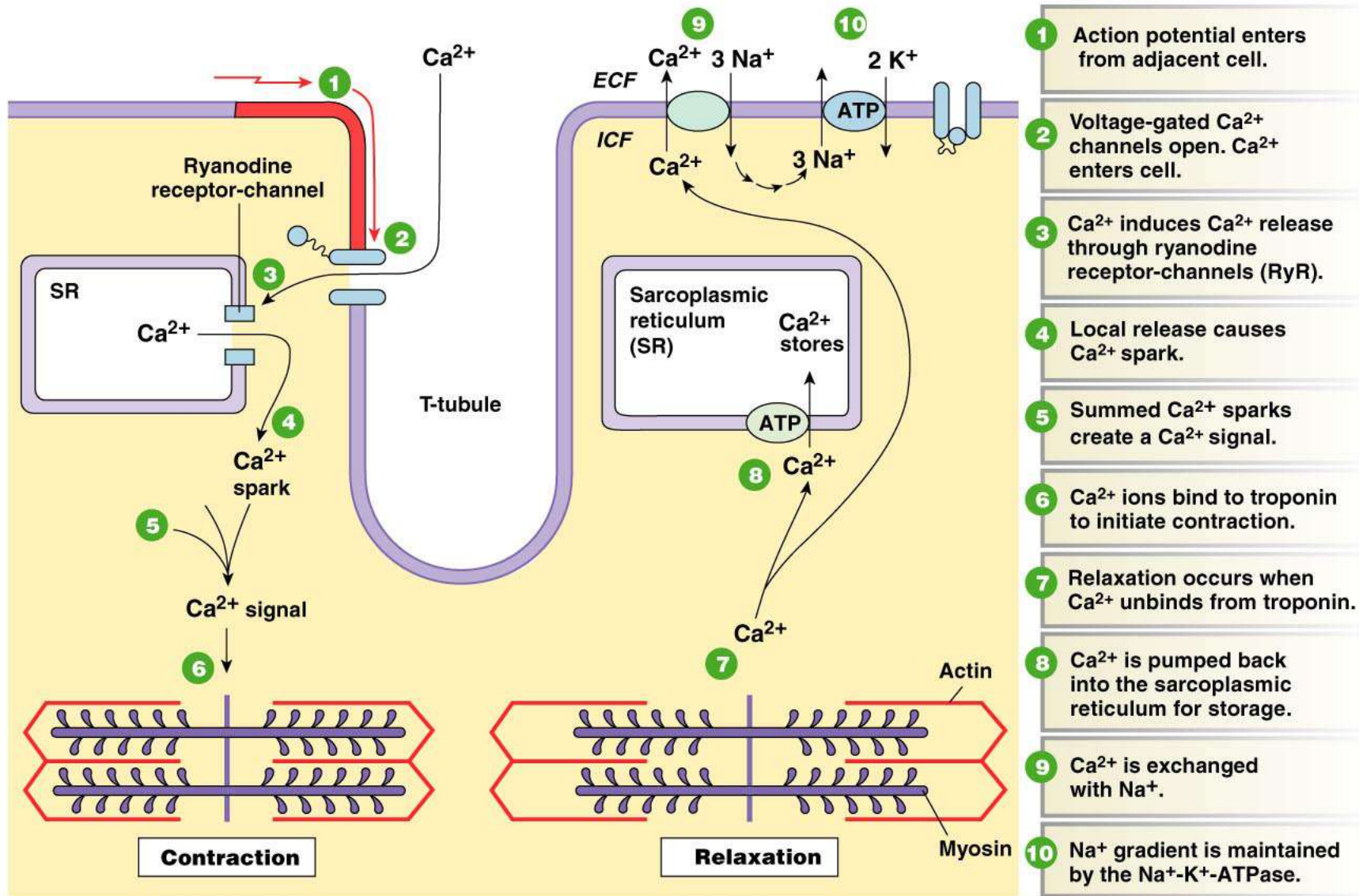
Mitochondria

Nucleus

Cardiac muscle cell

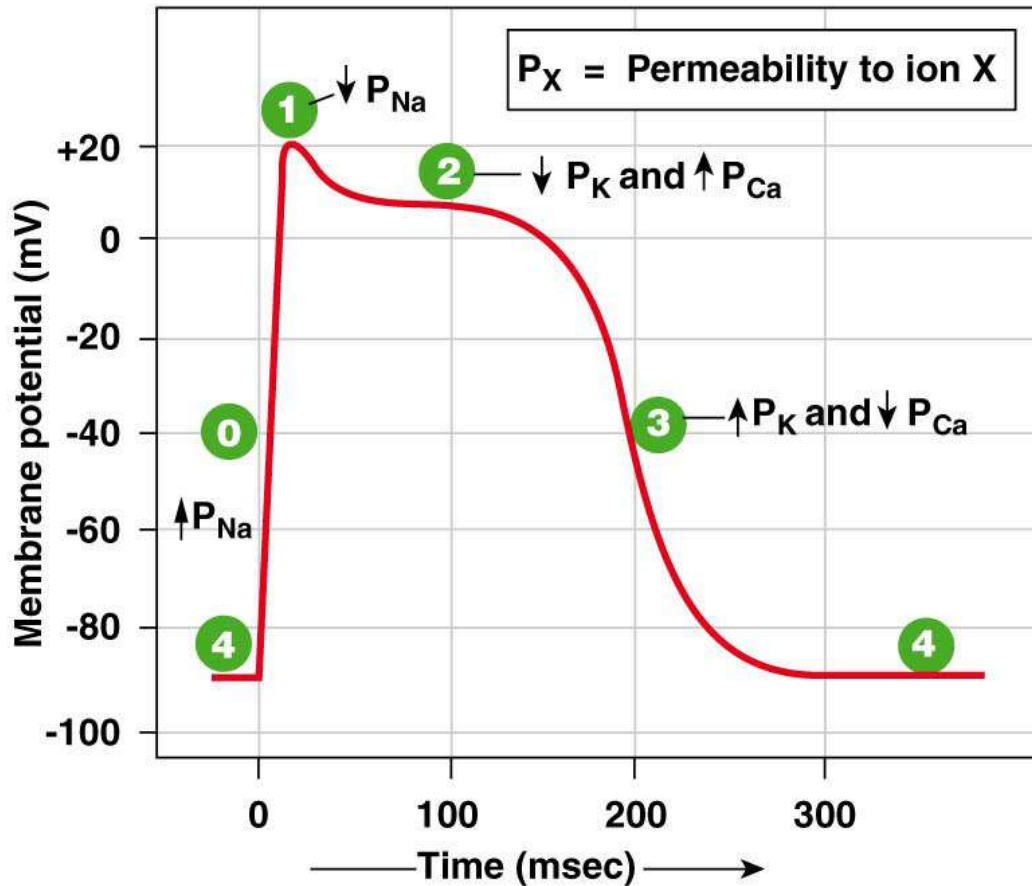
Contractile fibers





- 1 Action potential enters from adjacent cell.
- 2 Voltage-gated Ca²⁺ channels open. Ca²⁺ enters cell.
- 3 Ca²⁺ induces Ca²⁺ release through ryanodine receptor-channels (RyR).
- 4 Local release causes Ca²⁺ spark.
- 5 Summed Ca²⁺ sparks create a Ca²⁺ signal.
- 6 Ca²⁺ ions bind to troponin to initiate contraction.
- 7 Relaxation occurs when Ca²⁺ unbinds from troponin.
- 8 Ca²⁺ is pumped back into the sarcoplasmic reticulum for storage.
- 9 Ca²⁺ is exchanged with Na⁺.
- 10 Na⁺ gradient is maintained by the Na⁺-K⁺-ATPase.

Figure 14-11 - Overview

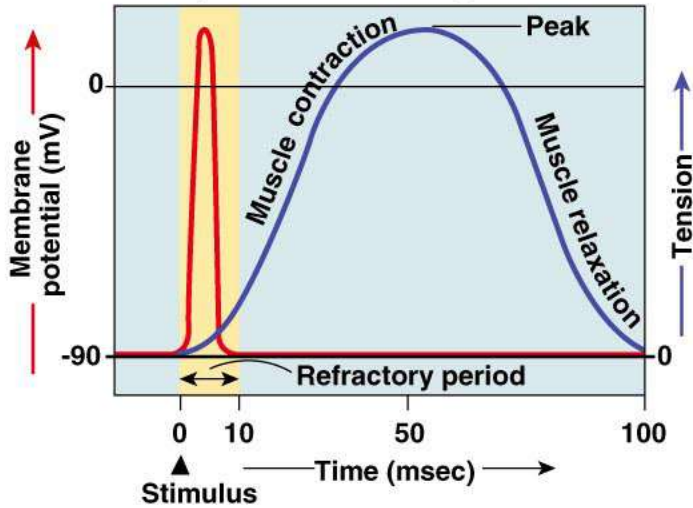


Phase	Membrane channels
0	Na^+ channels open
1	Na^+ channels close
2	Ca^{2+} channels open; fast K^+ channels close
3	Ca^{2+} channels close; slow K^+ channels open
4	Resting potential

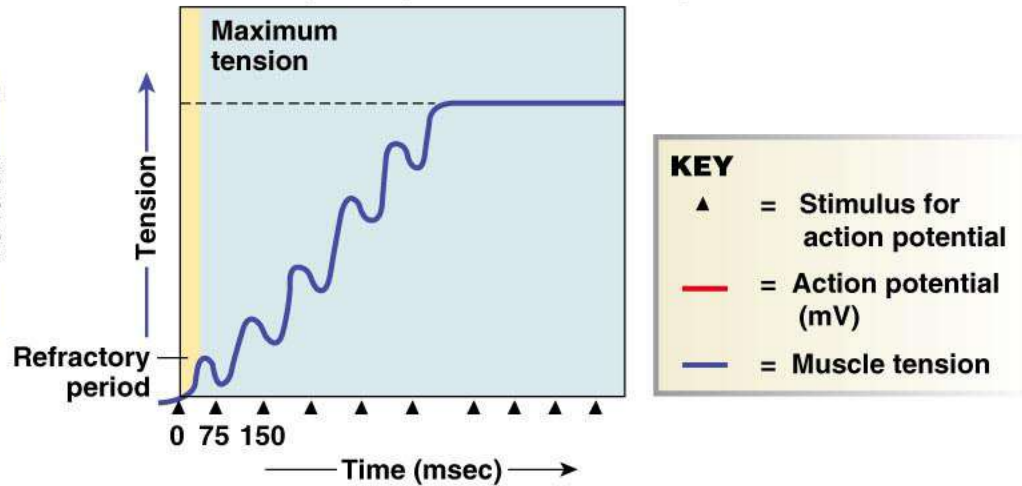
Copyright © 2007 Pearson Education, Inc., publishing as Benjamin Cummings.

Figure 14-13

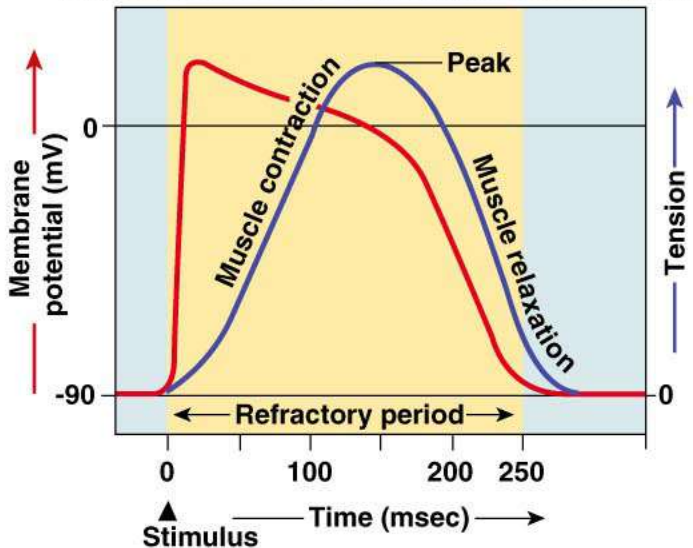
(a) Skeletal muscle fast-twitch fiber: The refractory period (yellow) is very short compared with the amount of time required for the development of tension.



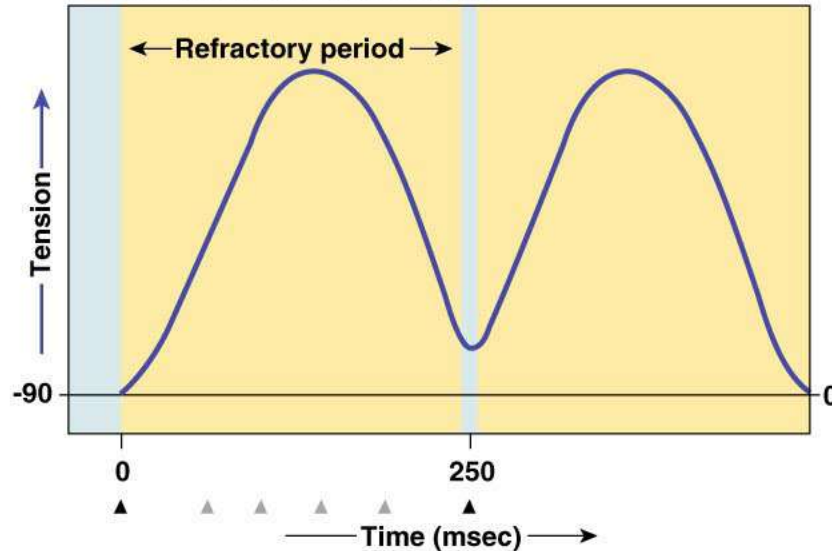
(b) Skeletal muscles that are stimulated repeatedly will exhibit summation and tetanus (action potentials not shown).



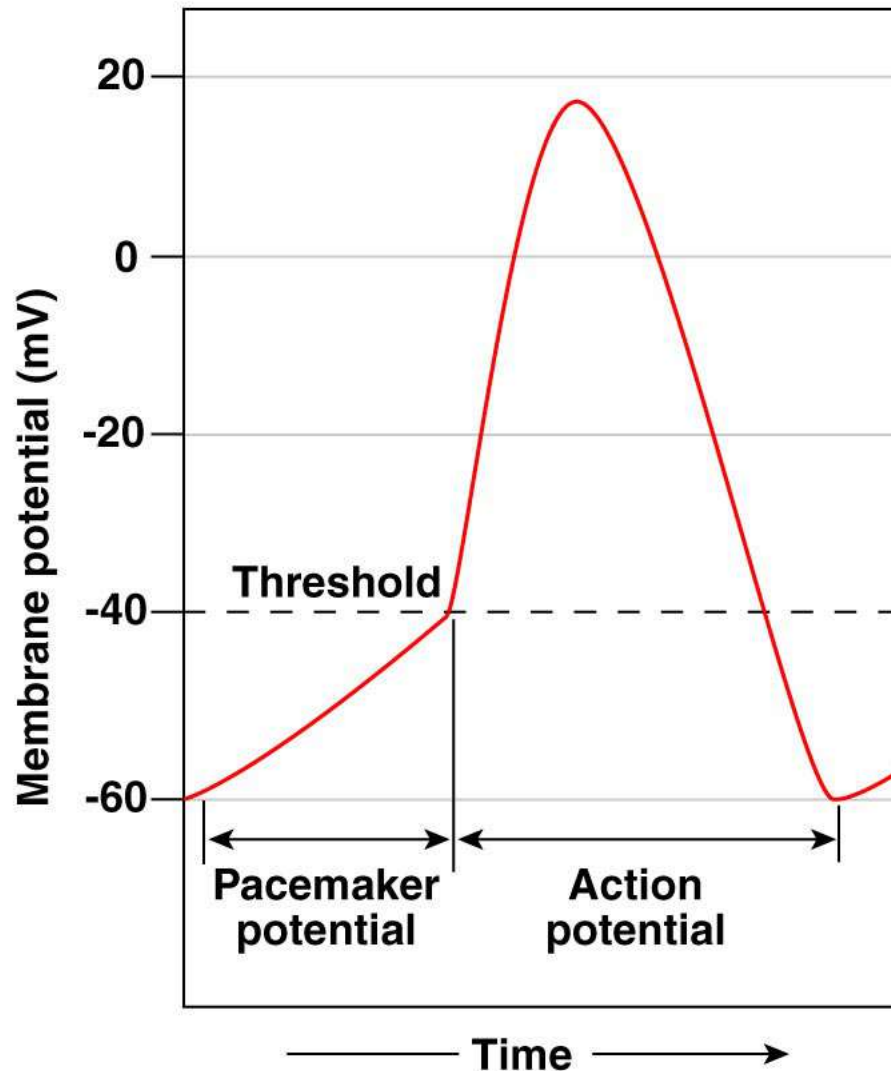
(c) Cardiac muscle fiber: The refractory period lasts almost as long as the entire muscle twitch.



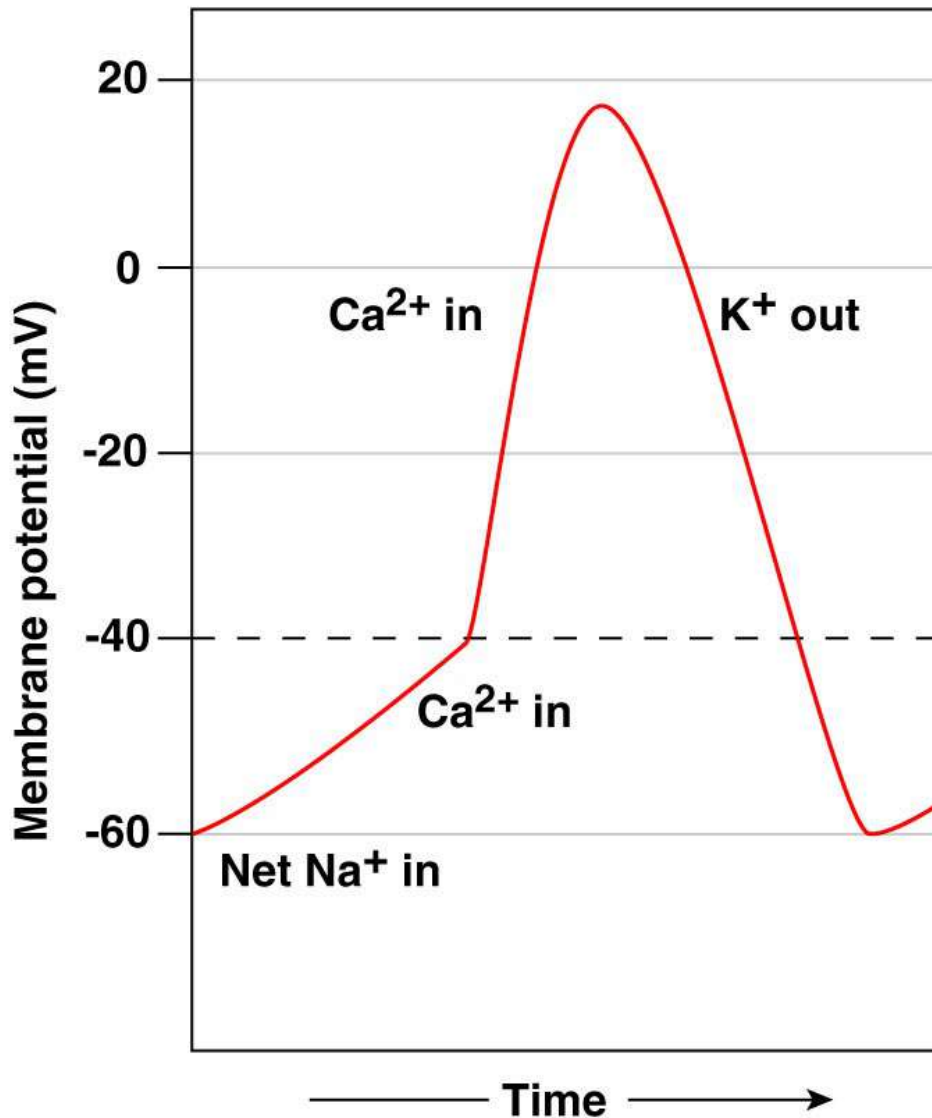
(d) Long refractory period in a cardiac muscle prevents tetanus.



(a) The pacemaker potential gradually becomes less negative until it reaches threshold, triggering an action potential.



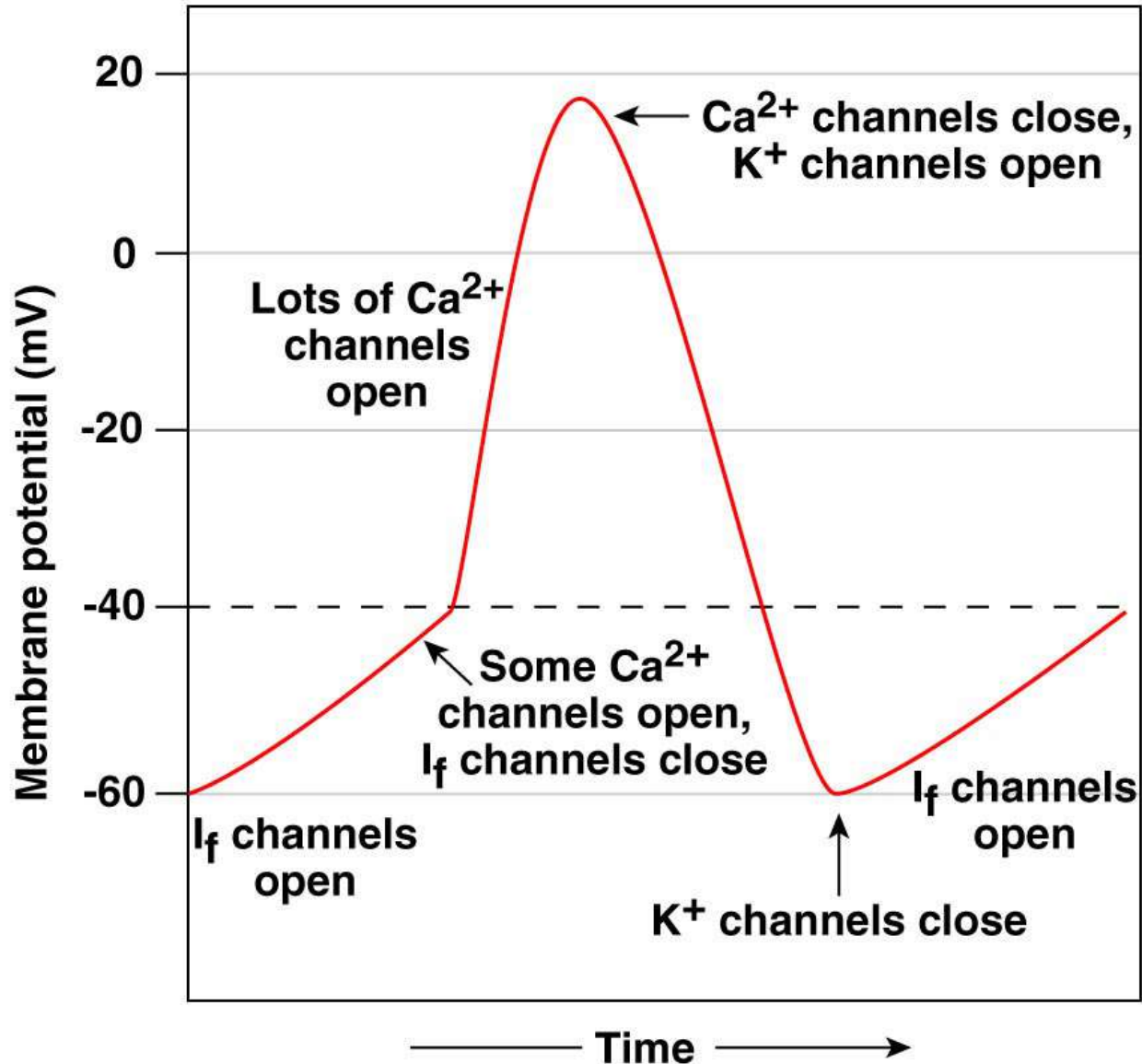
(b) Ion movements during an action and pacemaker potential



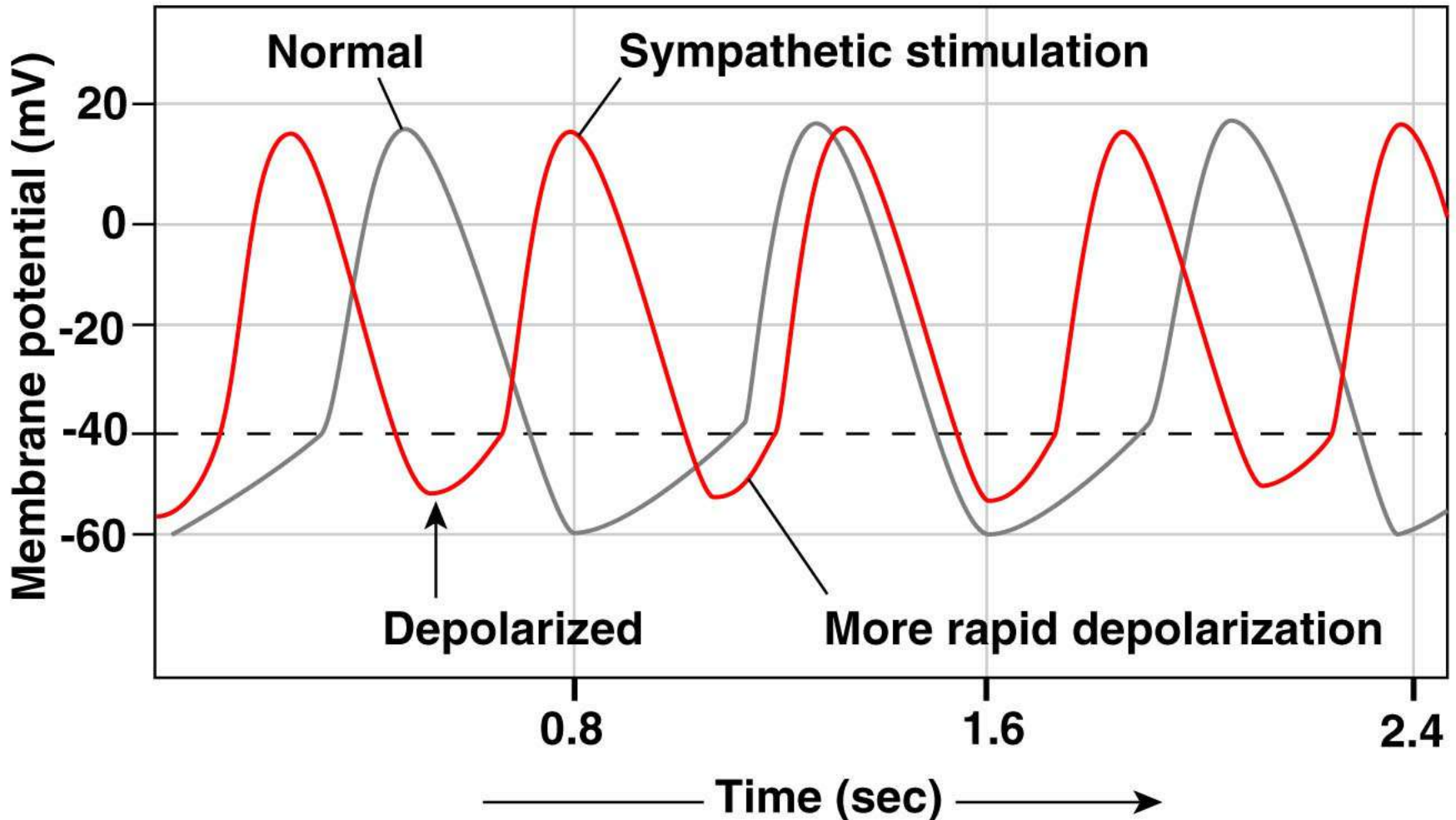
Copyright © 2007 Pearson Education, Inc., publishing as Benjamin Cummings.

Figure 14-15b

(c) States of various ion channels



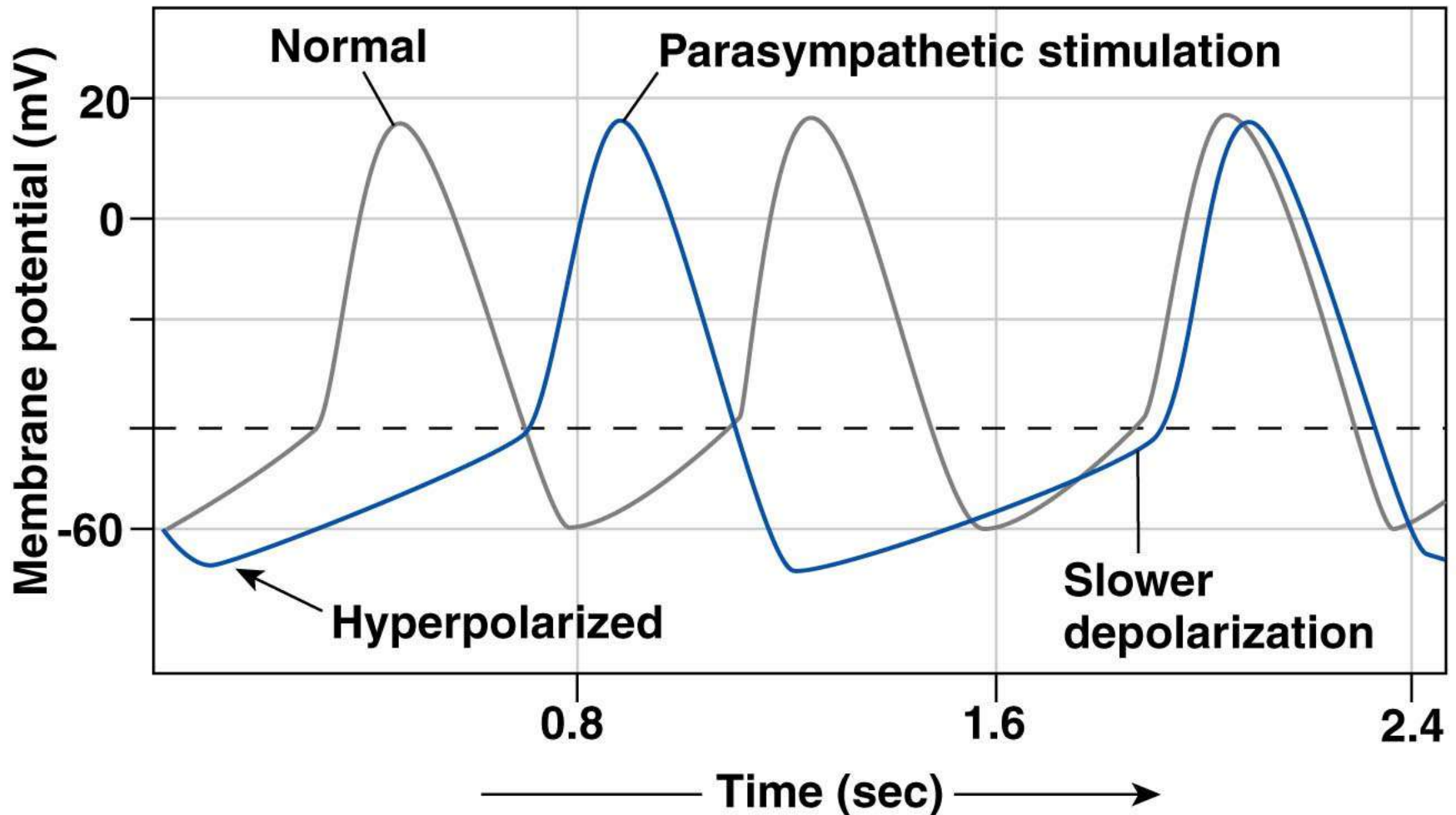
(a) Sympathetic stimulation and epinephrine depolarize the autorhythmic cell and speed up the depolarization rate, increasing the heart rate.



Copyright © 2007 Pearson Education, Inc., publishing as Benjamin Cummings.

Figure 14-16a

(b) Parasympathetic stimulation hyperpolarizes the membrane potential of the autorhythmic cell and slows depolarization, decreasing the heart rate.



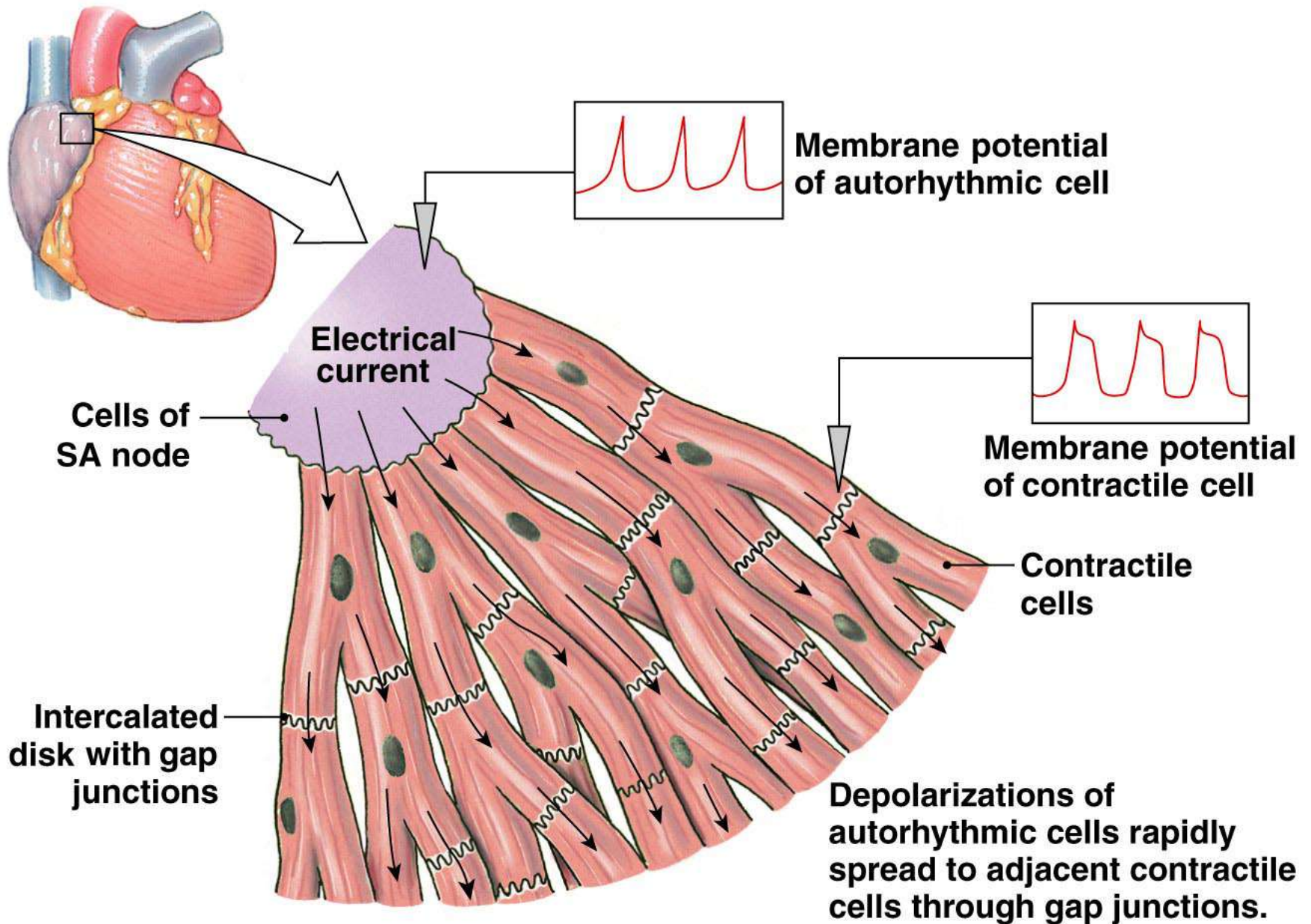
Copyright © 2007 Pearson Education, Inc., publishing as Benjamin Cummings.

Figure 14-16b

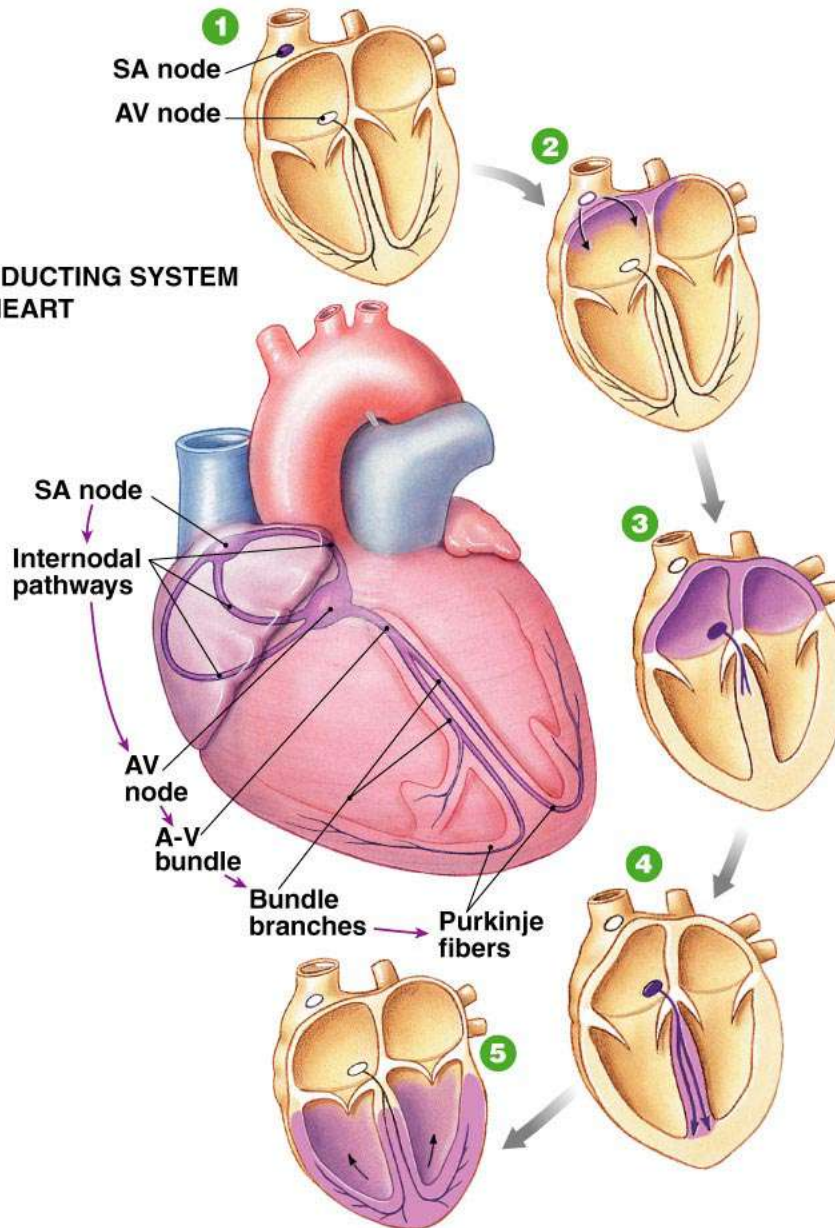
TABLE 14-3 Comparison of Action Potentials in Cardiac and Skeletal Muscle

	SKELETAL MUSCLE	CONTRACTILE MYOCARDIUM	AUTORHYTHMIC MYOCARDIUM
Membrane potential	Stable at -70 mV	Stable at -90 mV	Unstable pacemaker potential; usually starts at -60 mV
Events leading to threshold potential	Net Na^+ entry through ACh-operated channels	Depolarization enters via gap junctions	Net Na^+ entry through I_f channels; reinforced by Ca^{2+} entry
Rising phase of action potential	Na^+ entry	Na^+ entry	Ca^{2+} entry
Repolarization phase	Rapid; caused by K^+ efflux	Extended plateau caused by Ca^{2+} entry; rapid phase caused by K^+ efflux	Rapid; caused by K^+ efflux
Hyperpolarization	Due to excessive K^+ efflux at high K^+ permeability when K^+ channels close; leak of K^+ and Na^+ restores potential to resting state	None; resting potential is -90 mV, the equilibrium potential for K^+	None; when repolarization hits -60 mV, the I_f channels open again
Duration of action potential	Short: 1–2 msec	Extended: 200+ msec	Variable; generally 150+ msec
Refractory period	Generally brief	Long because resetting of Na^+ channel gates delayed until end of action potential	None

Copyright © 2007 Pearson Education, Inc., publishing as Benjamin Cummings.



THE CONDUCTING SYSTEM OF THE HEART



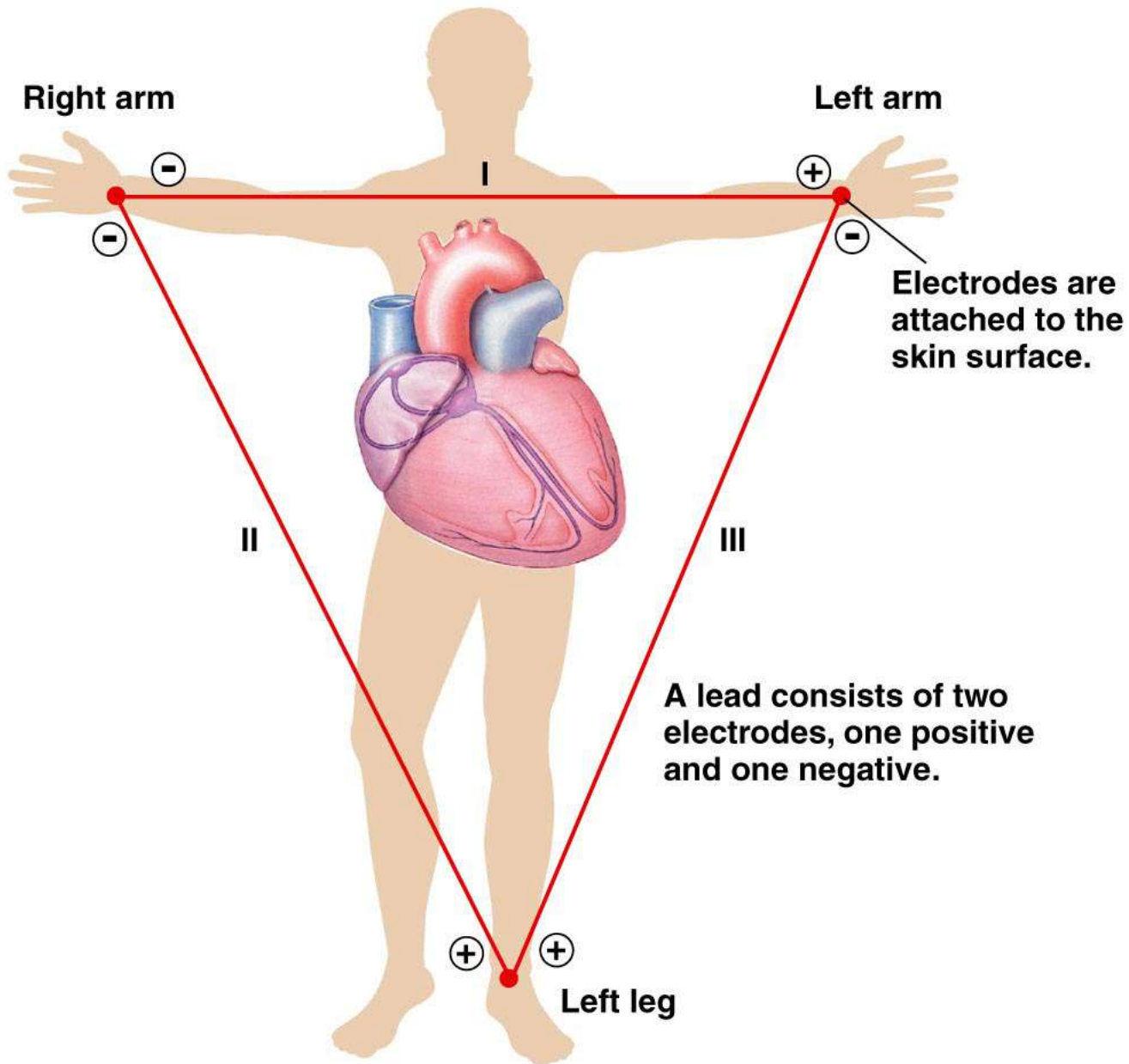
1 SA node depolarizes.

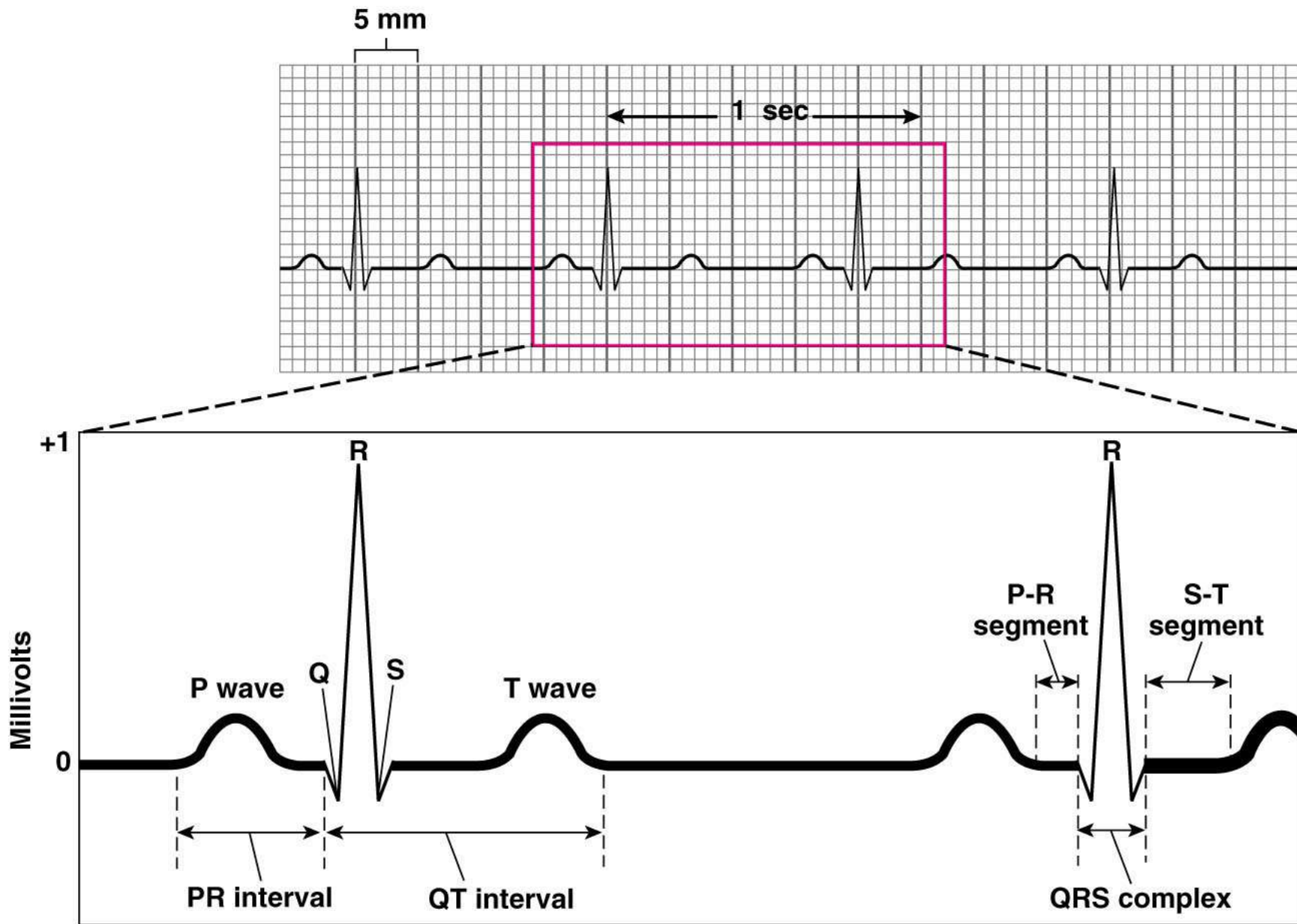
2 Electrical activity goes rapidly to AV node via internodal pathways.

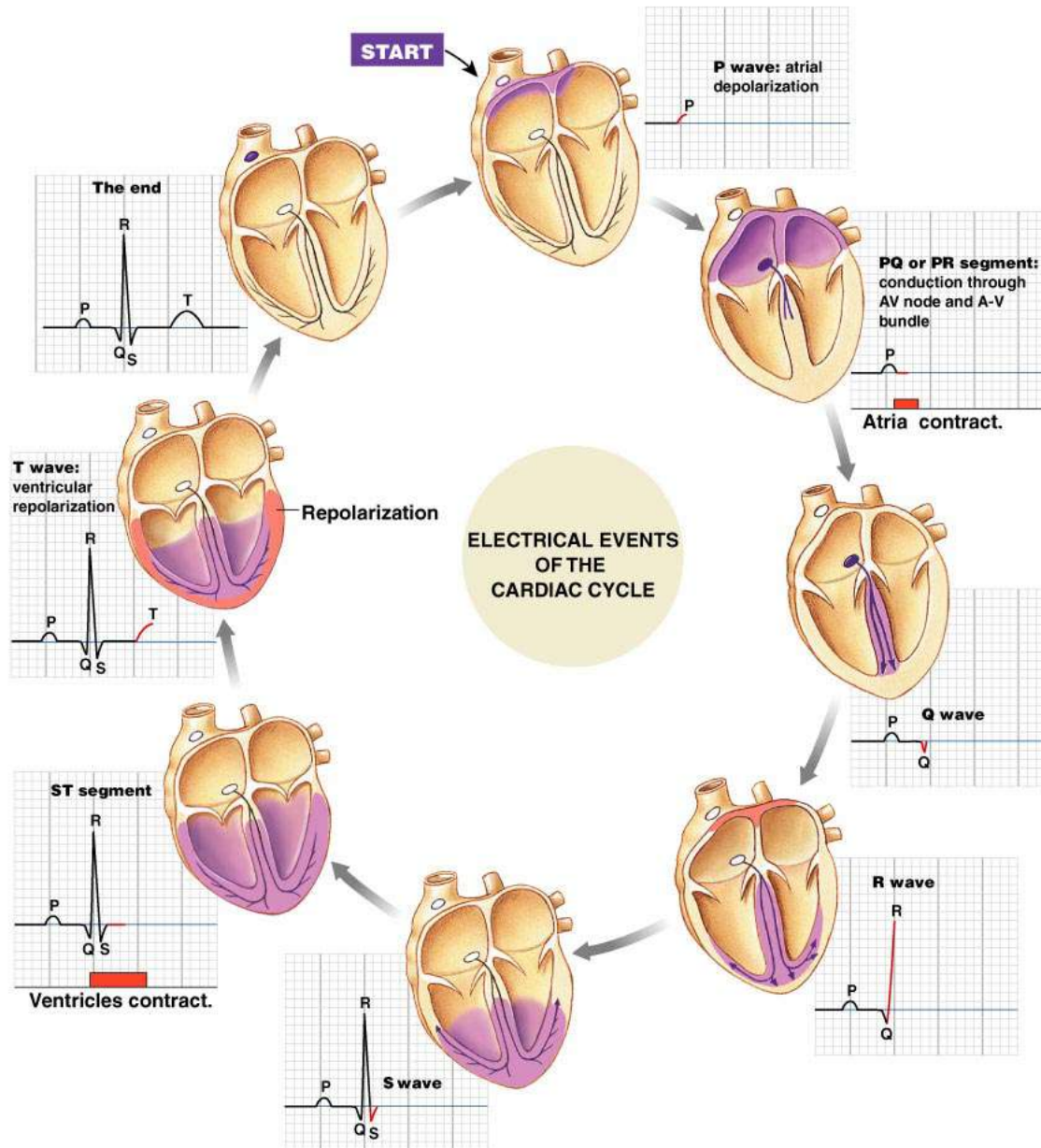
3 Depolarization spreads more slowly across atria. Conduction slows through AV node.

4 Depolarization moves rapidly through ventricular conducting system to the apex of the heart.

5 Depolarization wave spreads upward from the apex.





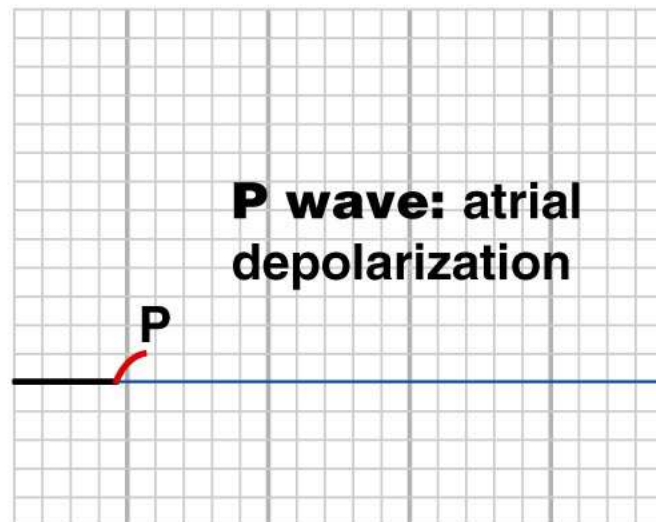
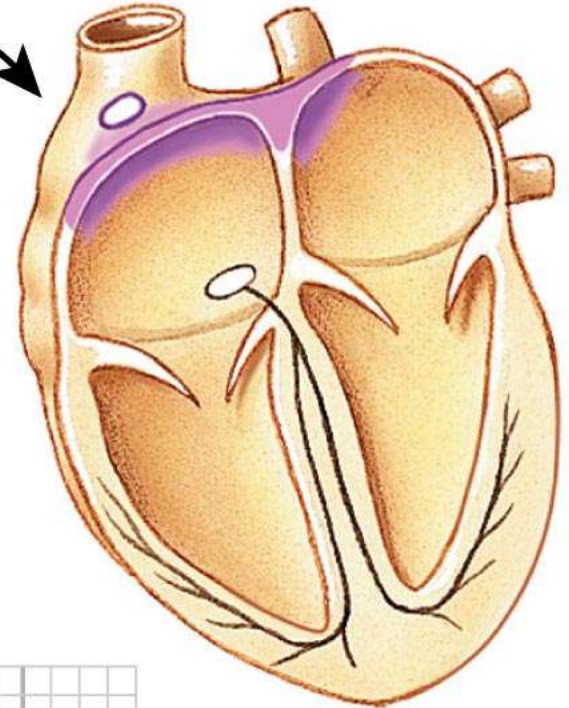


Copyright © 2007 Pearson Education, Inc., publishing as Benjamin Cummings.

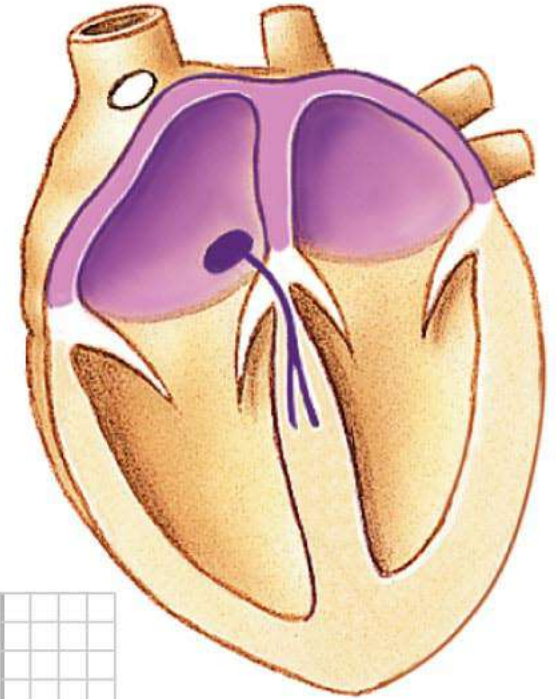
Figure 14-21 - Overview (1 of 9)

ELECTRICAL EVENTS OF THE CARDIAC CYCLE

START

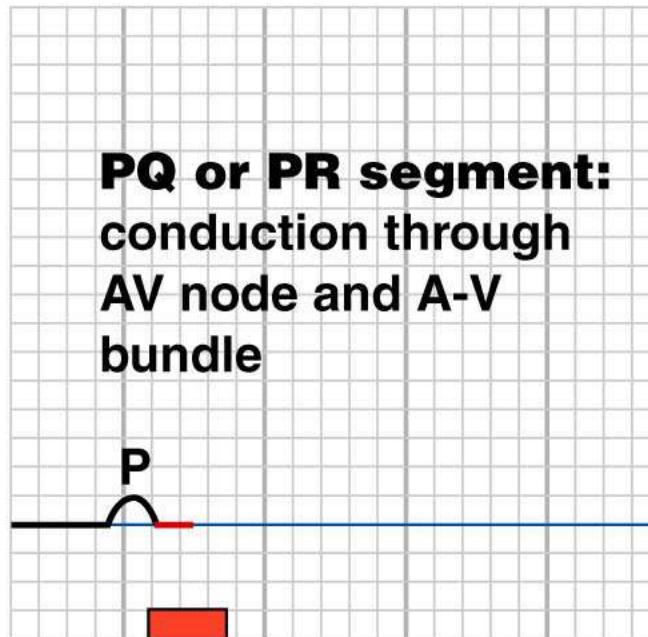


ELECTRICAL EVENTS OF THE CARDIAC CYCLE

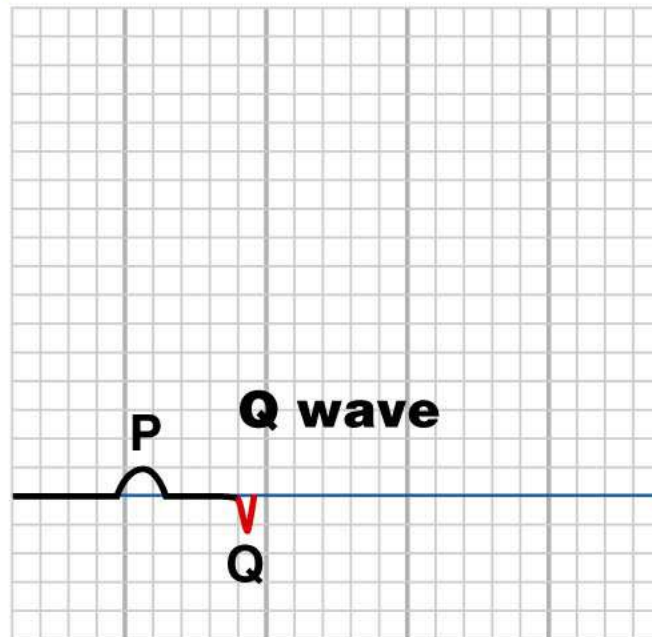
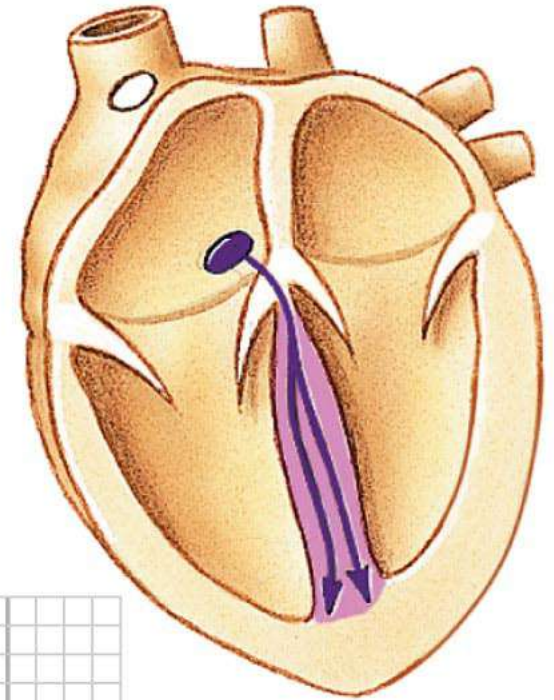


PQ or PR segment:
conduction through
AV node and A-V
bundle

**Atria
contract.**



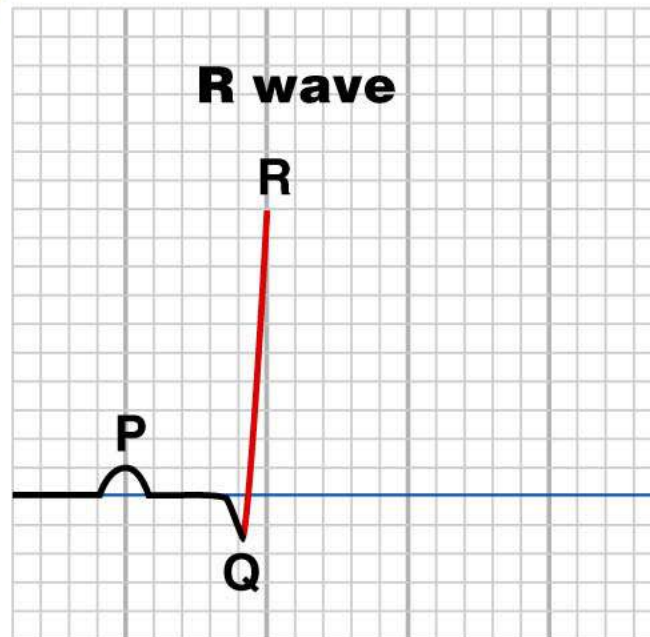
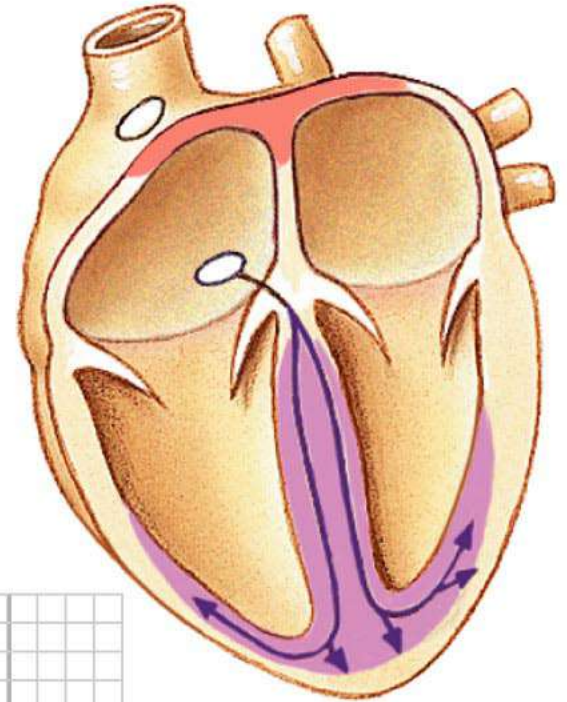
ELECTRICAL EVENTS OF THE CARDIAC CYCLE



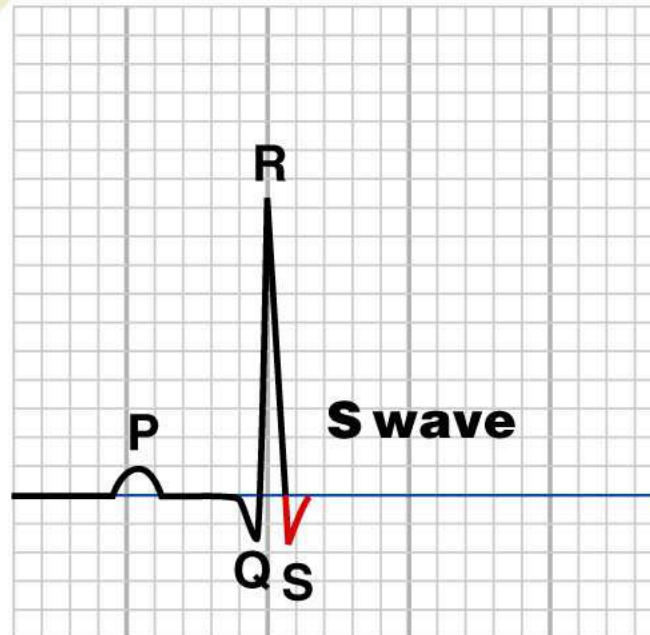
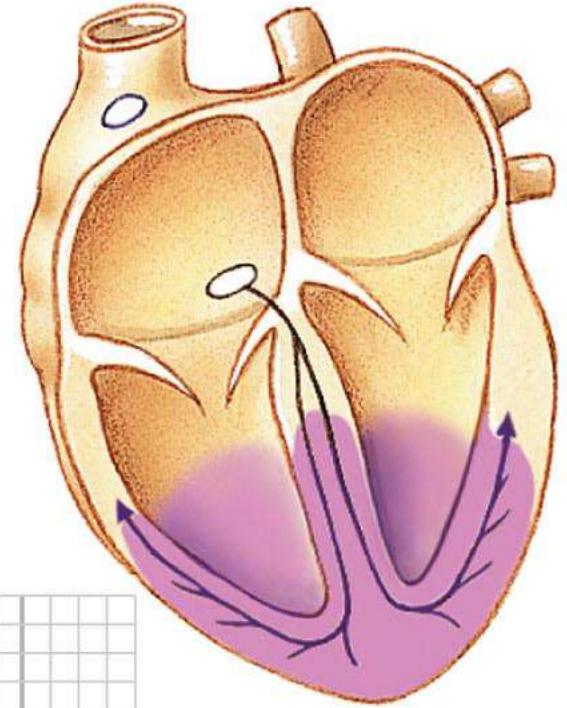
Copyright © 2007 Pearson Education, Inc., publishing as Benjamin Cummings.

Figure 14-21 (4 of 9)

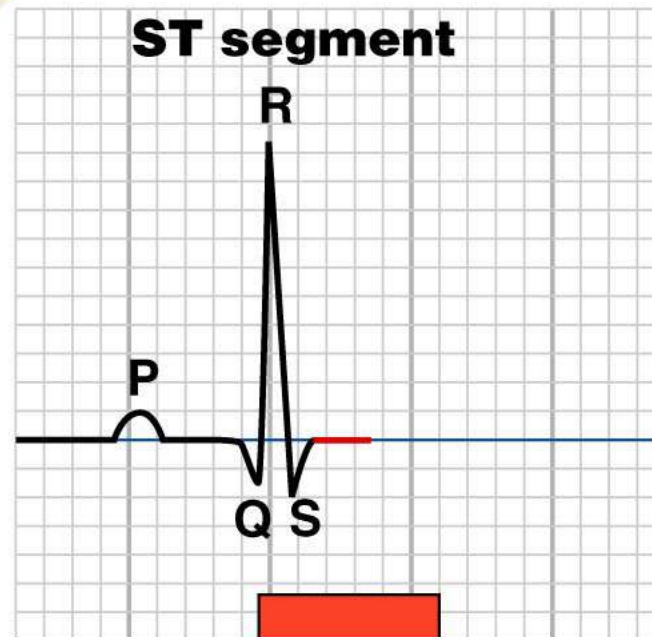
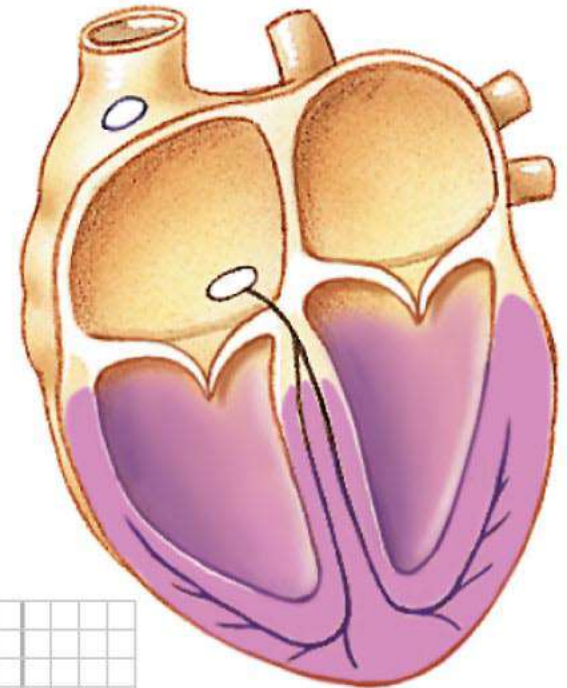
ELECTRICAL EVENTS OF THE CARDIAC CYCLE



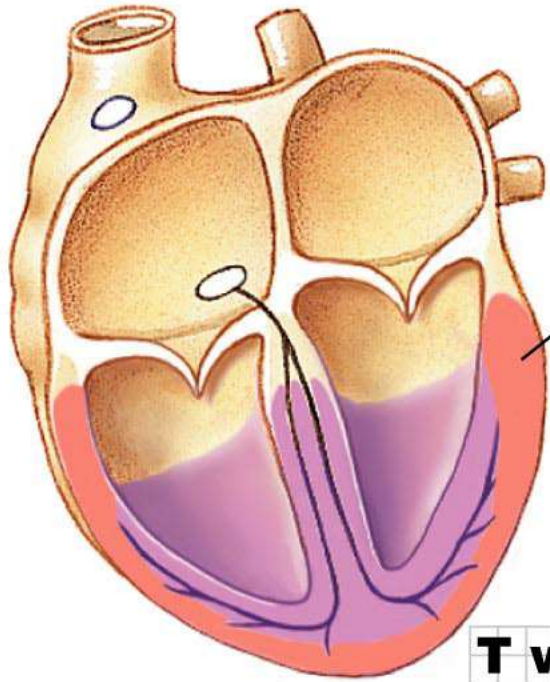
ELECTRICAL EVENTS OF THE CARDIAC CYCLE



ELECTRICAL EVENTS OF THE CARDIAC CYCLE



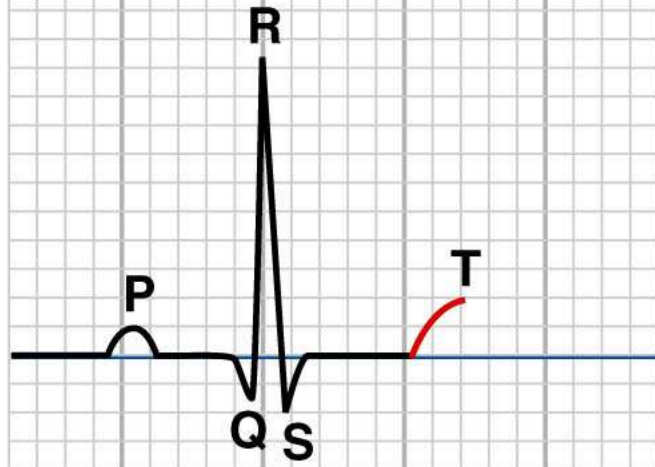
**Ventricles
contract.**



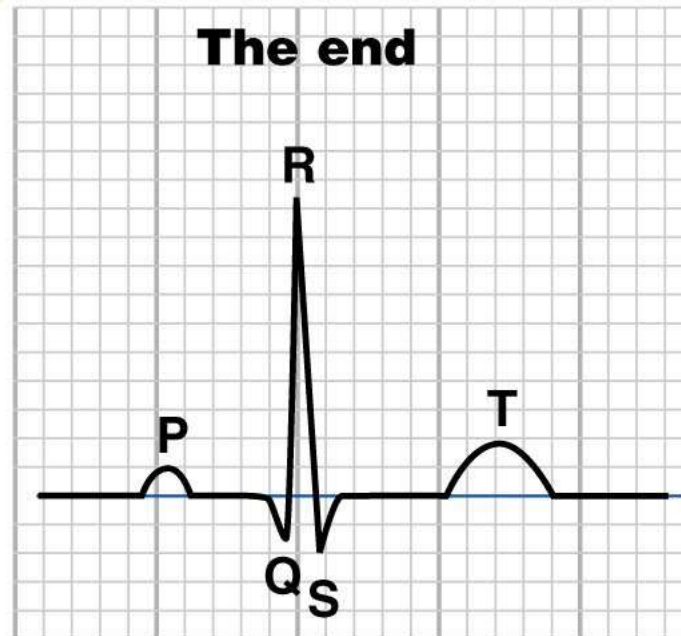
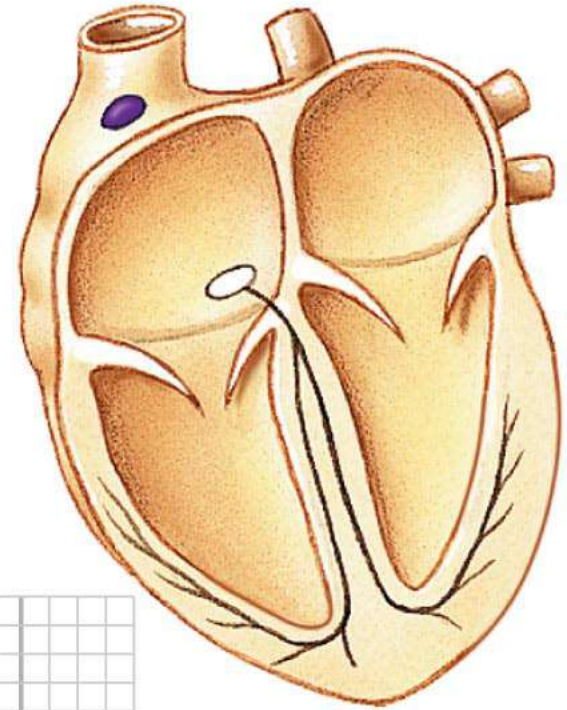
Repolarization

ELECTRICAL EVENTS OF THE CARDIAC CYCLE

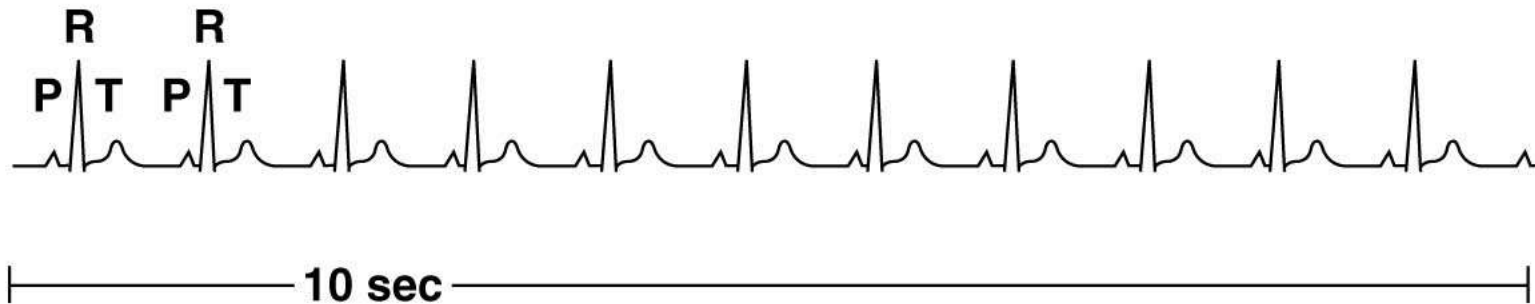
T wave: ventricular repolarization



ELECTRICAL EVENTS OF THE CARDIAC CYCLE



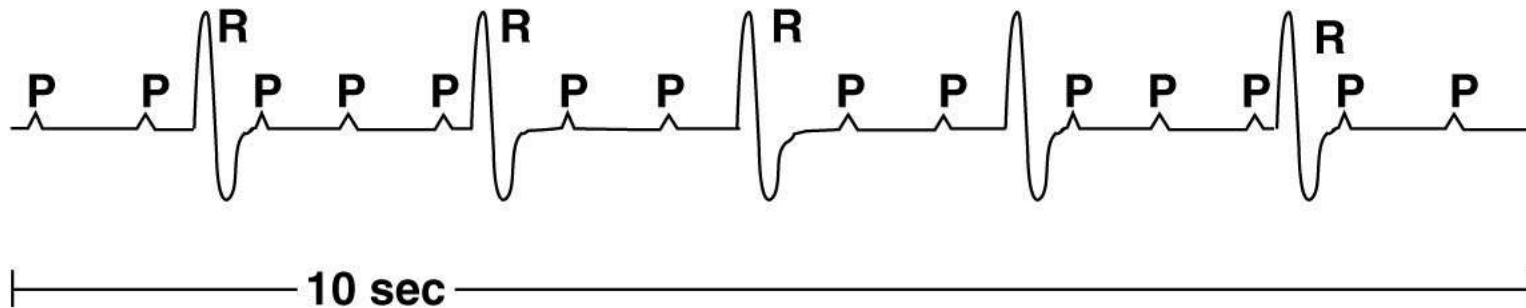
(a) Normal ECG



Questions to ask when analyzing ECG tracings:

- 1. What is the rate? Is it within the normal range of 60-100 beats per minute?**
- 2. Is the rhythm regular?**
- 3. Are all normal waves present in recognizable form?**
- 4. Is there one QRS complex for each P wave?
If yes, is the P-R segment constant in length?**
- 5. If there is not one QRS complex for each P wave, count the heart rate using the P waves, then count it according to the R waves. Are the rates the same? Which wave would agree with the pulse felt at the wrist?**

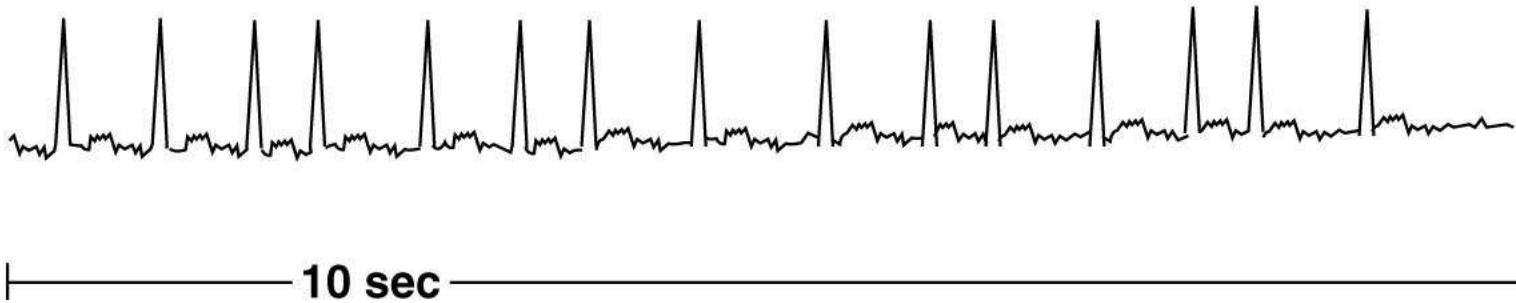(b) Third-degree block



Questions to ask when analyzing ECG tracings:

- 1. What is the rate? Is it within the normal range of 60-100 beats per minute?**
- 2. Is the rhythm regular?**
- 3. Are all normal waves present in recognizable form?**
- 4. Is there one QRS complex for each P wave?
If yes, is the P-R segment constant in length?**
- 5. If there is not one QRS complex for each P wave, count the heart rate using the P waves, then count it according to the R waves. Are the rates the same? Which wave would agree with the pulse felt at the wrist?**

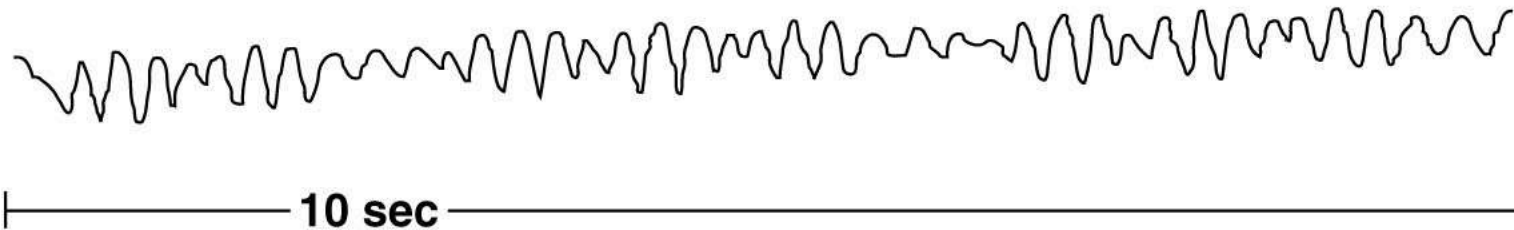
(c) Atrial fibrillation



Questions to ask when analyzing ECG tracings:

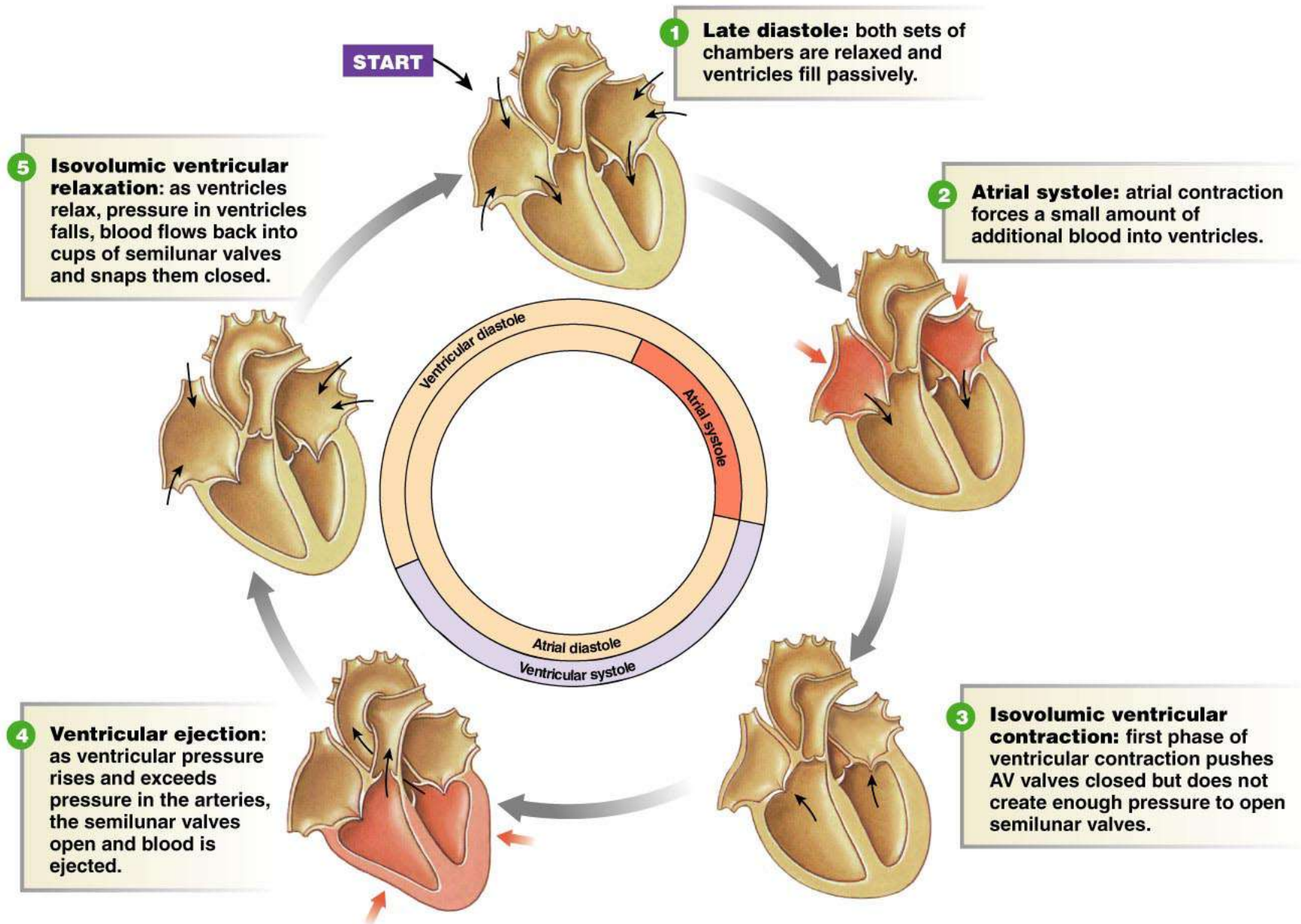
- 1. What is the rate? Is it within the normal range of 60-100 beats per minute?**
- 2. Is the rhythm regular?**
- 3. Are all normal waves present in recognizable form?**
- 4. Is there one QRS complex for each P wave?
If yes, is the P-R segment constant in length?**
- 5. If there is not one QRS complex for each P wave, count the heart rate using the P waves, then count it according to the R waves. Are the rates the same? Which wave would agree with the pulse felt at the wrist?**

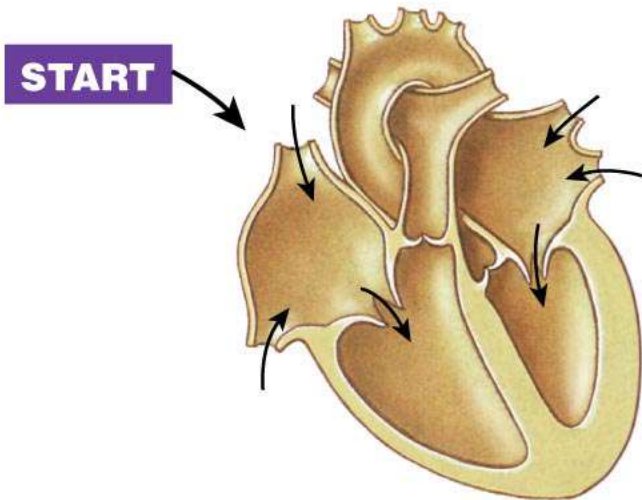
(d) Ventricular fibrillation



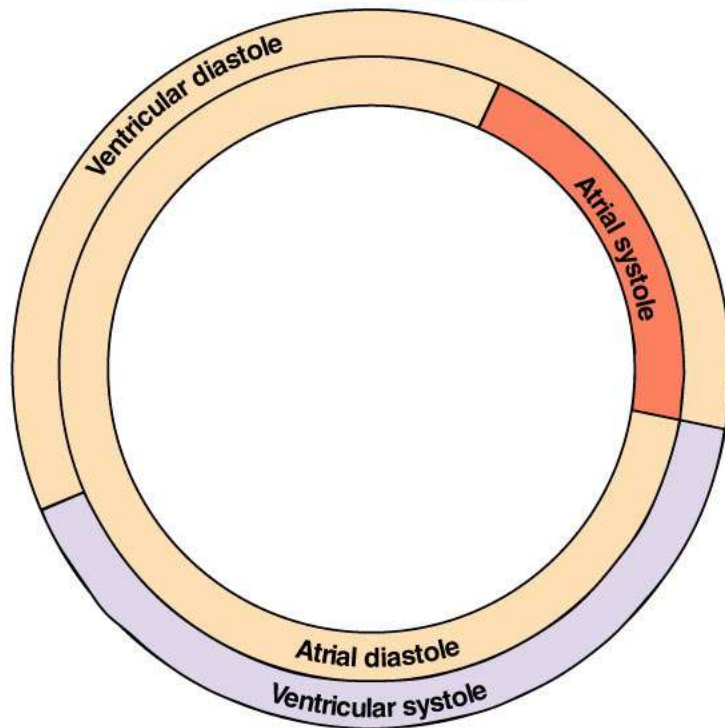
Questions to ask when analyzing ECG tracings:

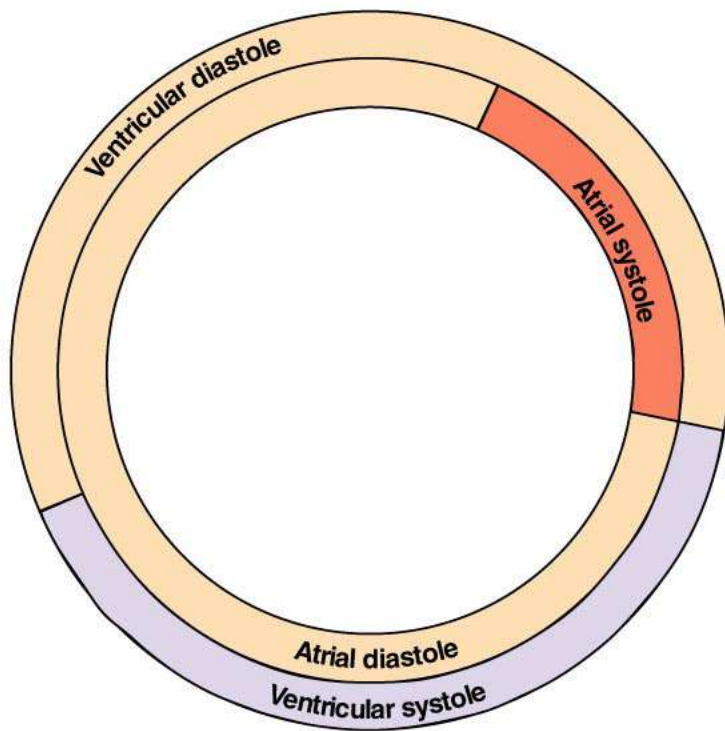
- 1. What is the rate? Is it within the normal range of 60-100 beats per minute?**
- 2. Is the rhythm regular?**
- 3. Are all normal waves present in recognizable form?**
- 4. Is there one QRS complex for each P wave?
If yes, is the P-R segment constant in length?**
- 5. If there is not one QRS complex for each P wave, count the heart rate using the P waves, then count it according to the R waves. Are the rates the same?
Which wave would agree with the pulse felt at the wrist?**



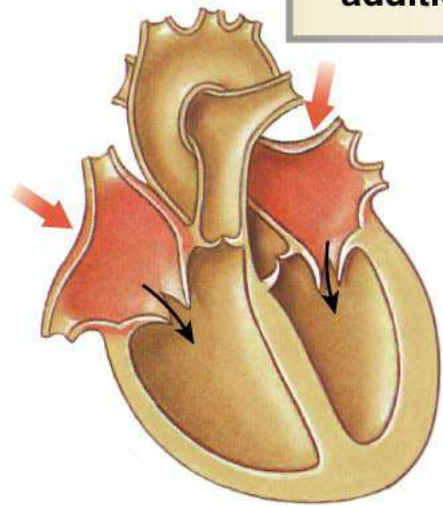


1 **Late diastole:** both sets of chambers are relaxed and ventricles fill passively.



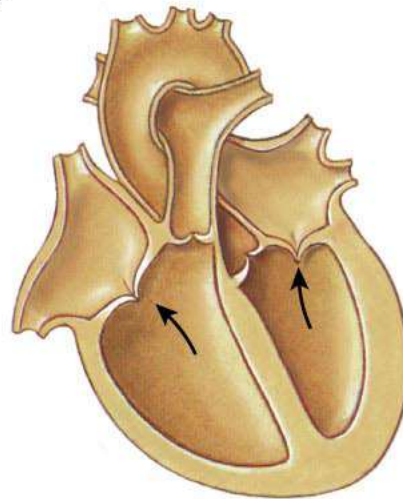
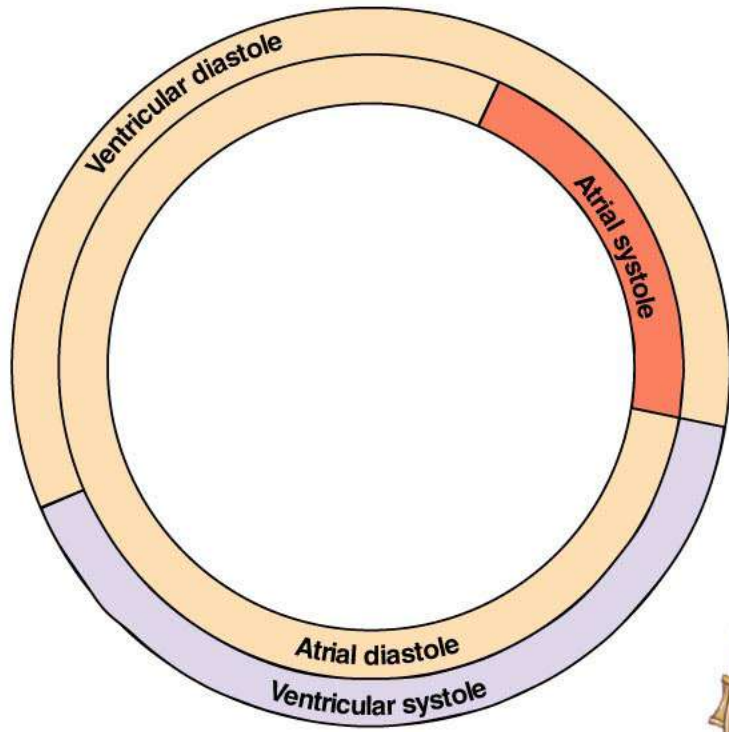


2 Atrial systole: atrial contraction forces a small amount of additional blood into ventricles.



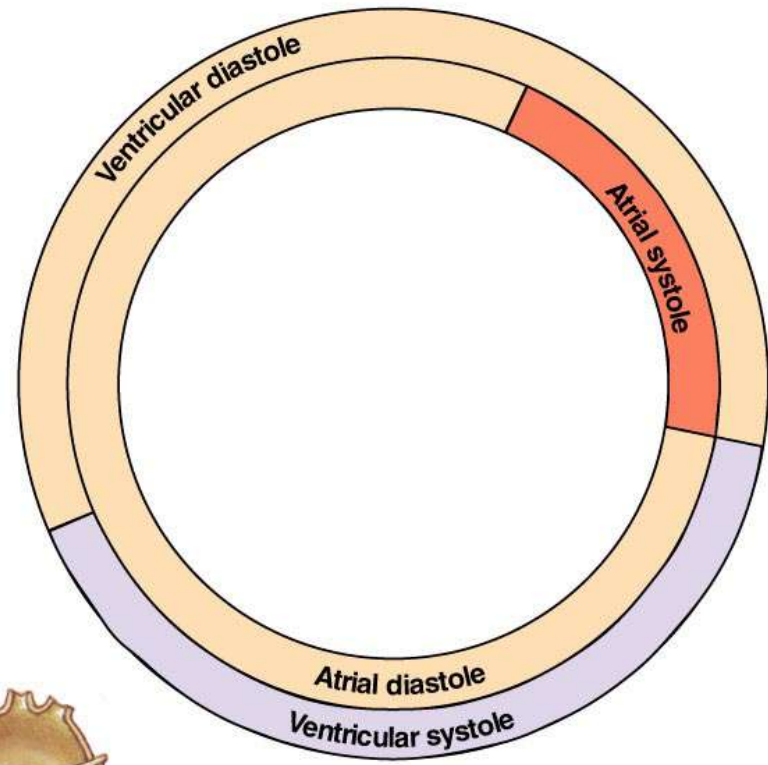
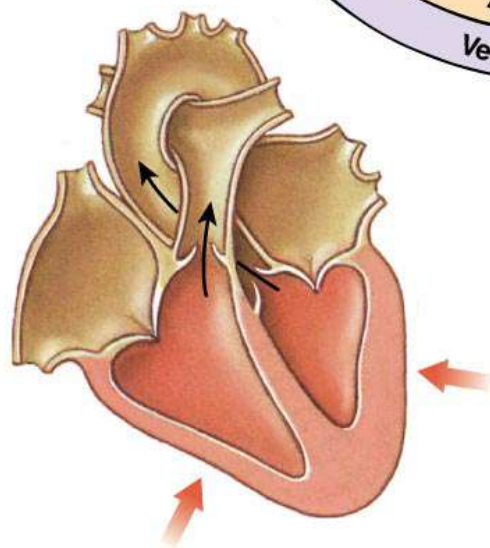
Copyright © 2007 Pearson Education, Inc., publishing as Benjamin Cummings.

Figure 14-24, step 2



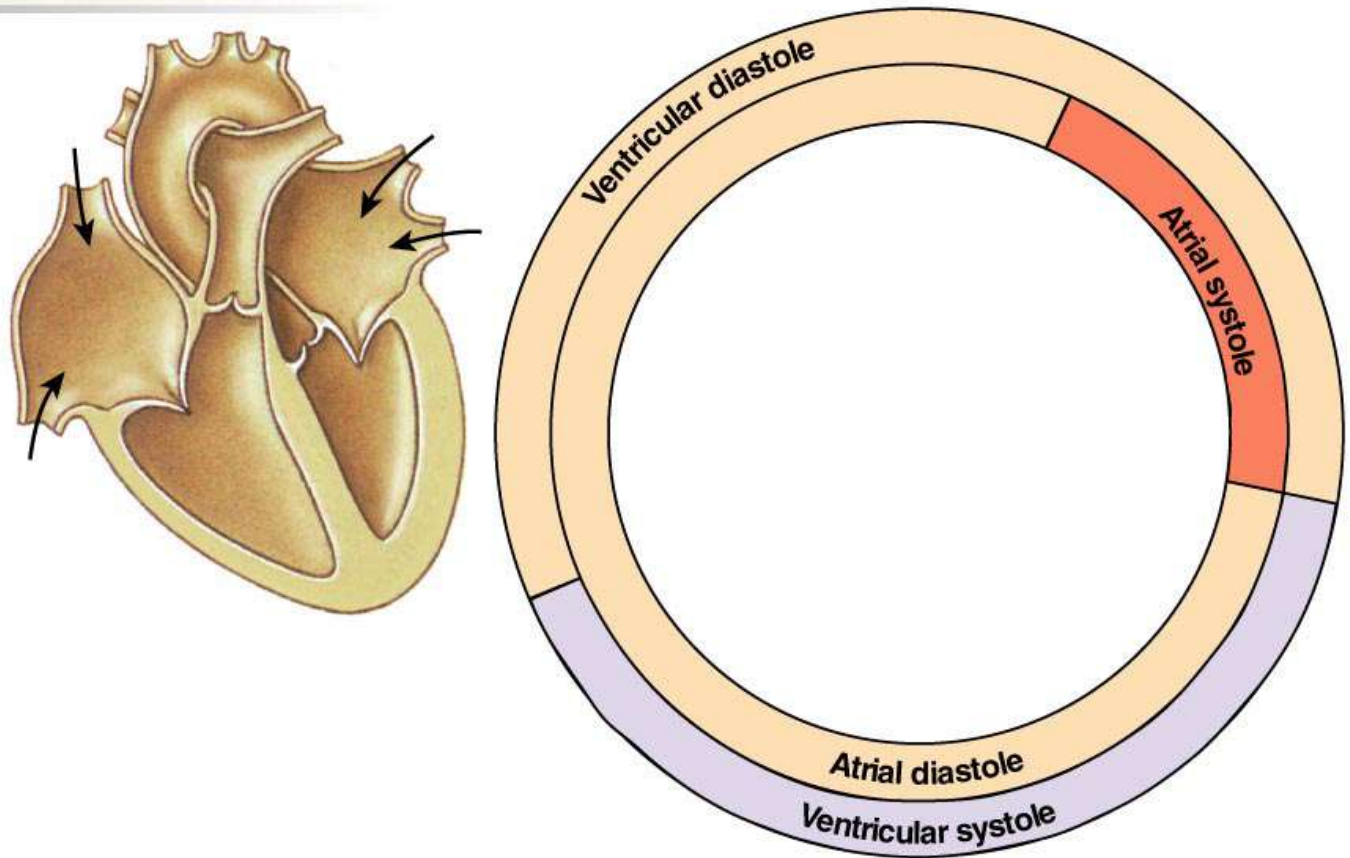
3 Isovolumic ventricular contraction: first phase of ventricular contraction pushes AV valves closed but does not create enough pressure to open semilunar valves.

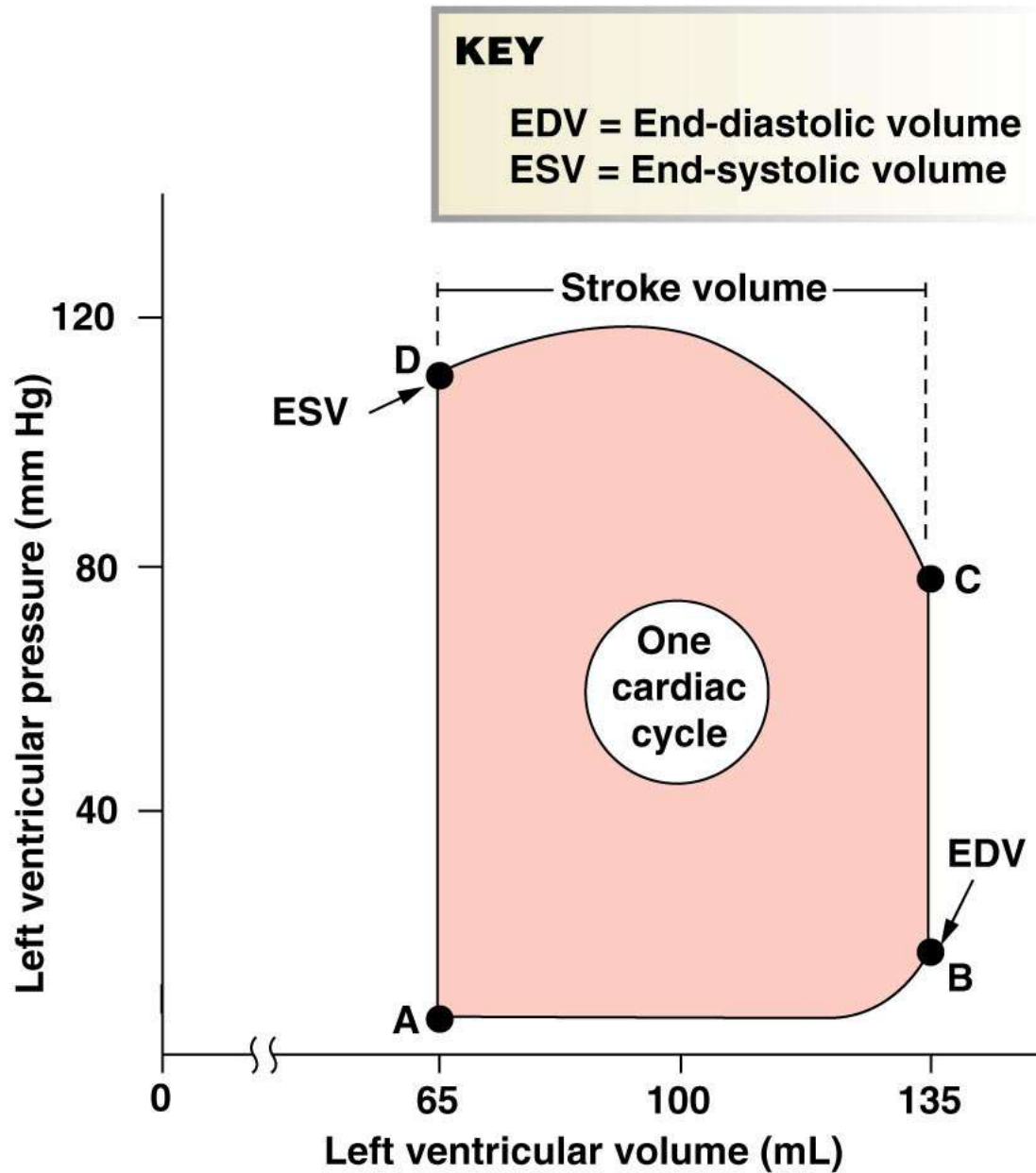
4 Ventricular ejection: as ventricular pressure rises and exceeds pressure in the arteries, the semilunar valves open and blood is ejected.



5

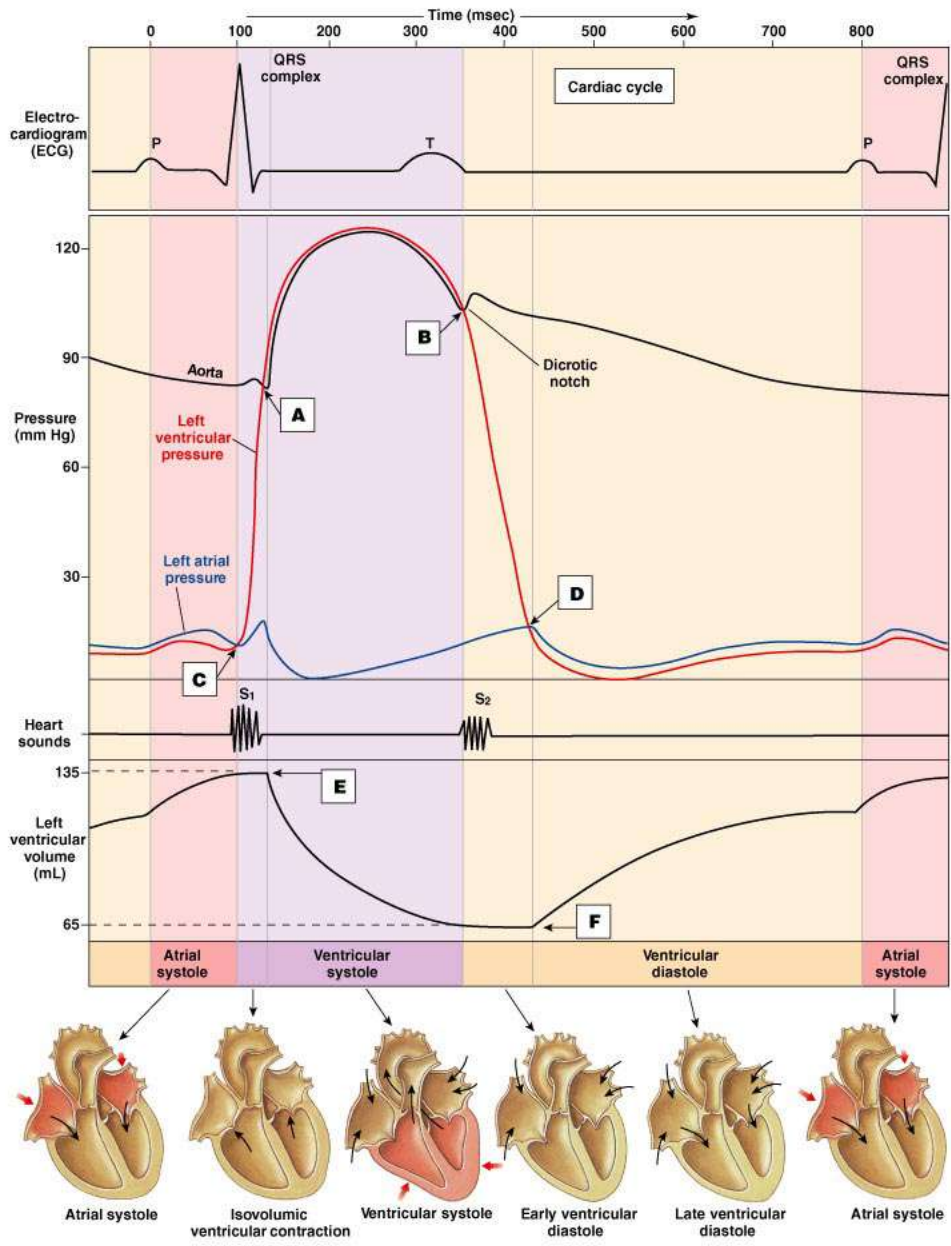
Isovolumic ventricular relaxation: as ventricles relax, pressure in ventricles falls, blood flows back into cups of semilunar valves and snaps them closed.





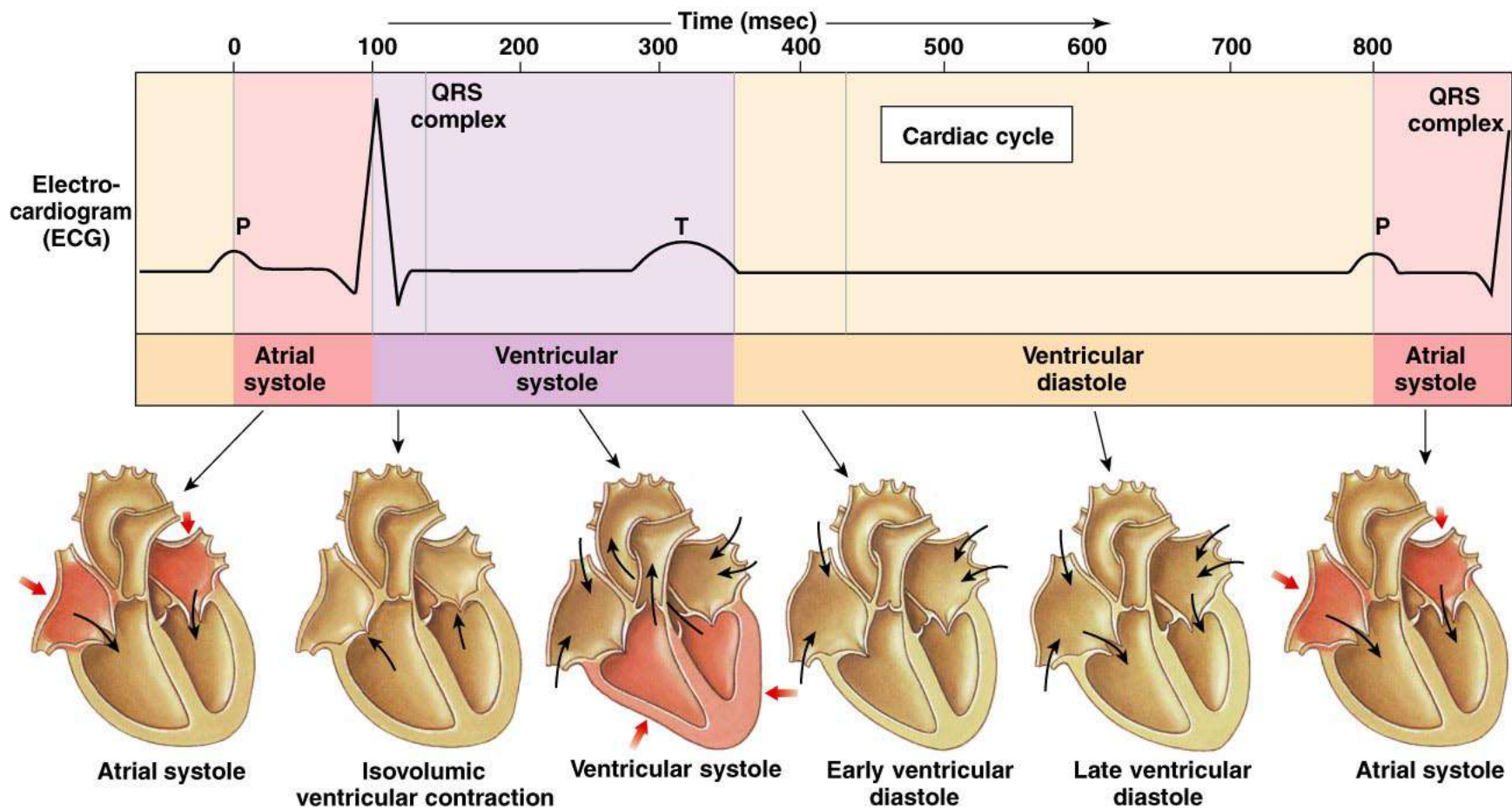
Copyright © 2007 Pearson Education, Inc., publishing as Benjamin Cummings.

Figure 14-25



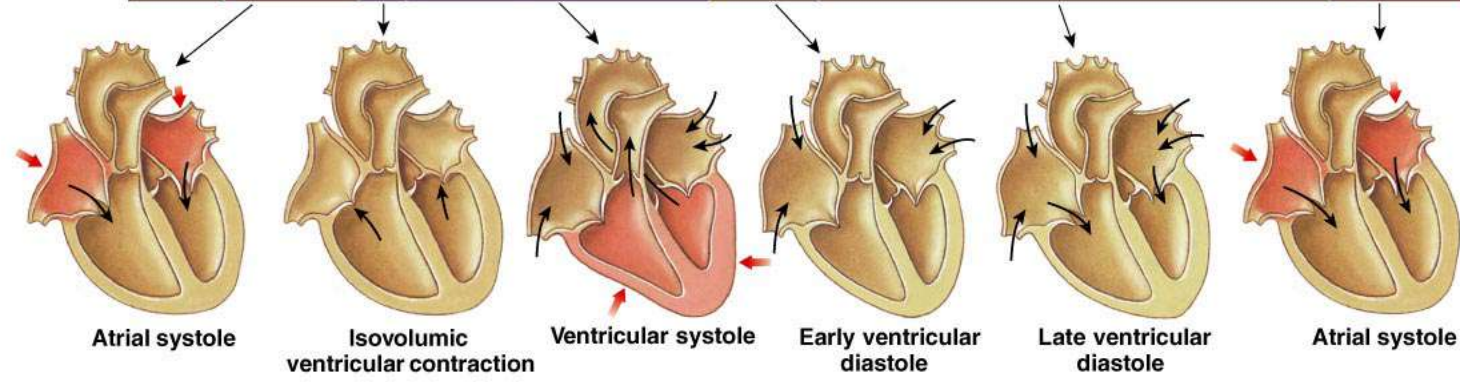
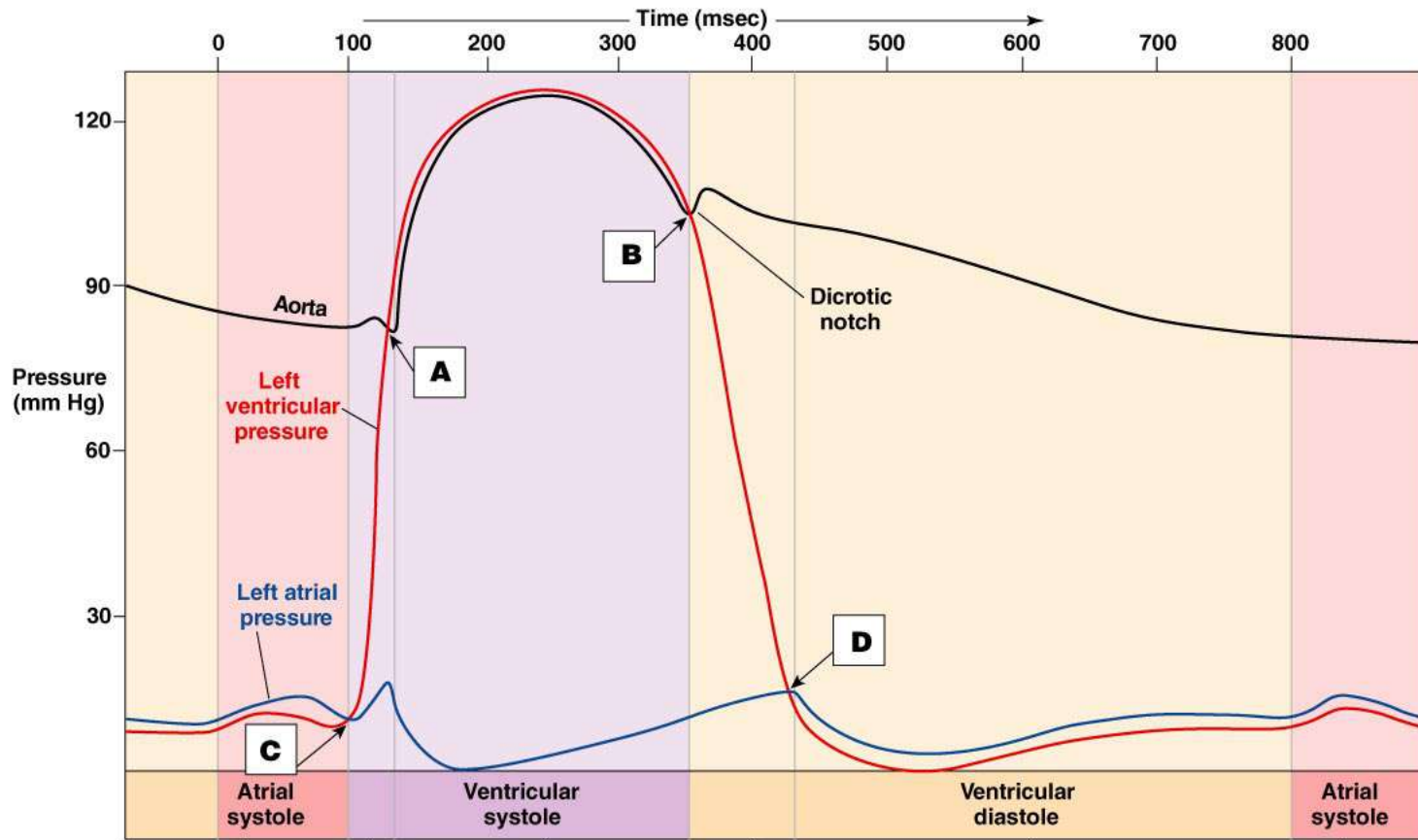
Copyright © 2007 Pearson Education, Inc., publishing as Benjamin Cummings.

Figure 14-26 – Overview (1 of 5)



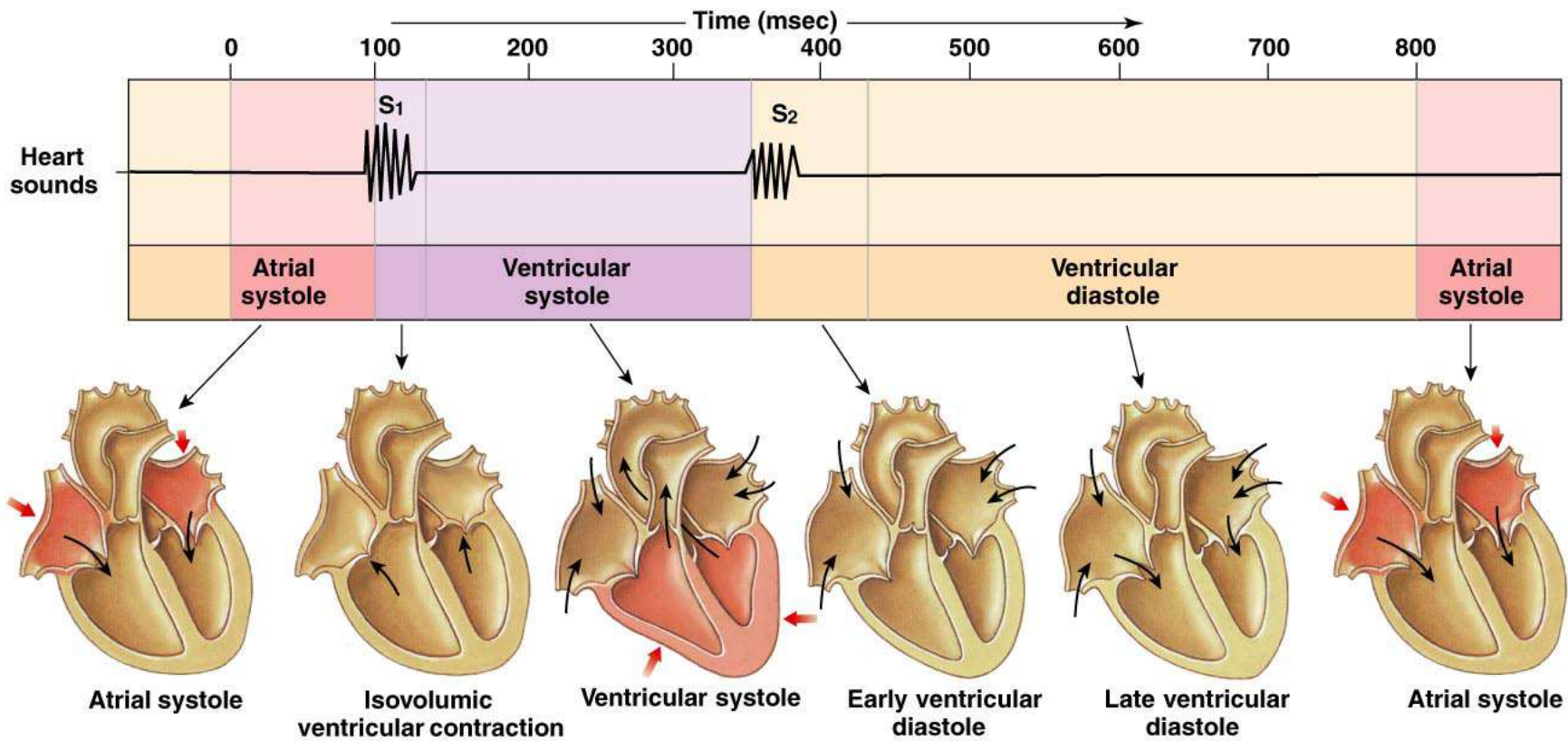
Copyright © 2007 Pearson Education, Inc., publishing as Benjamin Cummings.

Figure 14-26 (2 of 5)



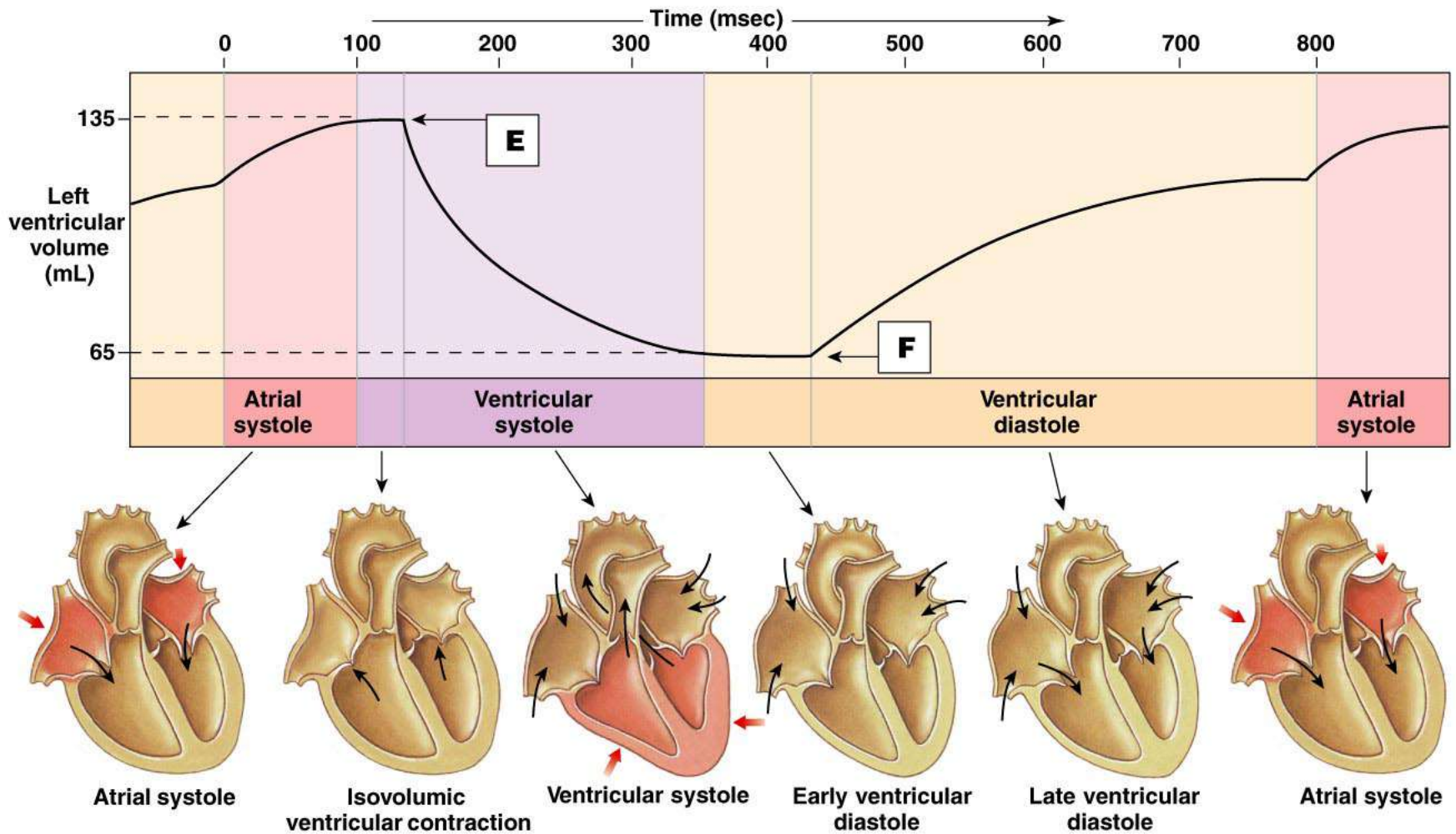
Copyright © 2007 Pearson Education, Inc., publishing as Benjamin Cummings.

Figure 14-26 (3 of 5)



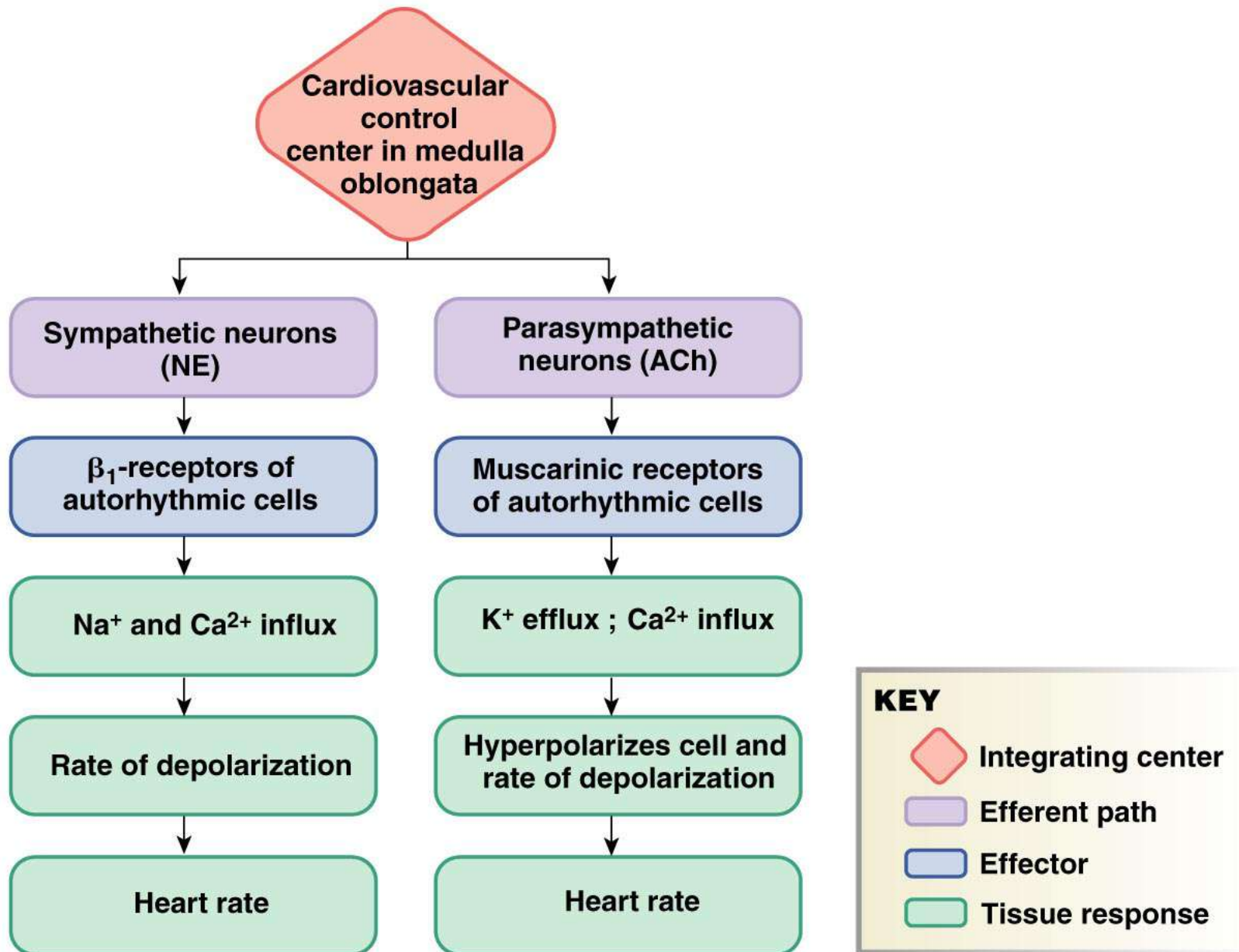
Copyright © 2007 Pearson Education, Inc., publishing as Benjamin Cummings.

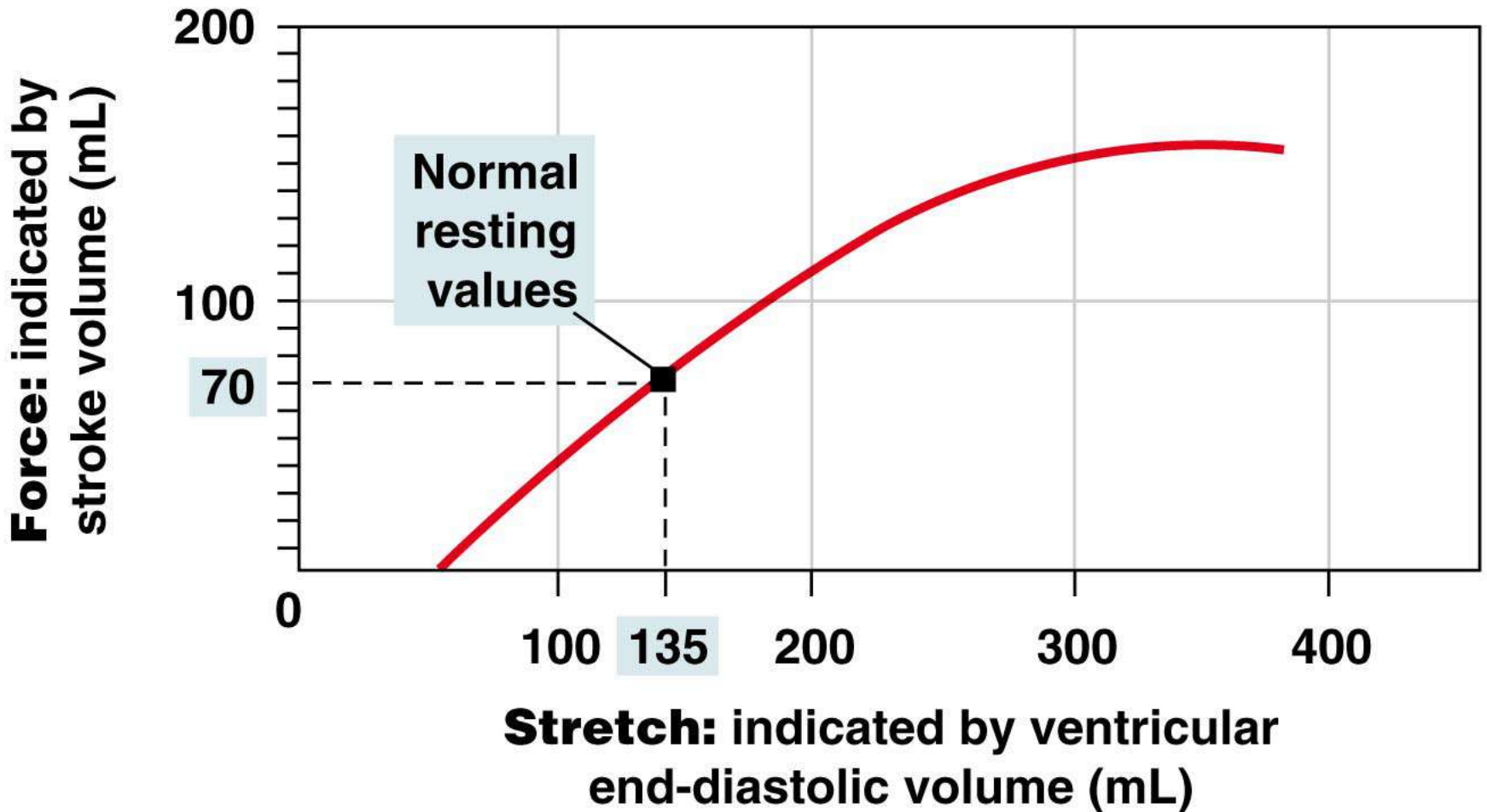
Figure 14-26 (4 of 5)



Copyright © 2007 Pearson Education, Inc., publishing as Benjamin Cummings.

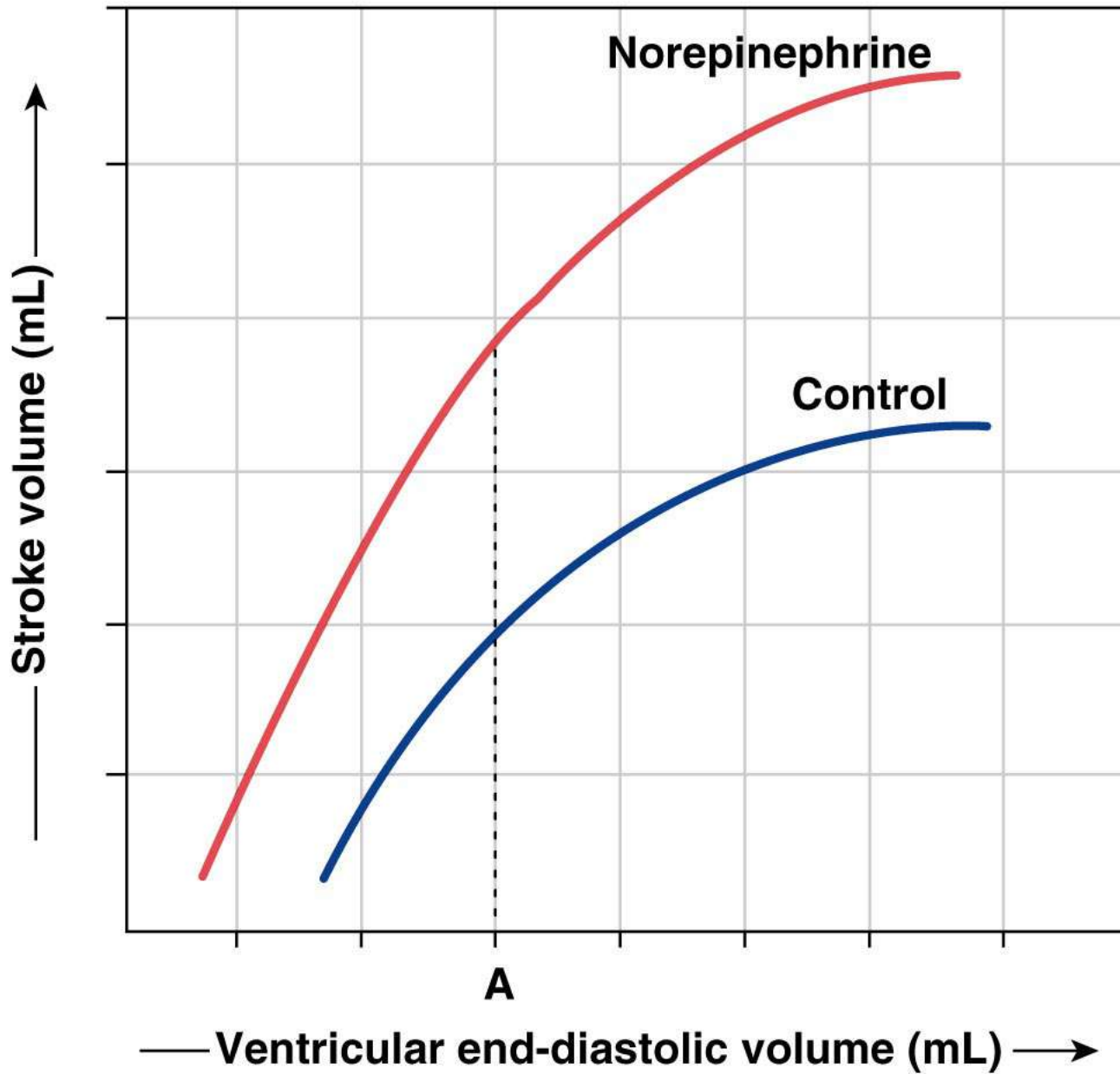
Figure 14-26 (5 of 5)





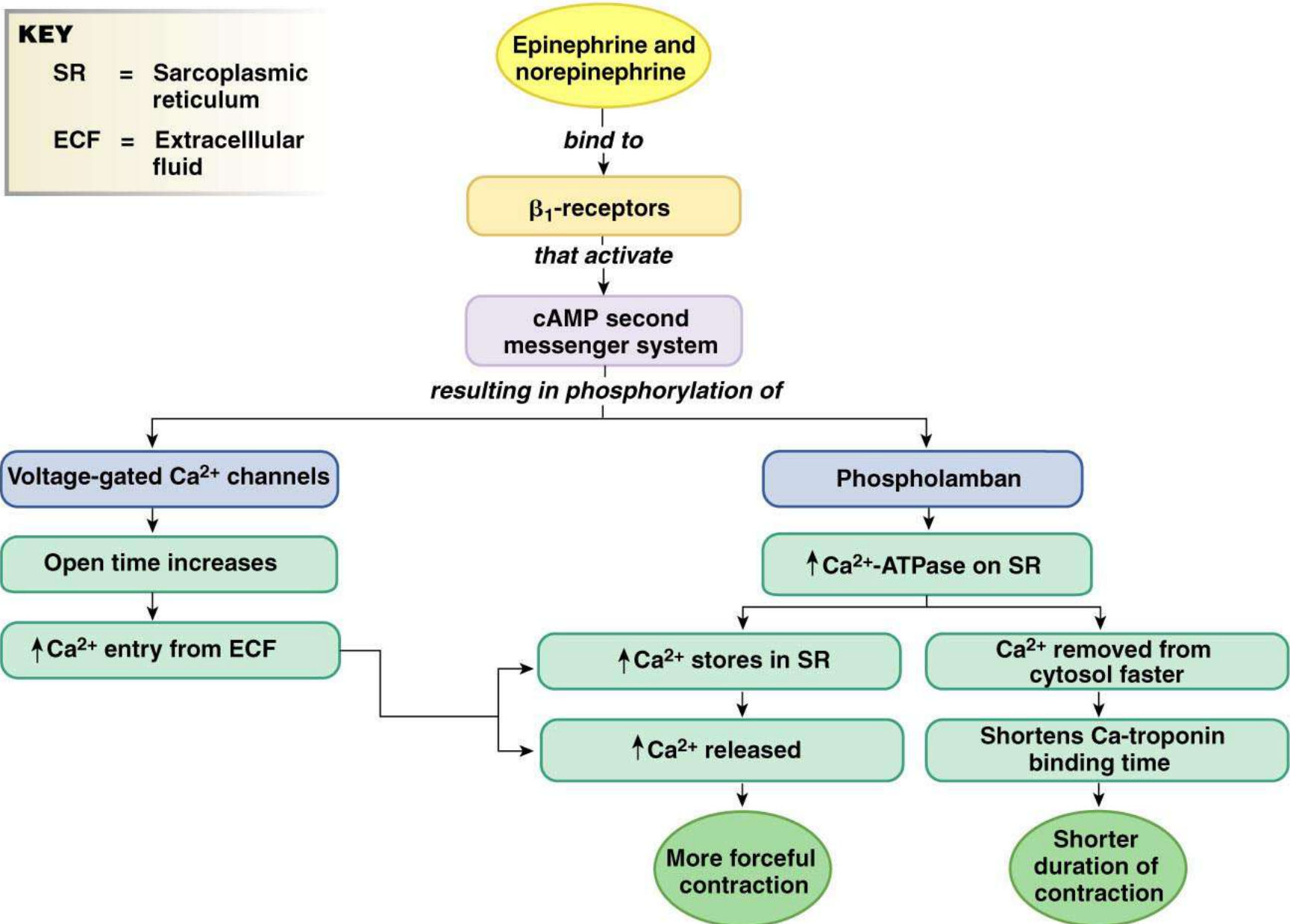
Copyright © 2007 Pearson Education, Inc., publishing as Benjamin Cummings.

Figure 14-28



Copyright © 2007 Pearson Education, Inc., publishing as Benjamin Cummings.

Figure 14-29



CARDIAC OUTPUT

is a function of

