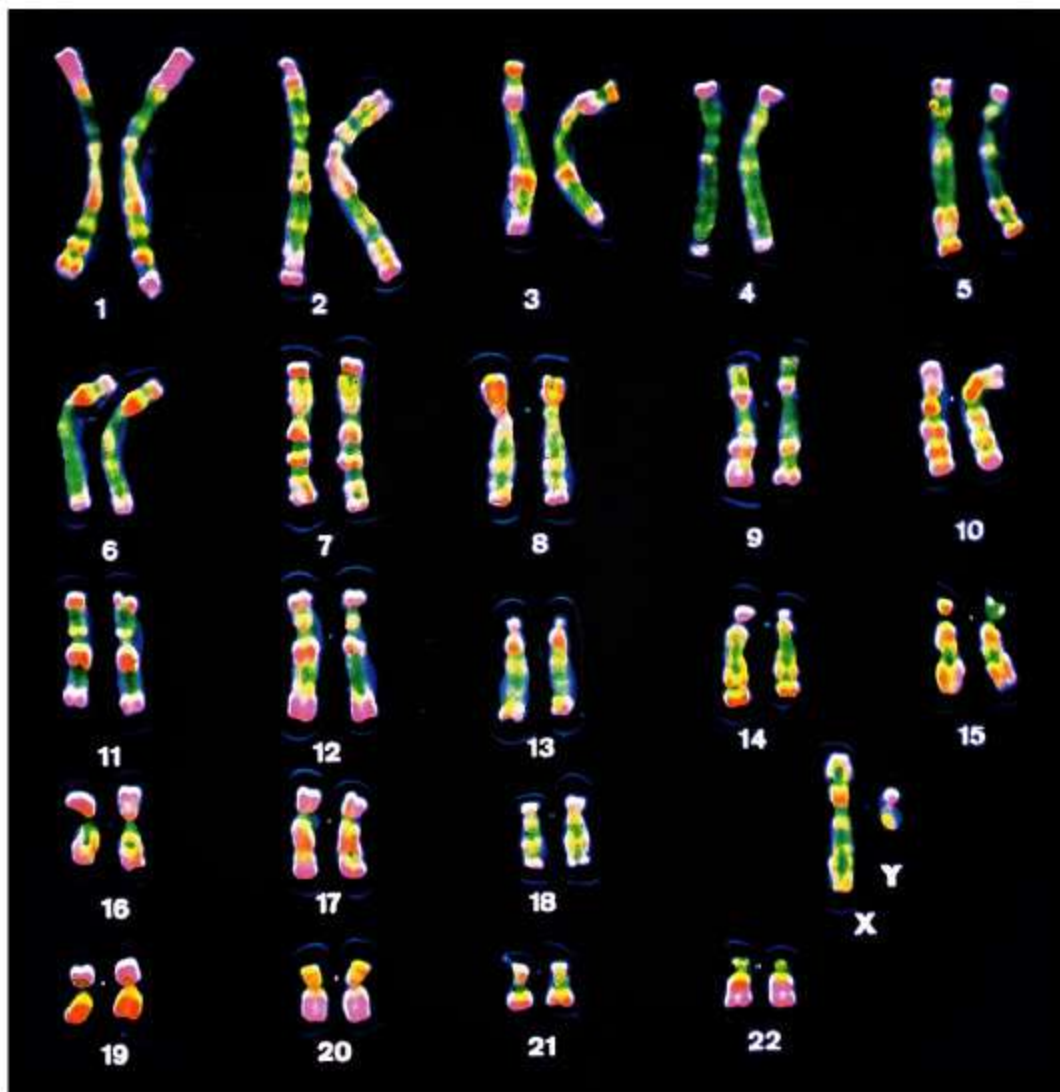
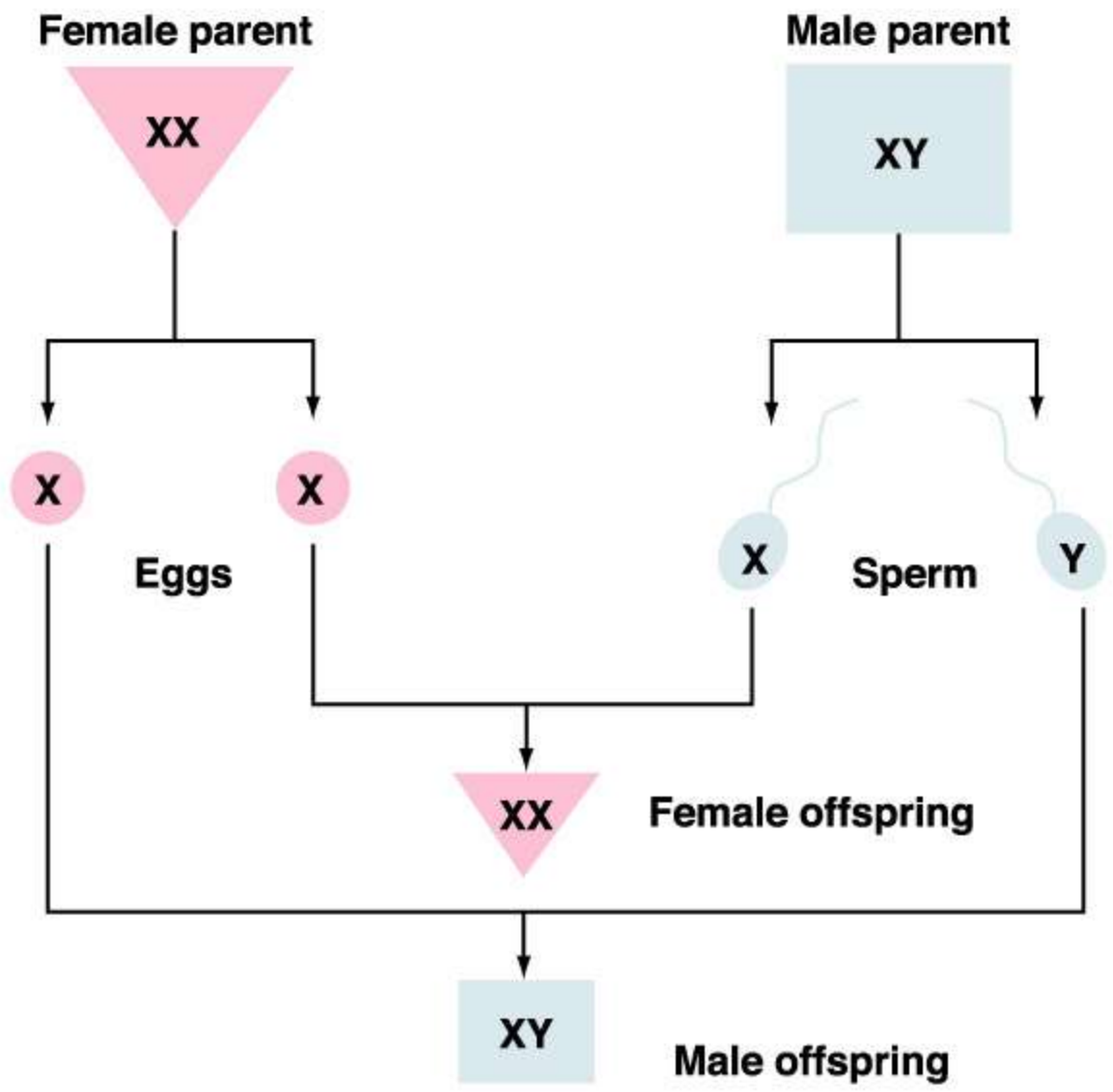
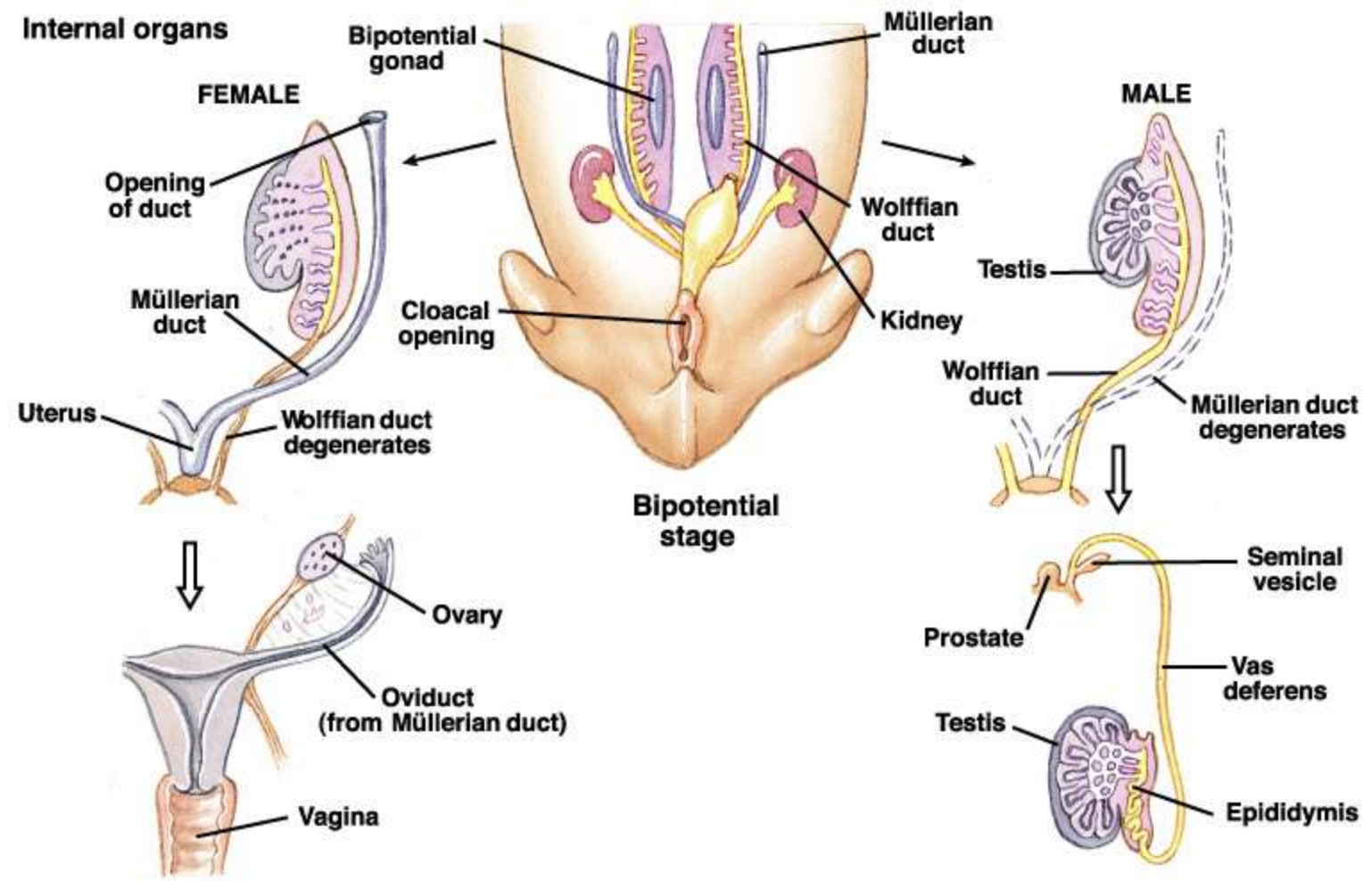


REPRODUCTION

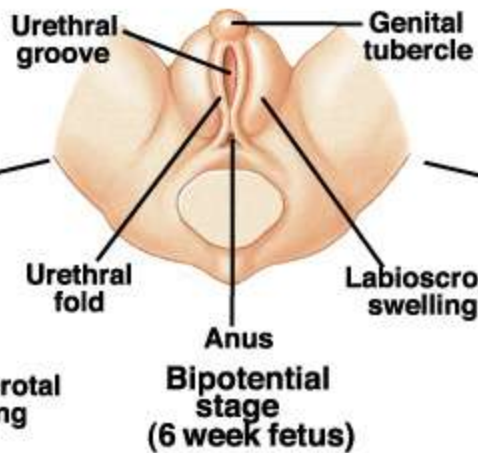
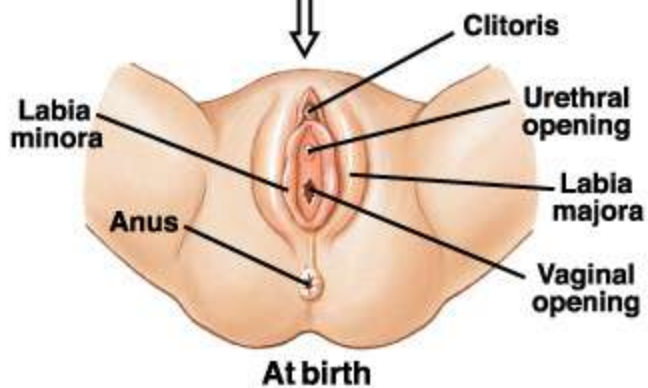
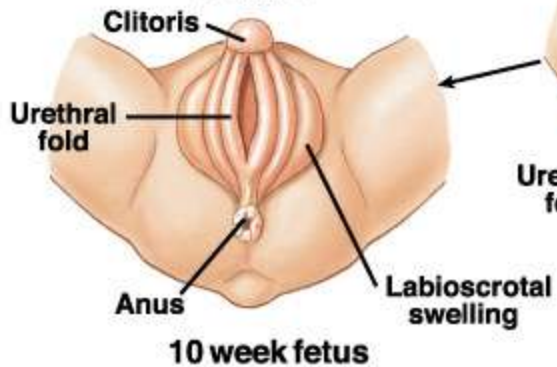




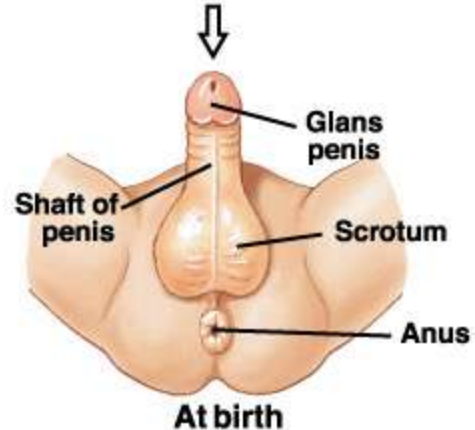
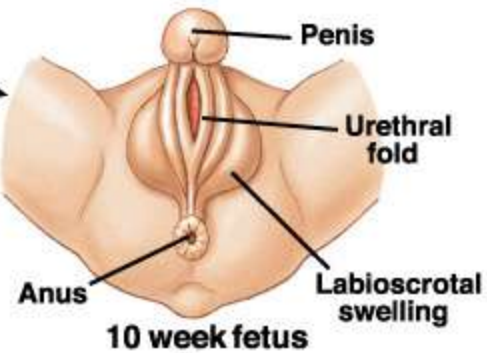
Internal organs

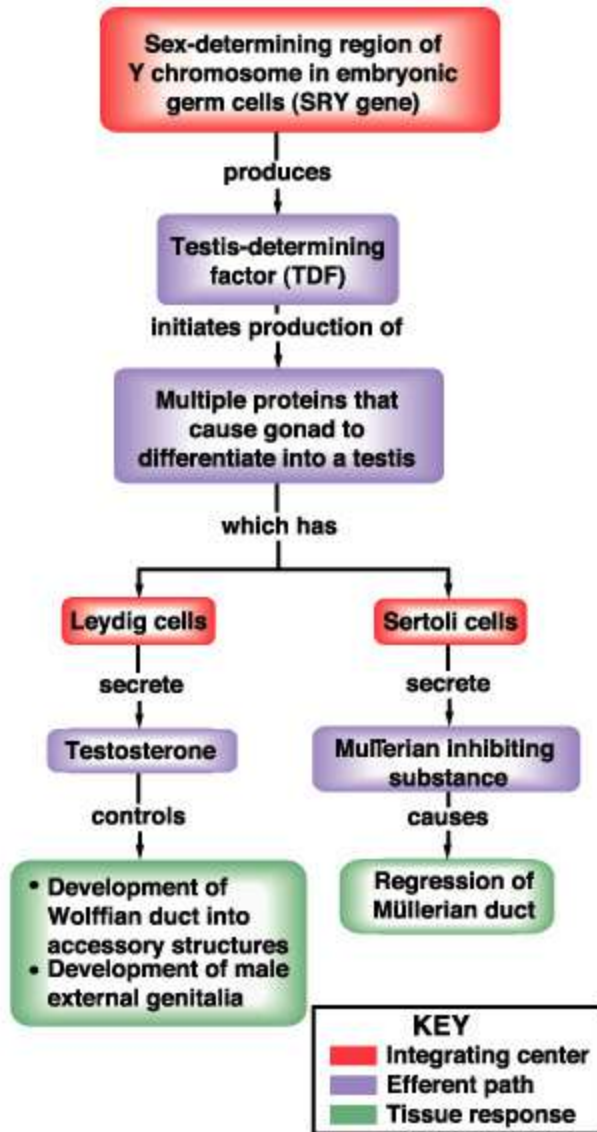


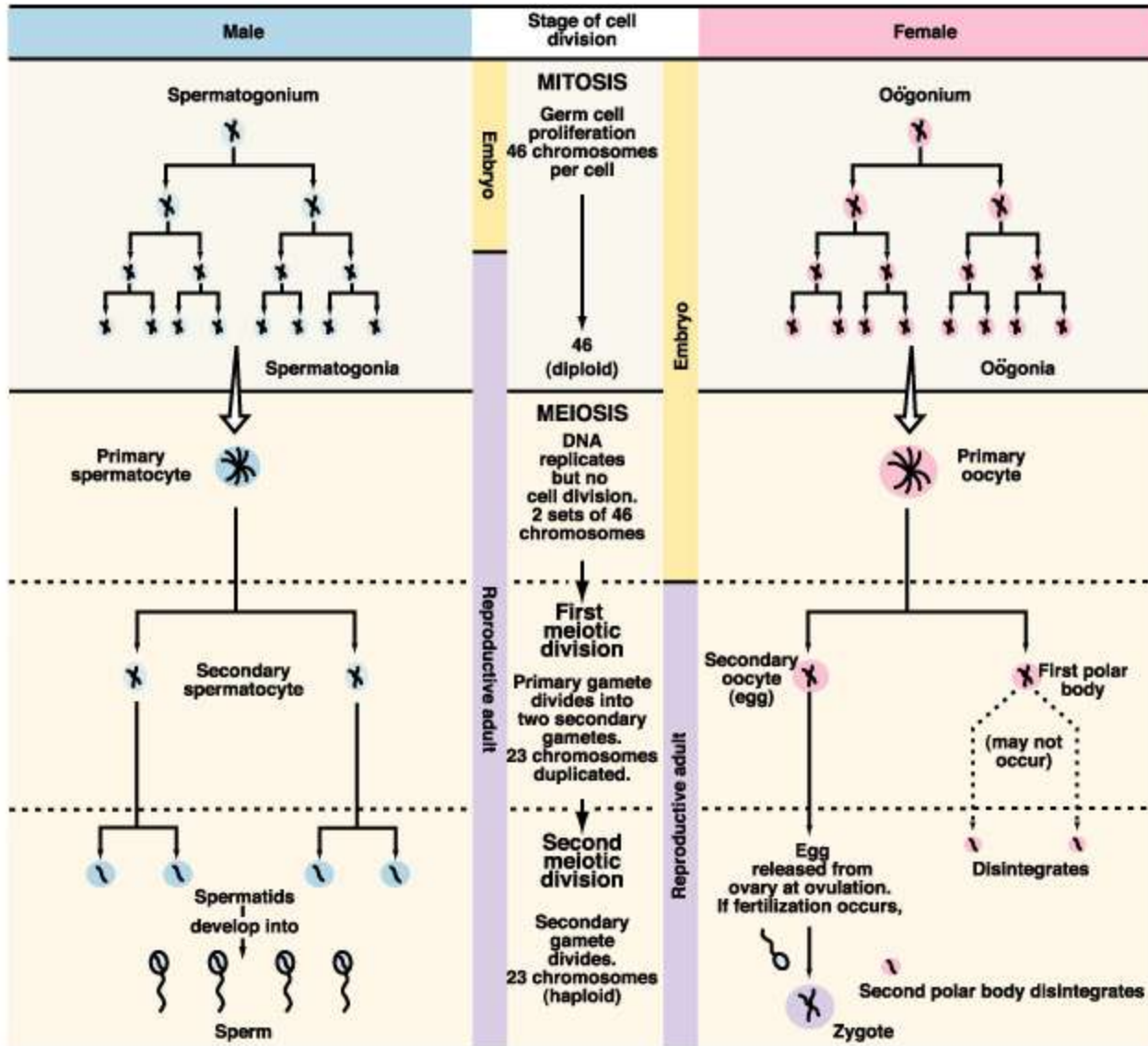
(b) External genitalia
FEMALE

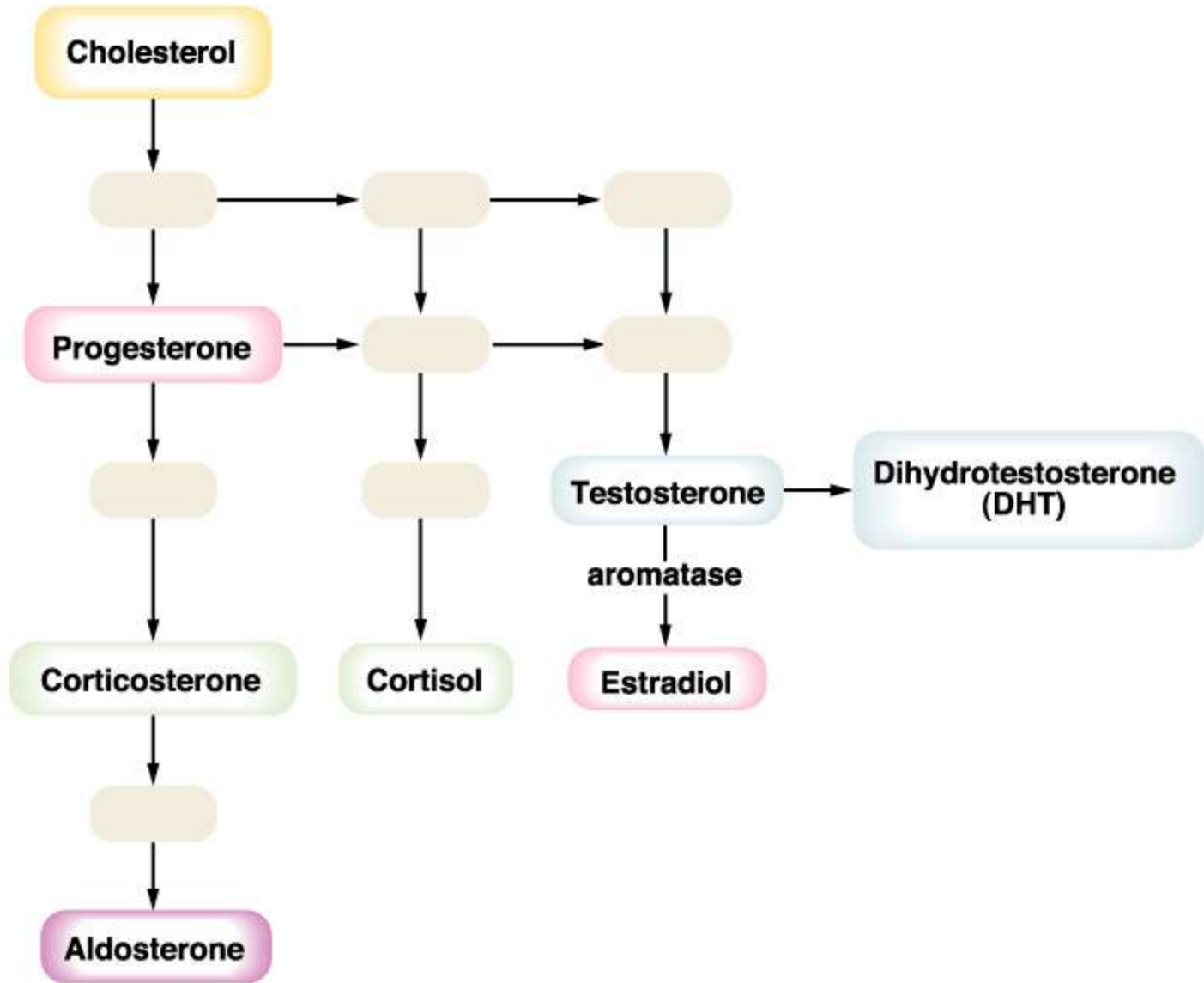


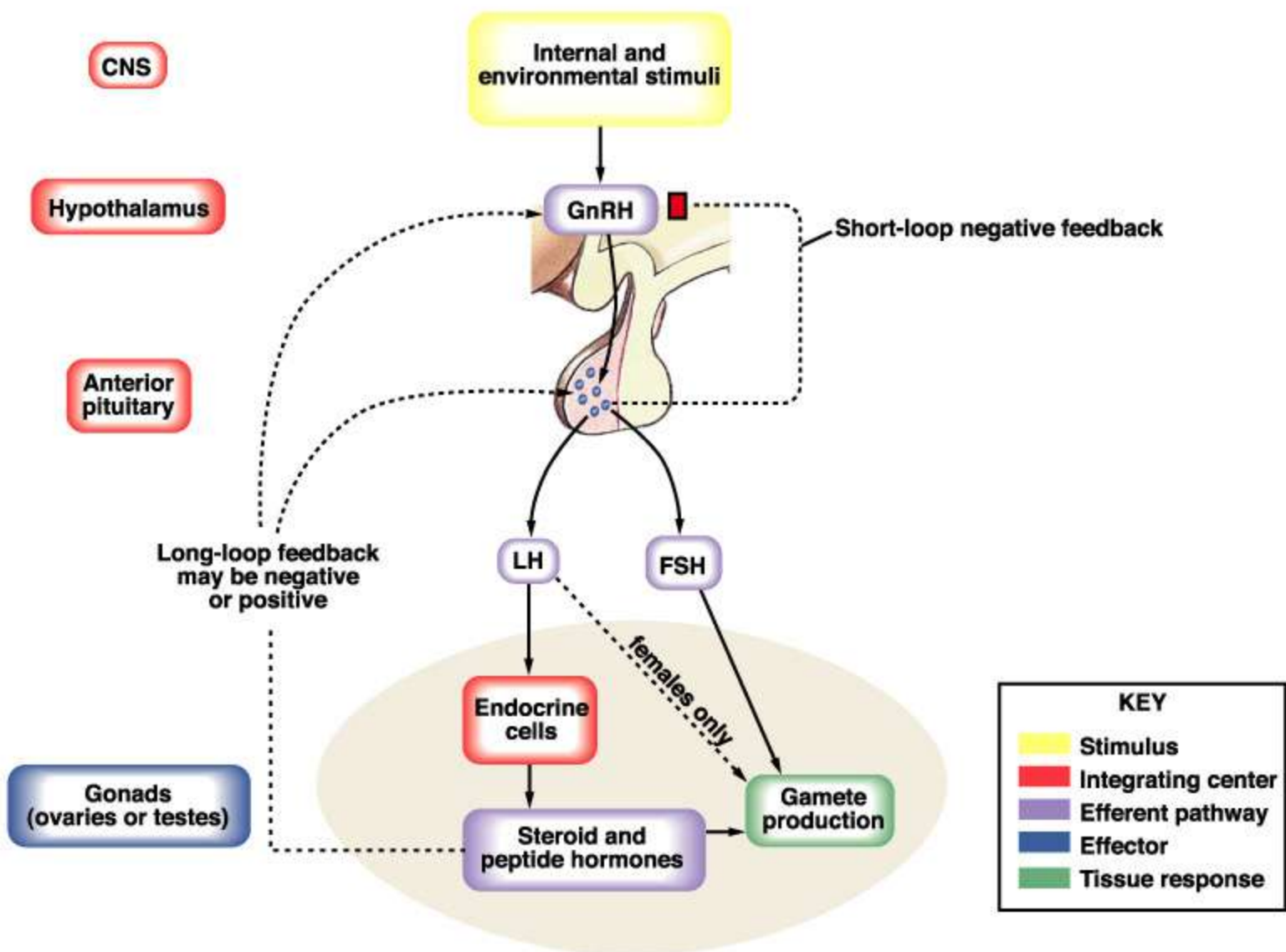
MALE











CNS

Hypothalamus

Anterior pituitary

Gonads (ovaries or testes)

Internal and environmental stimuli

GnRH

LH

FSH

Endocrine cells

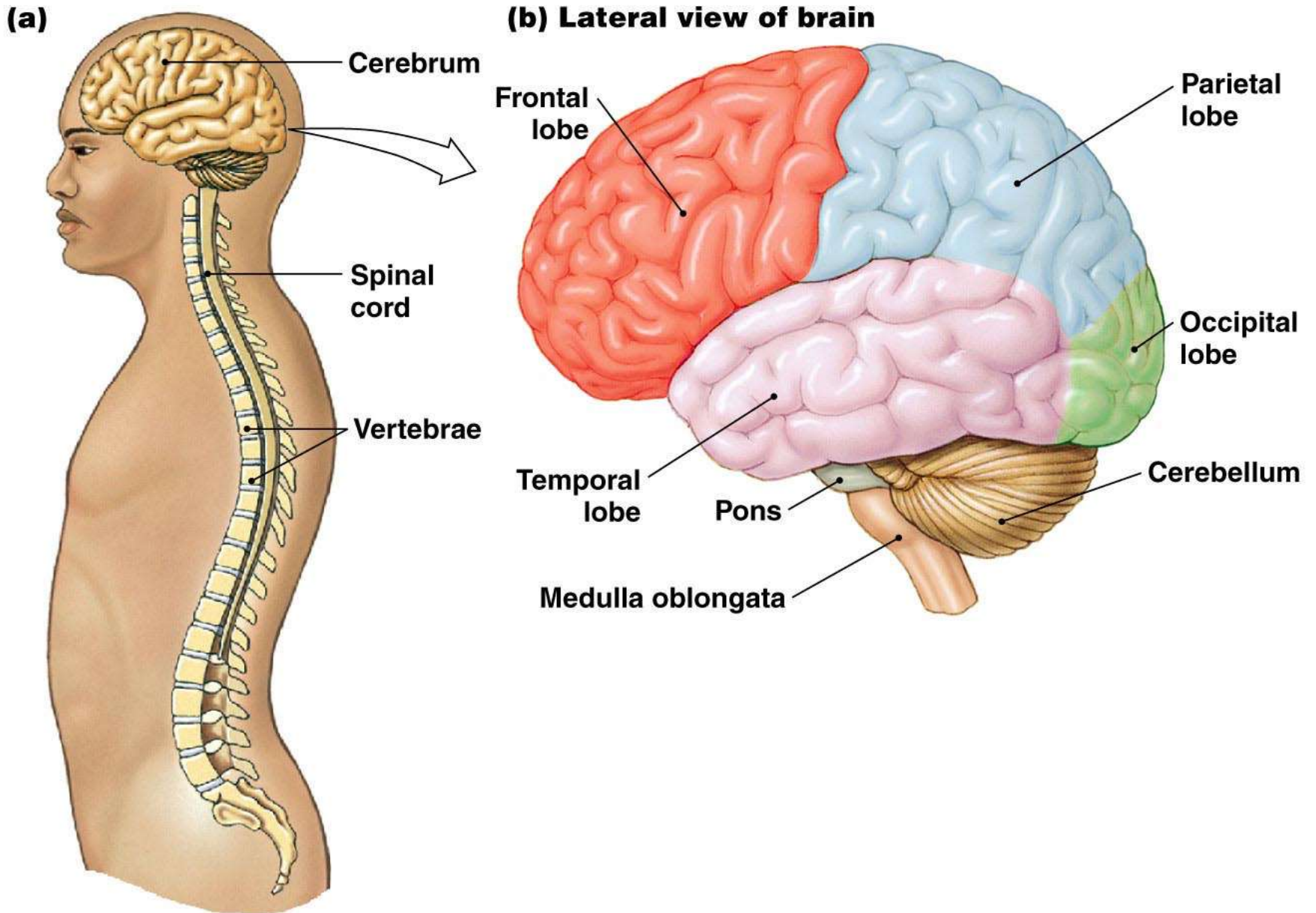
Steroid and peptide hormones

Gamete production

Short-loop negative feedback

Long-loop feedback may be negative or positive

females only



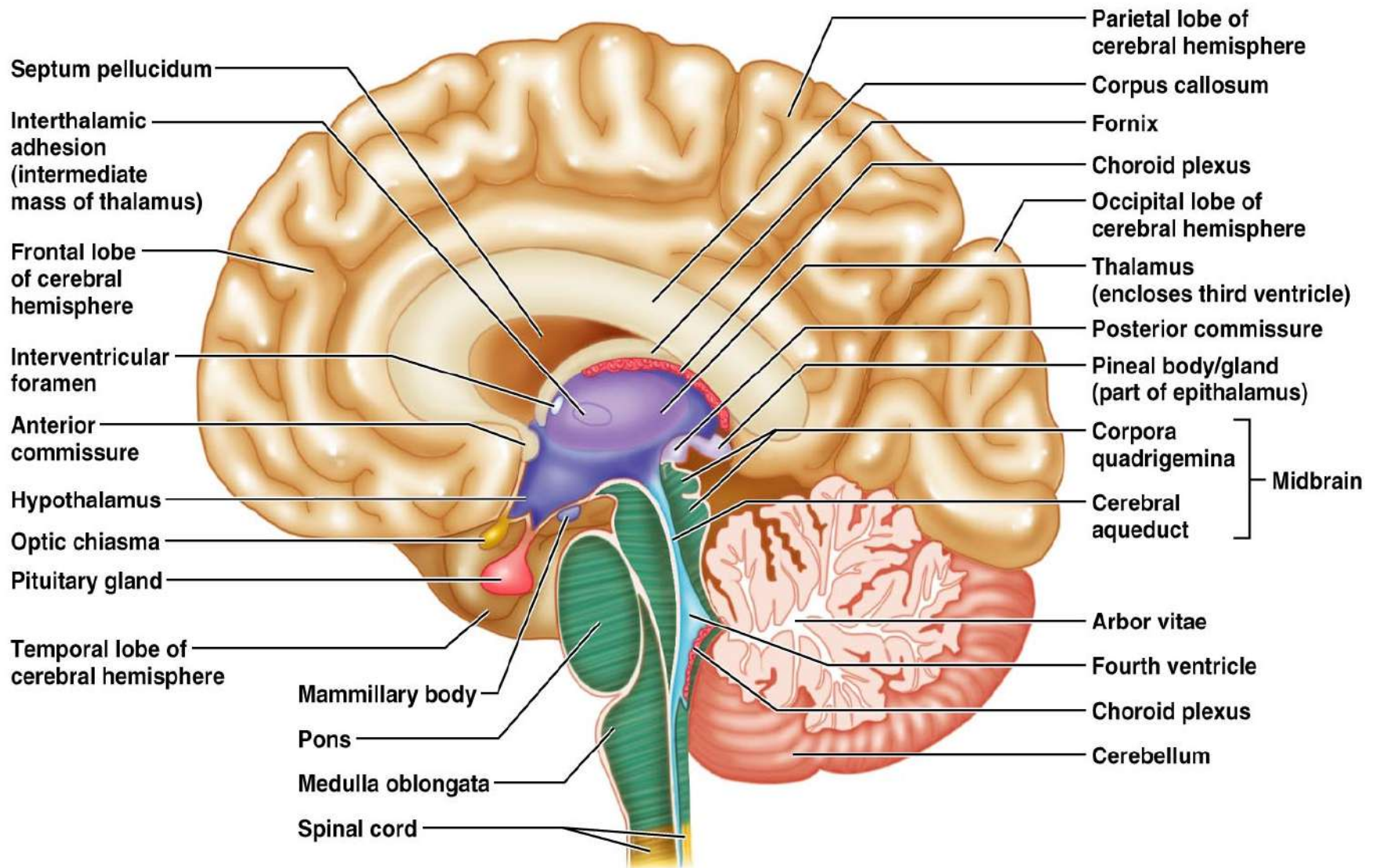
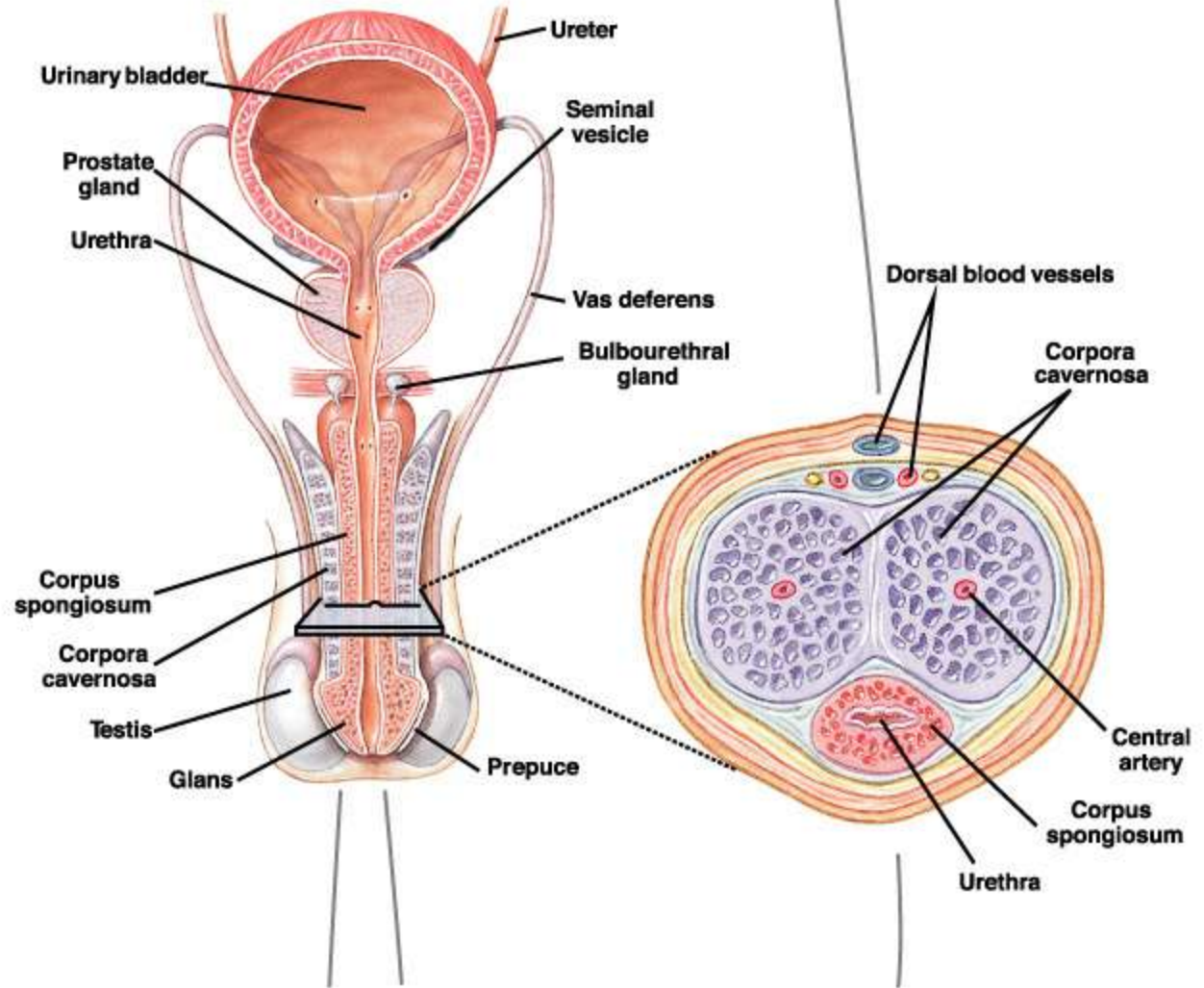
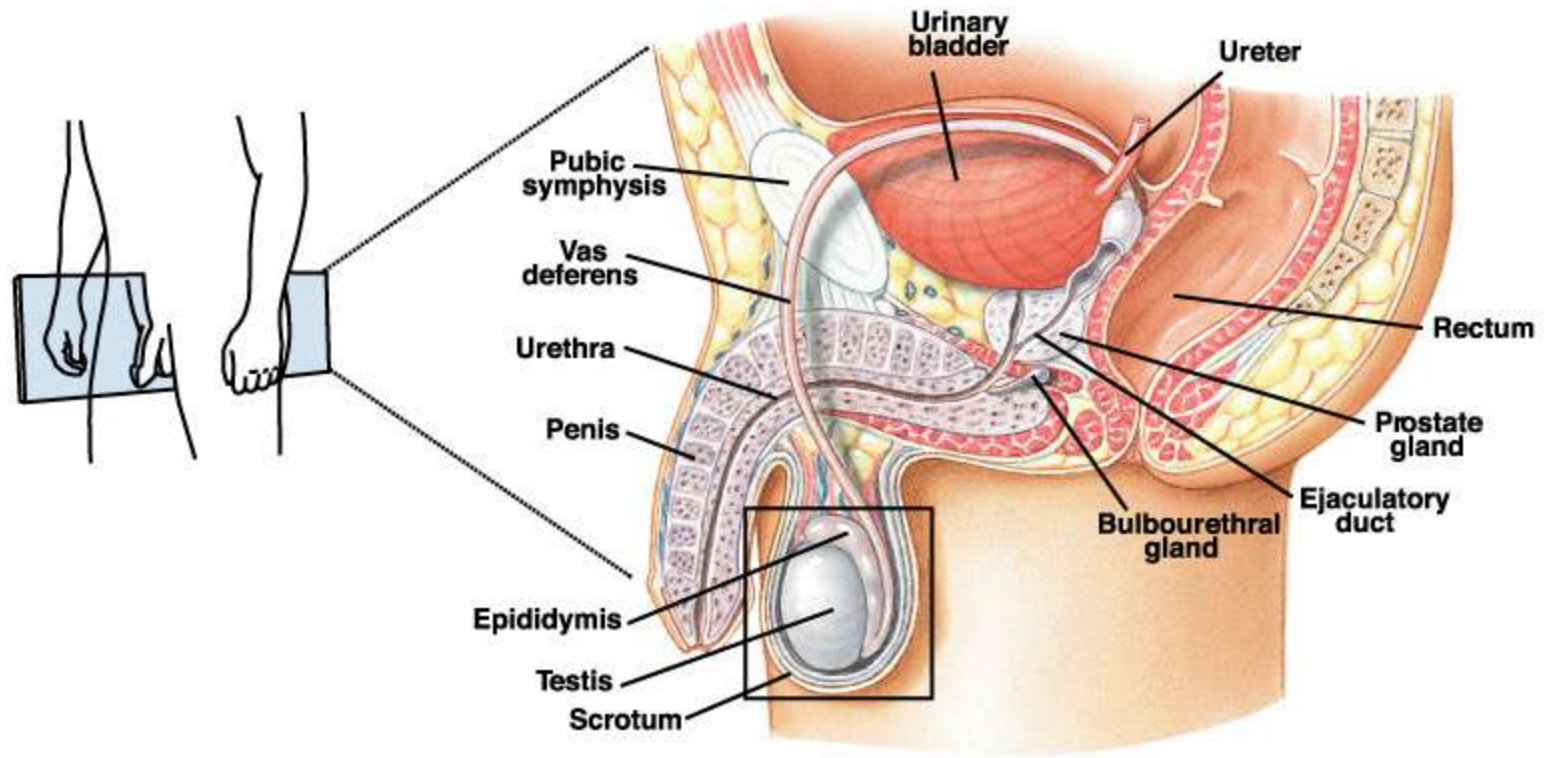
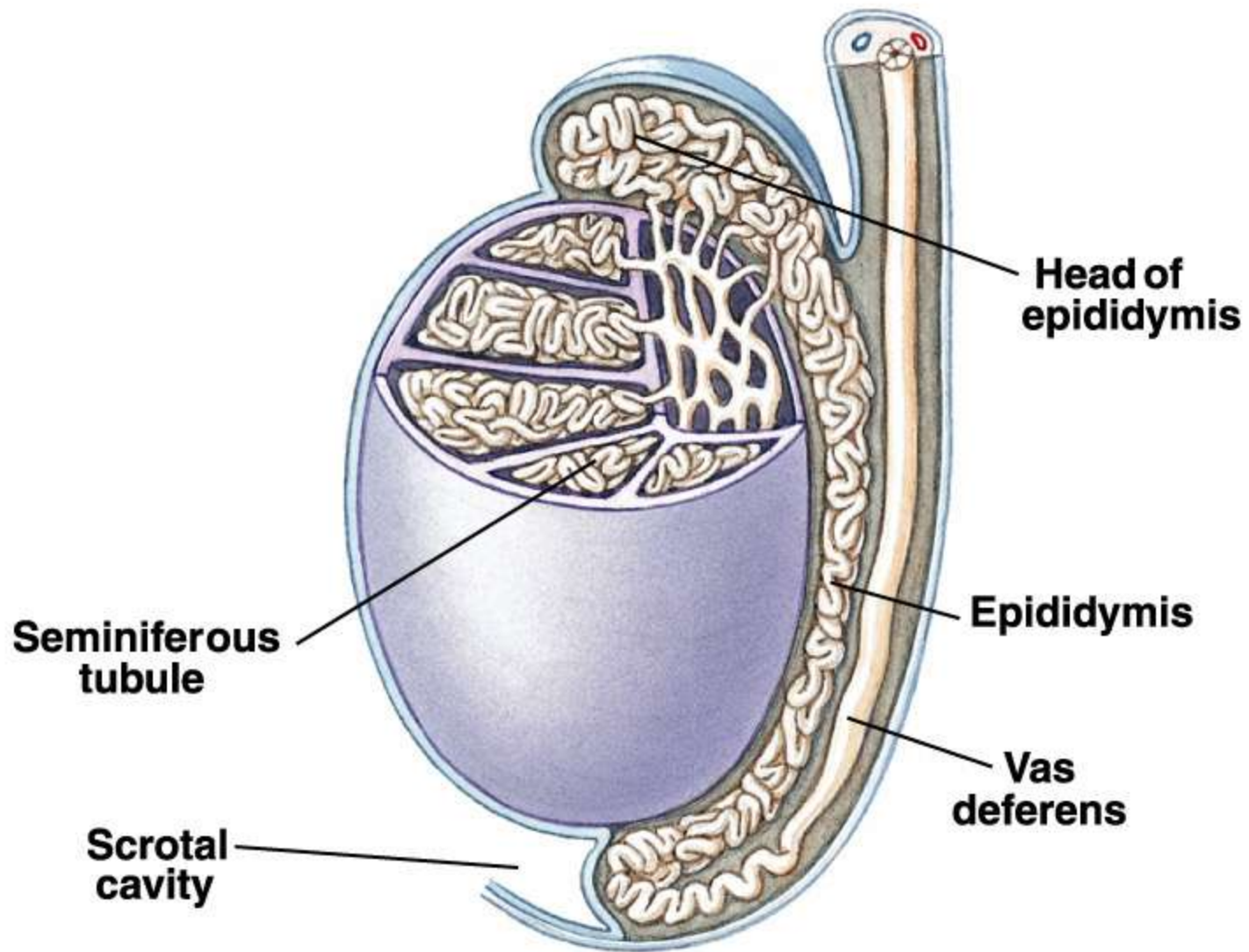
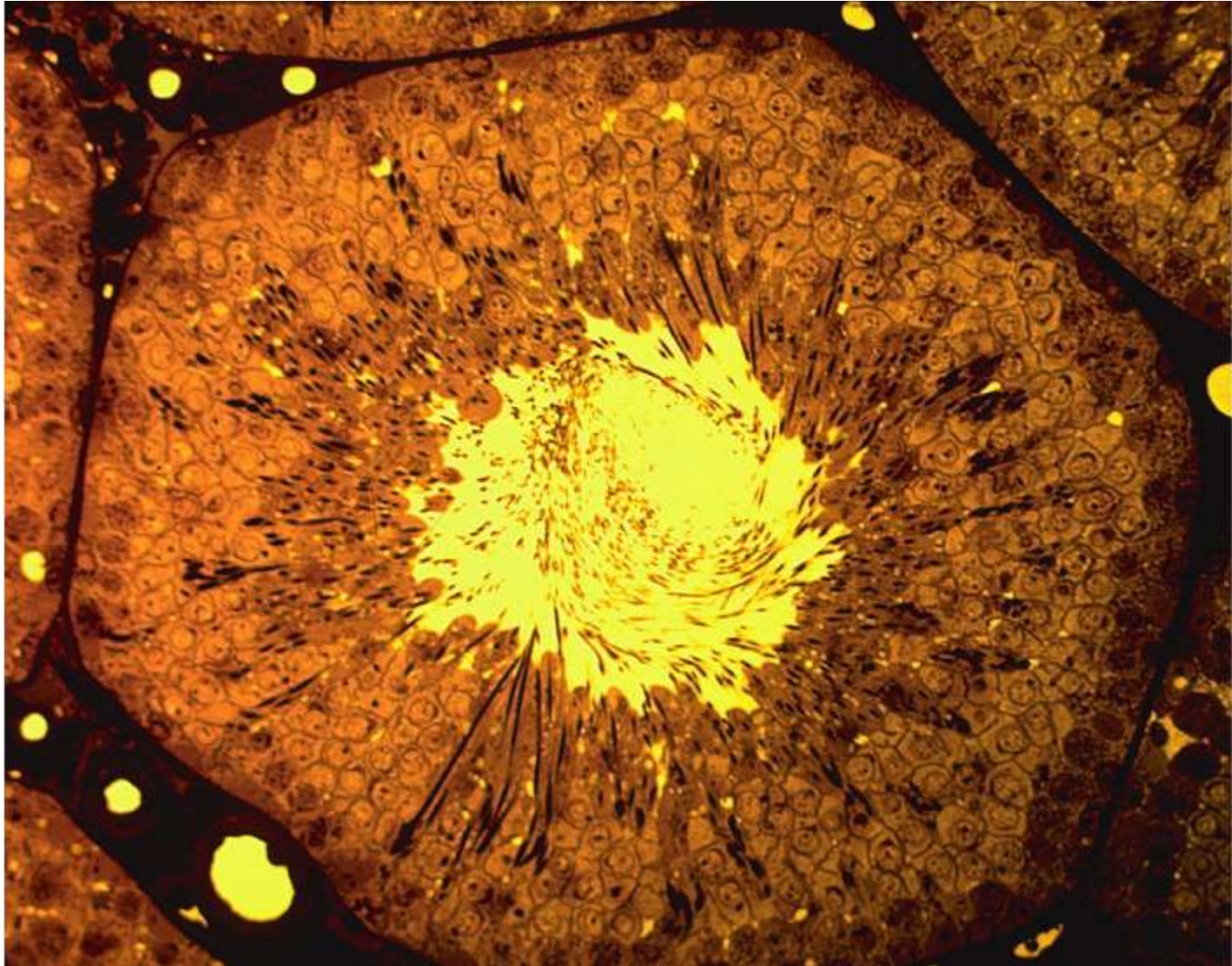


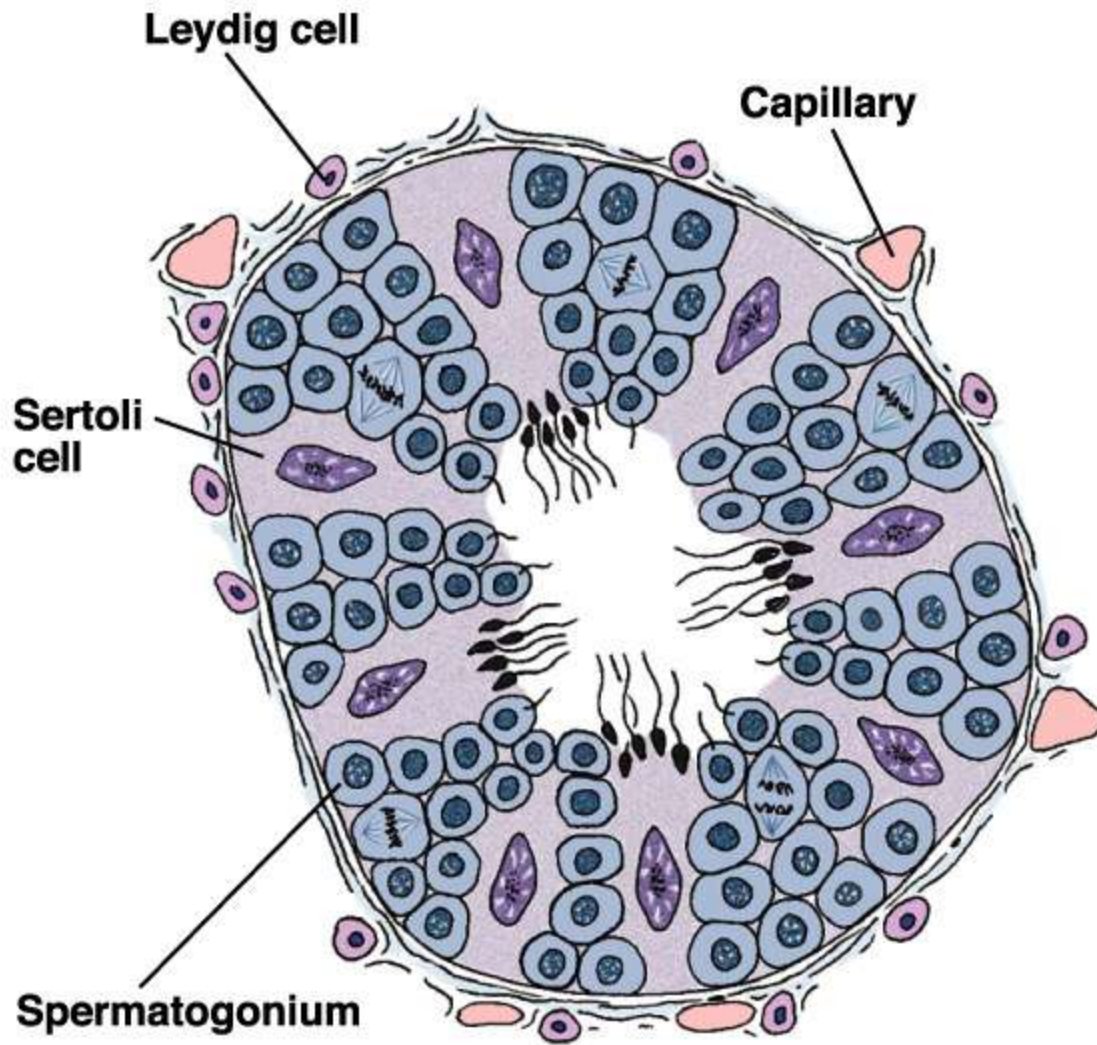
Figure 12.12

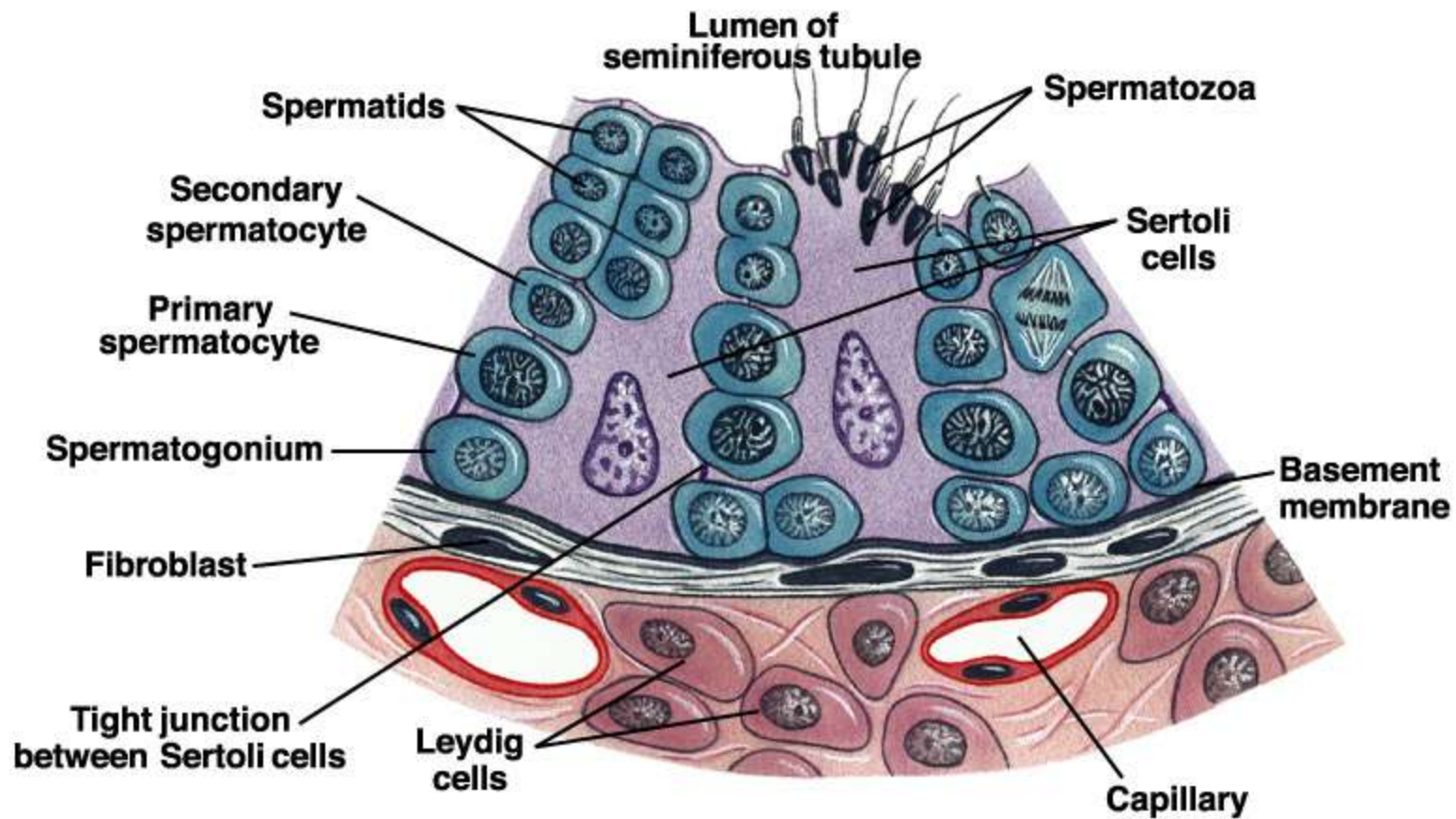


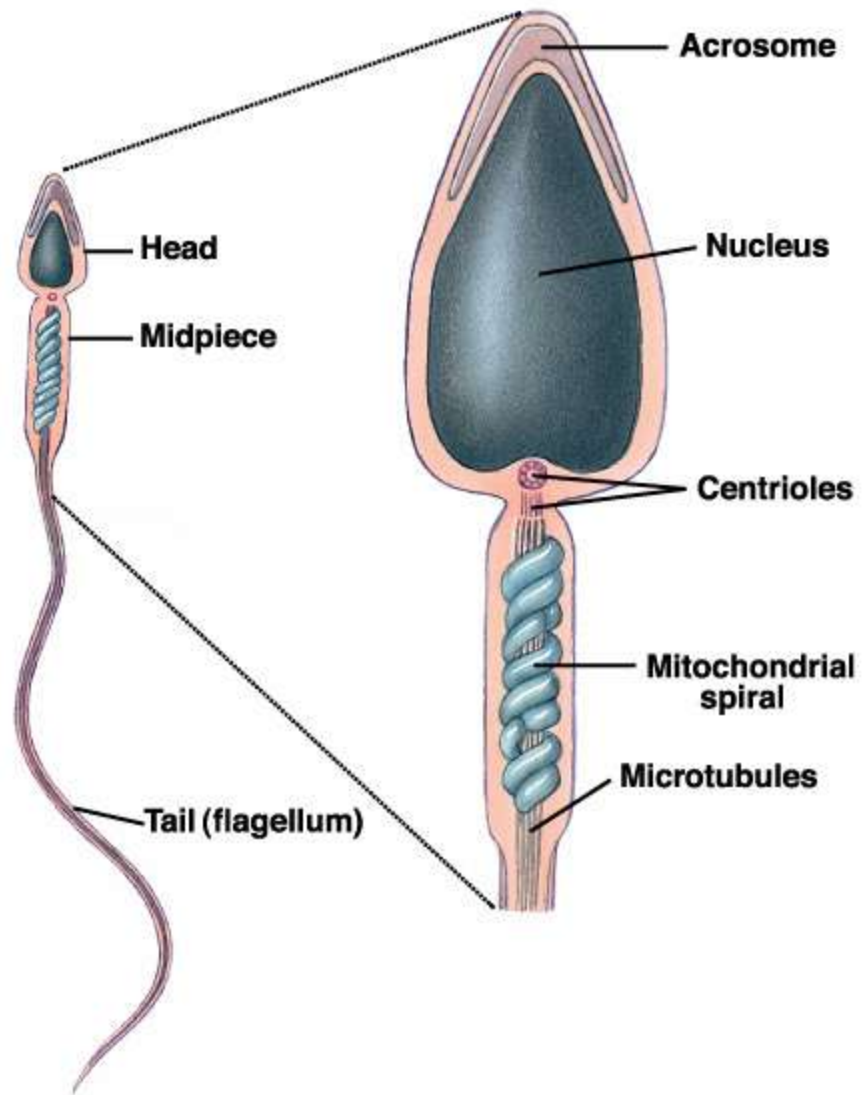


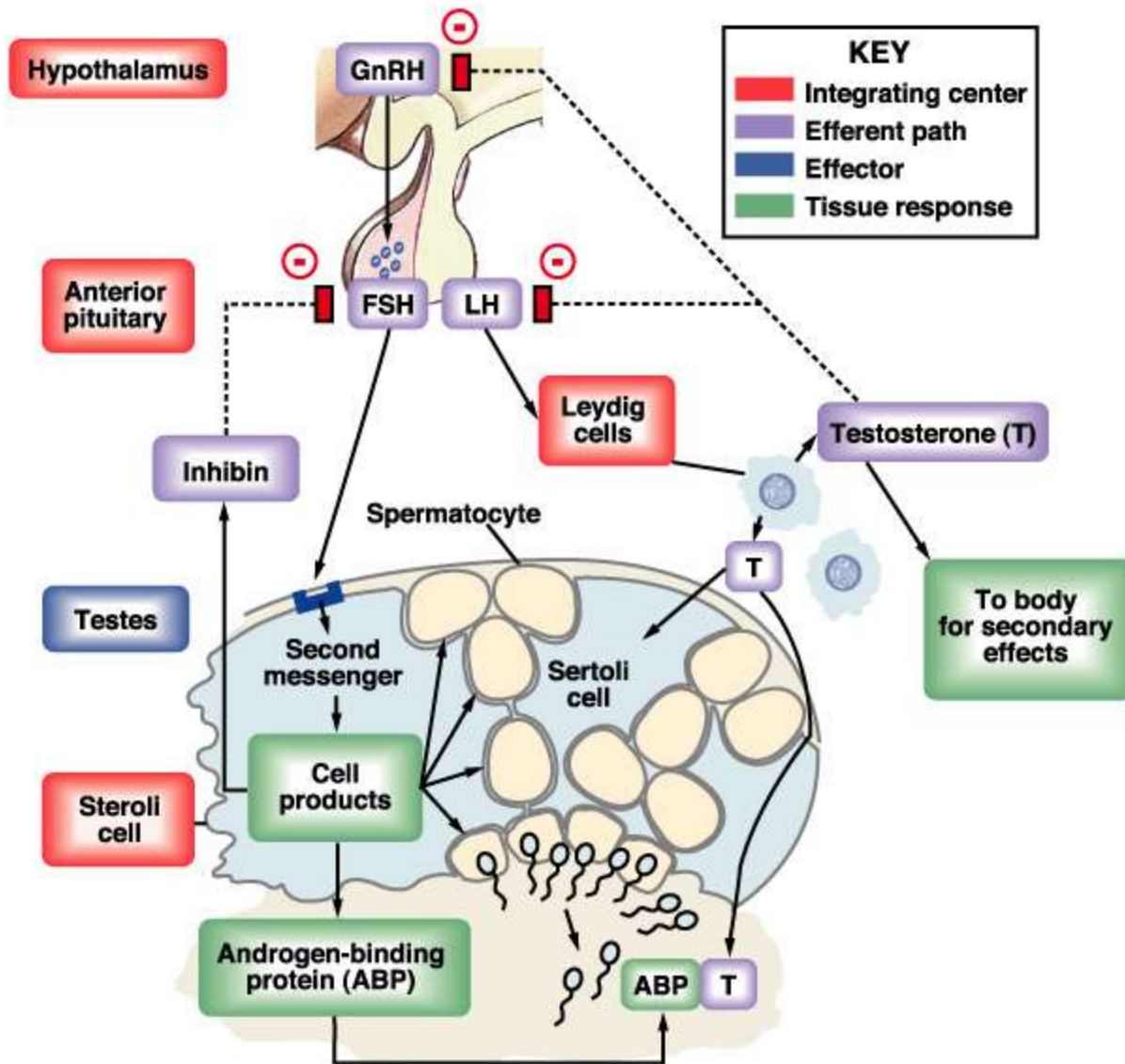


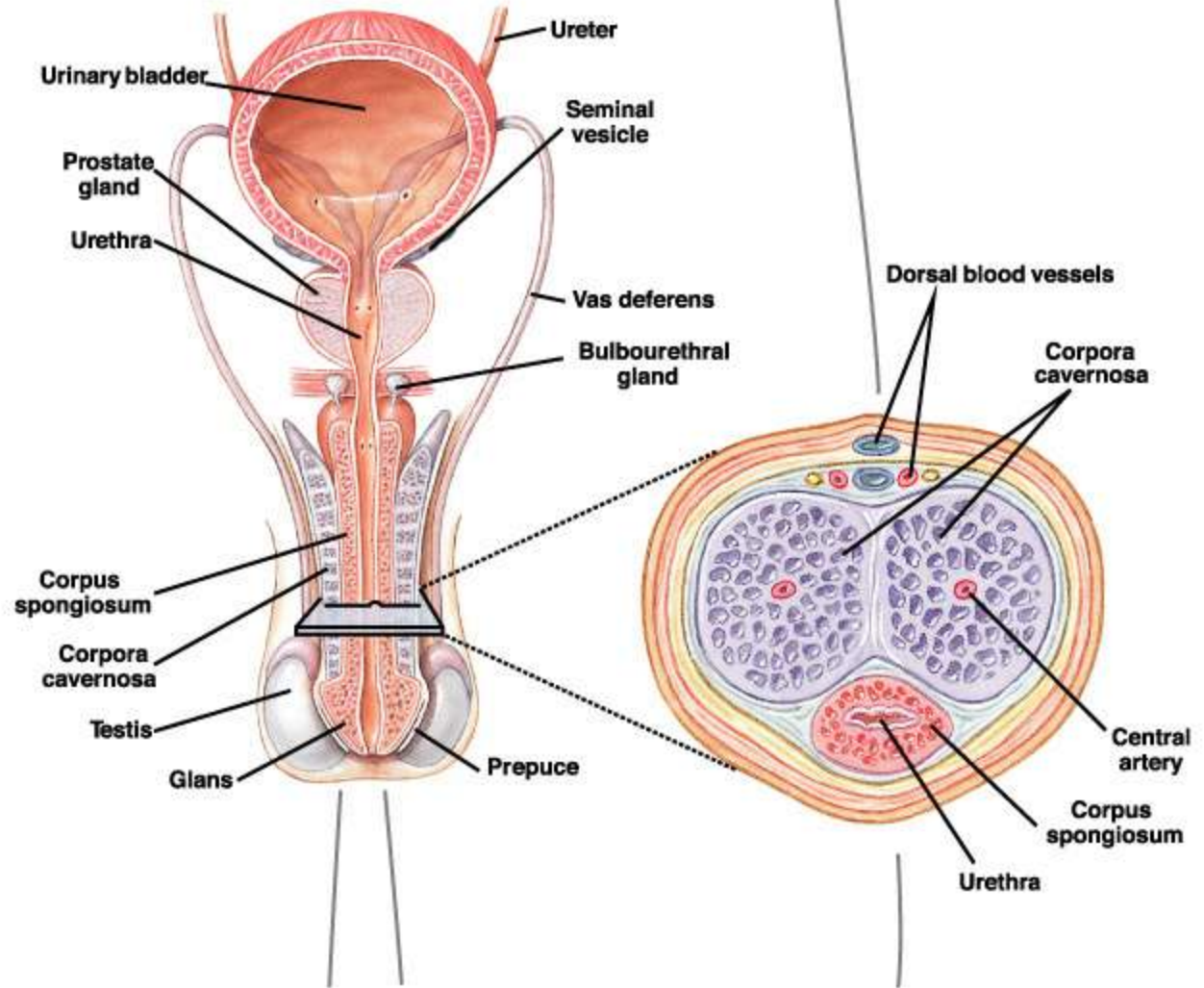


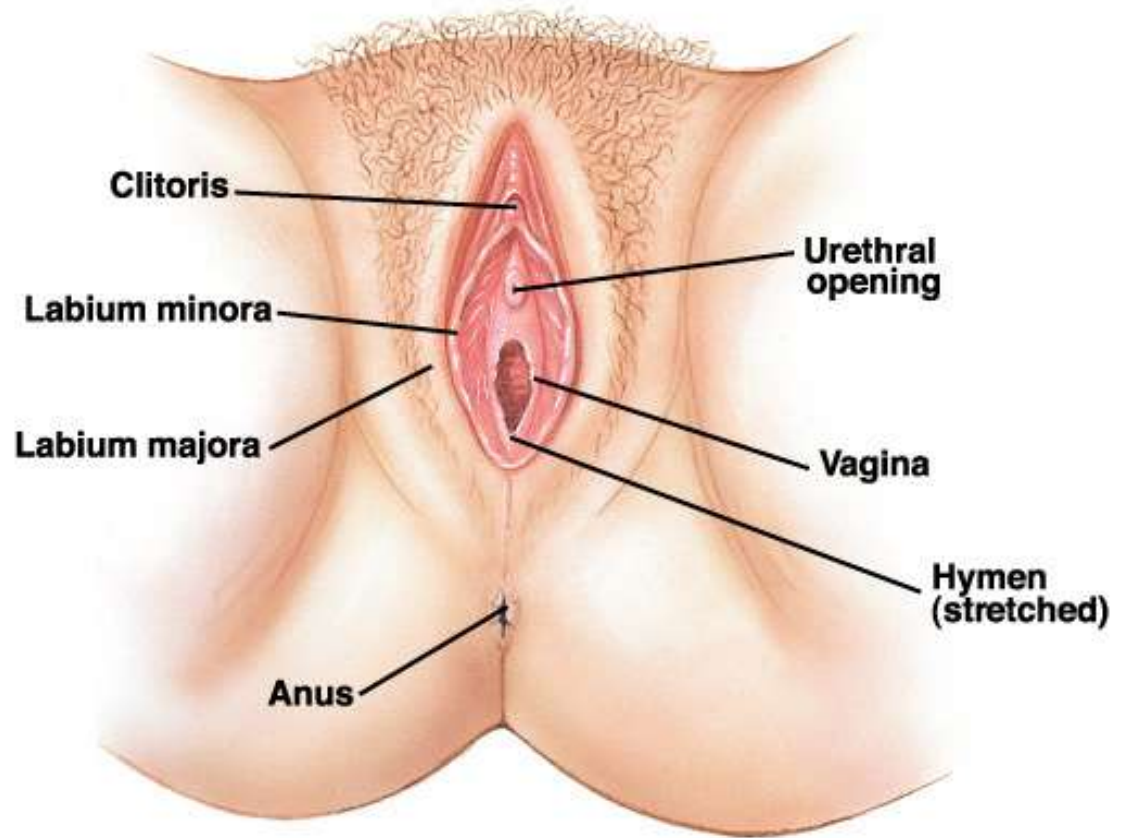
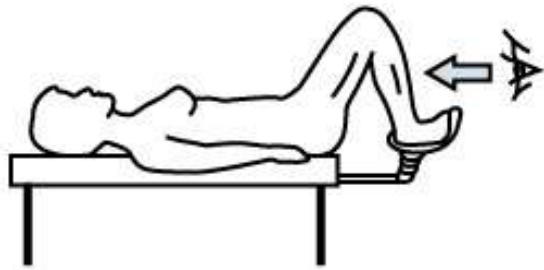

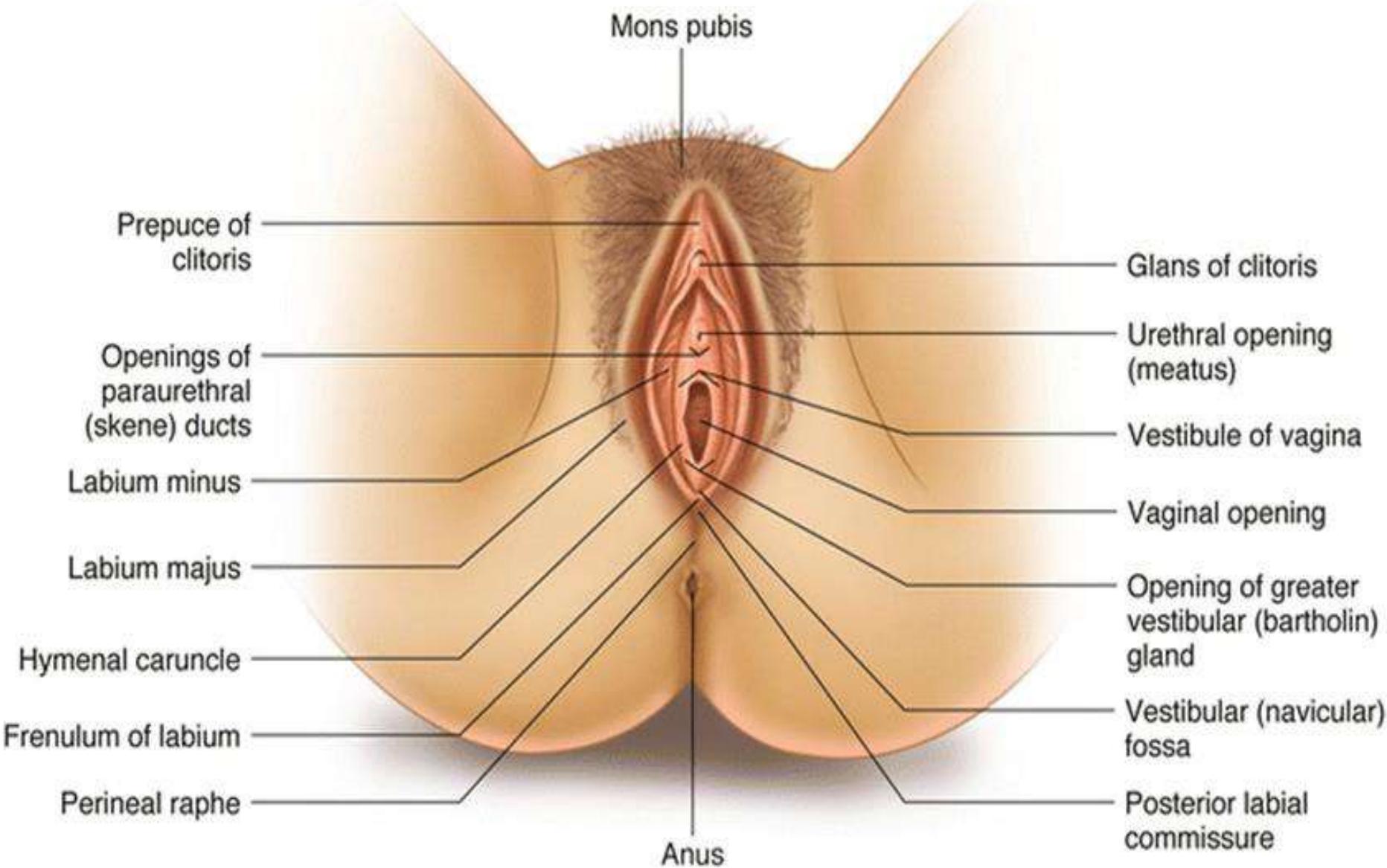


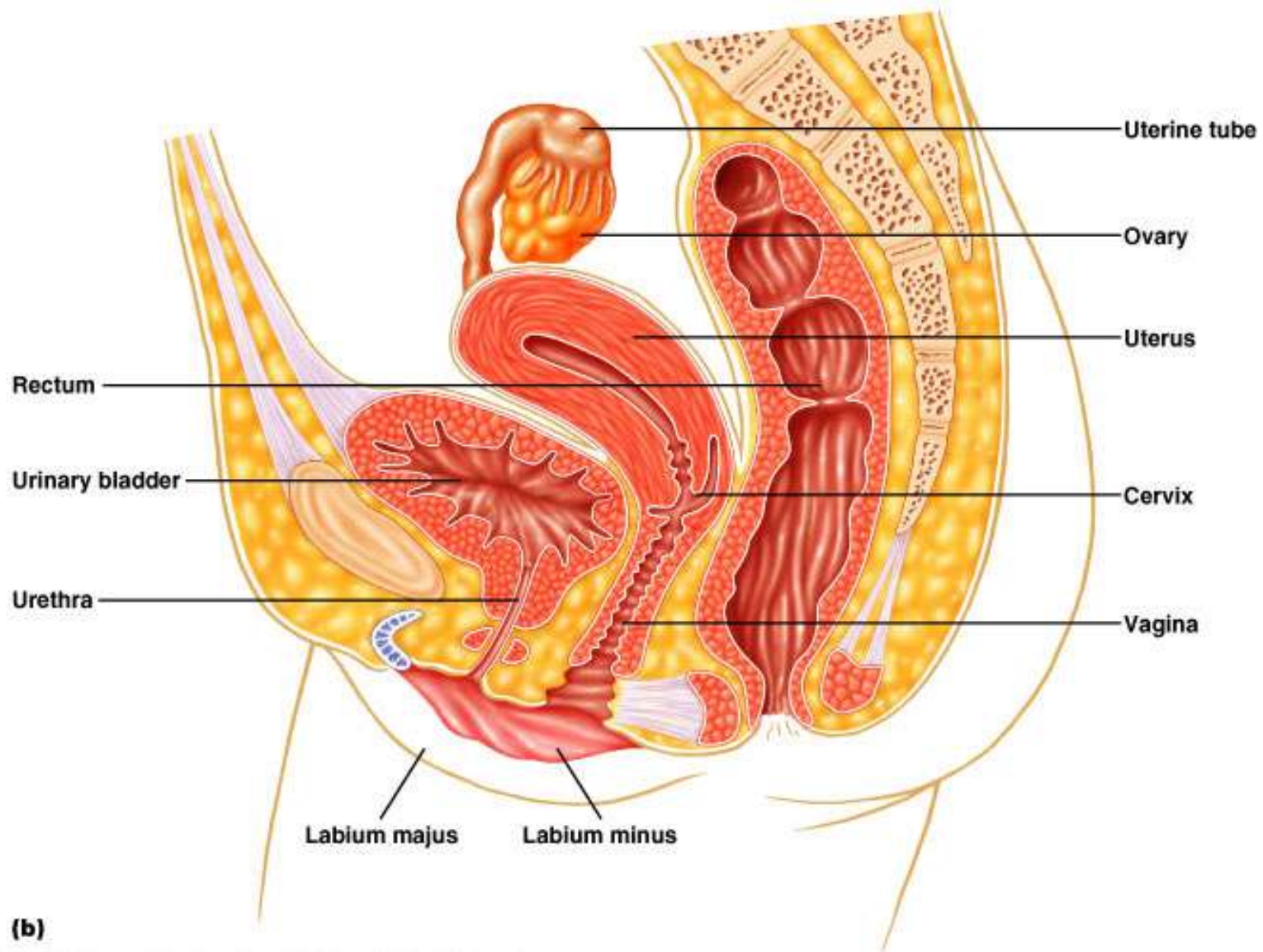


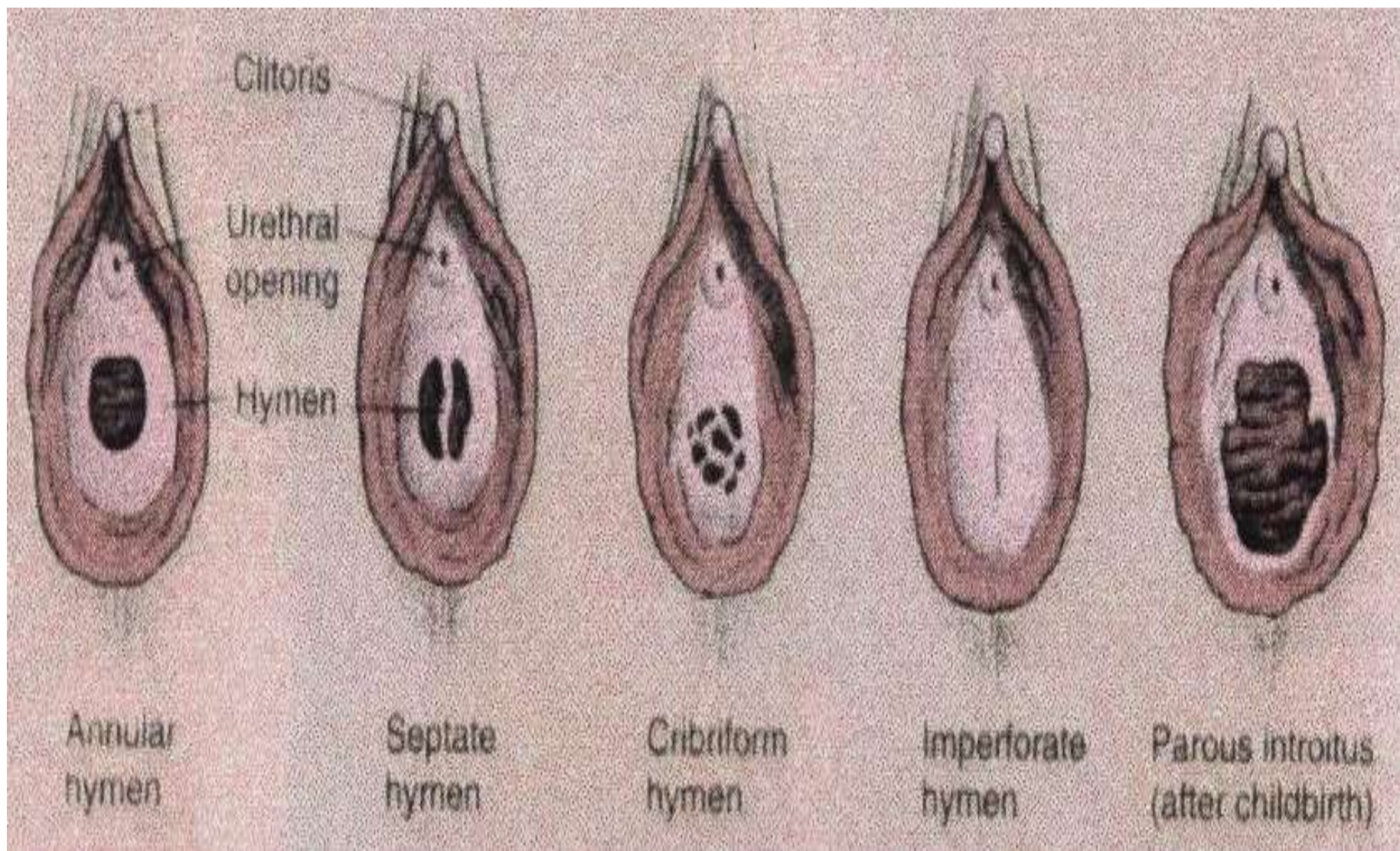


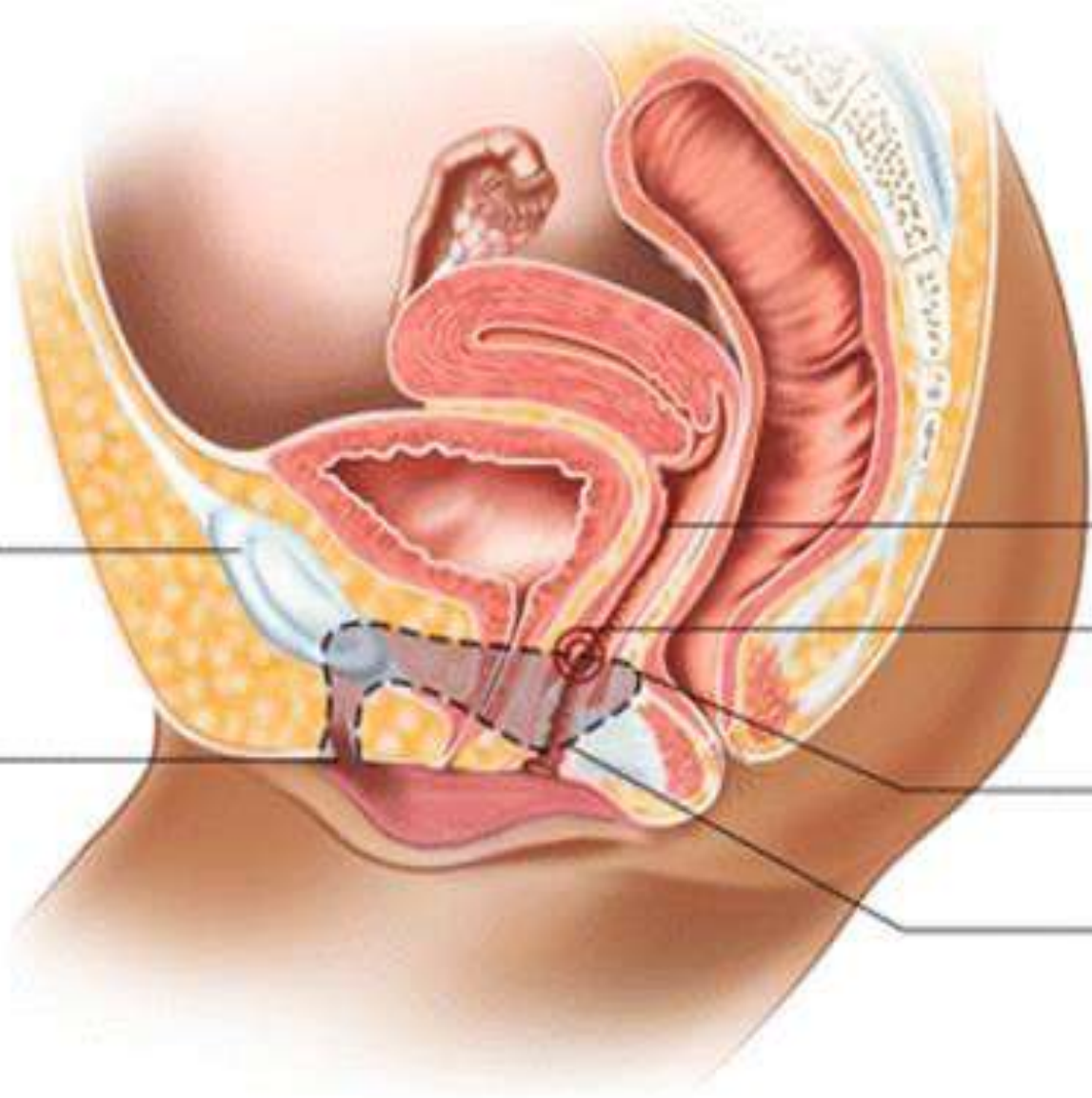












Pubic bone

Vagina

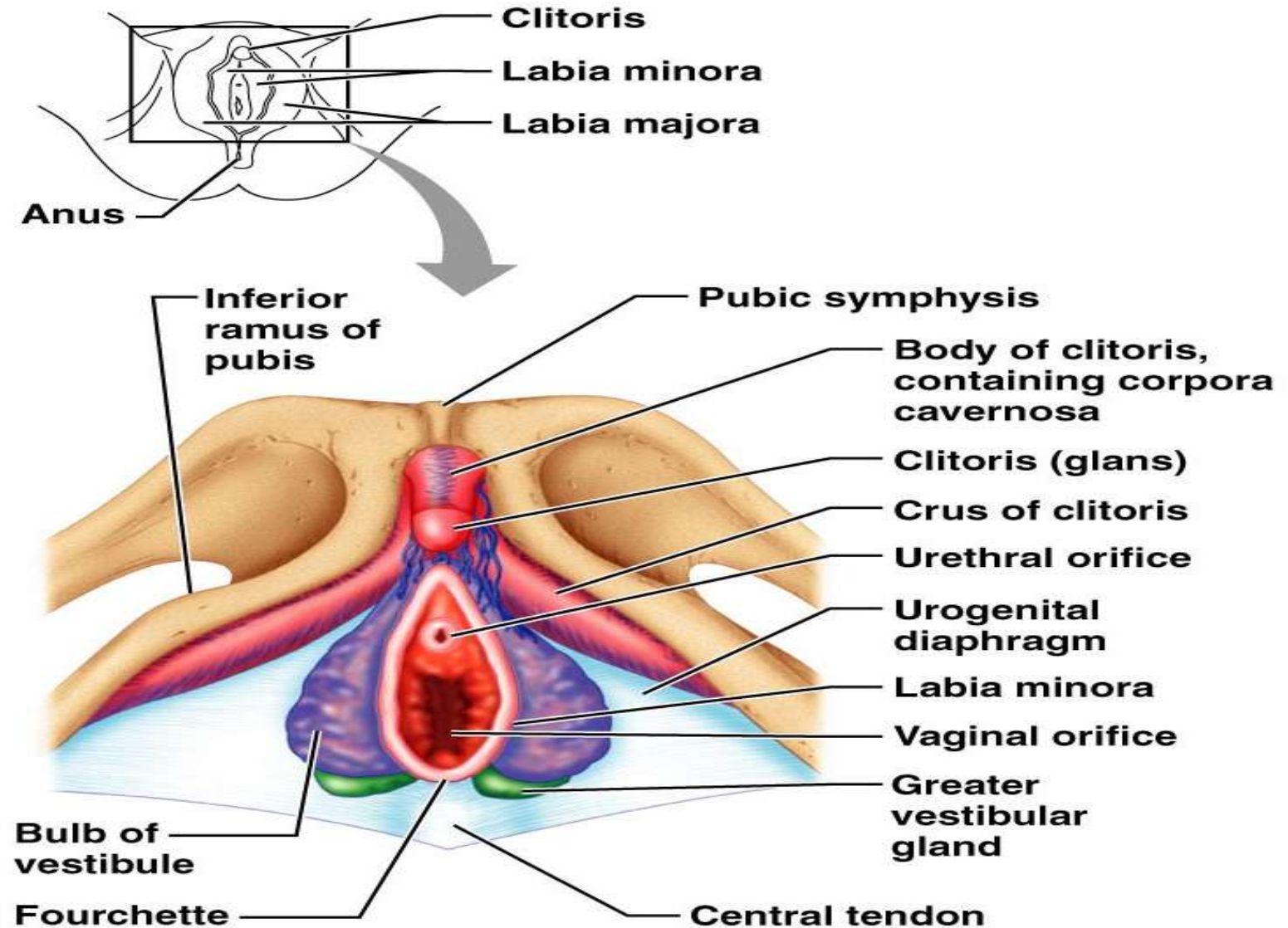
G-spot

Glans clitoris

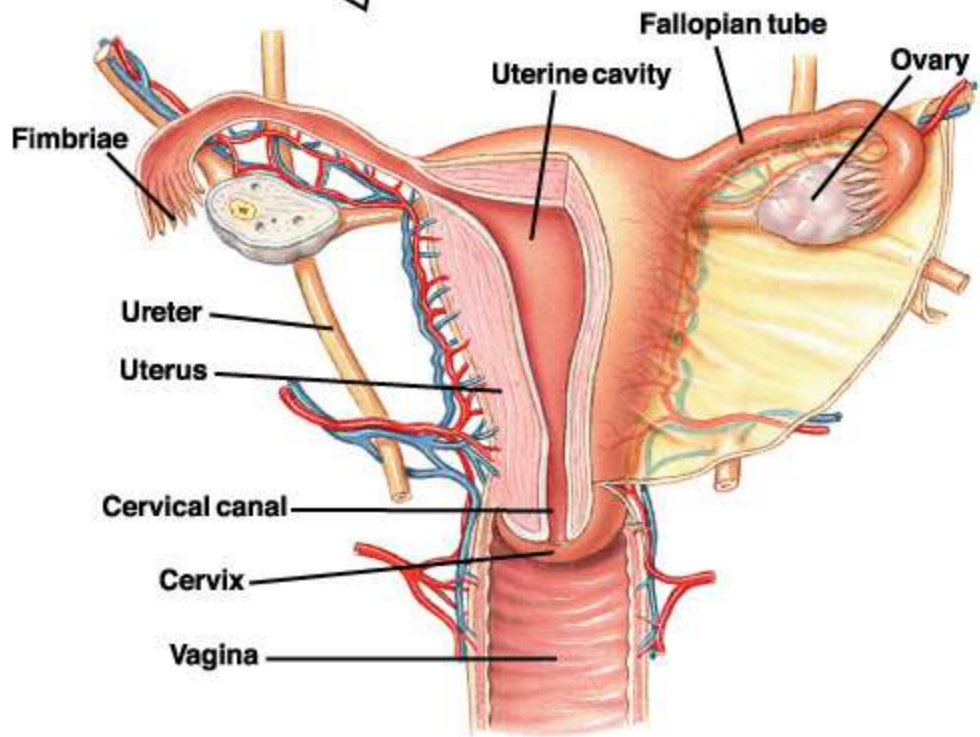
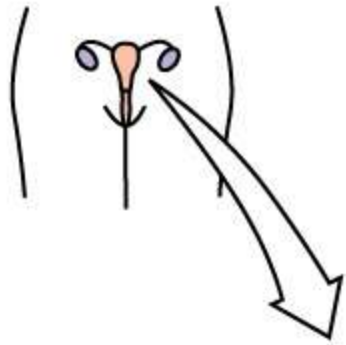
Arm of clitoris

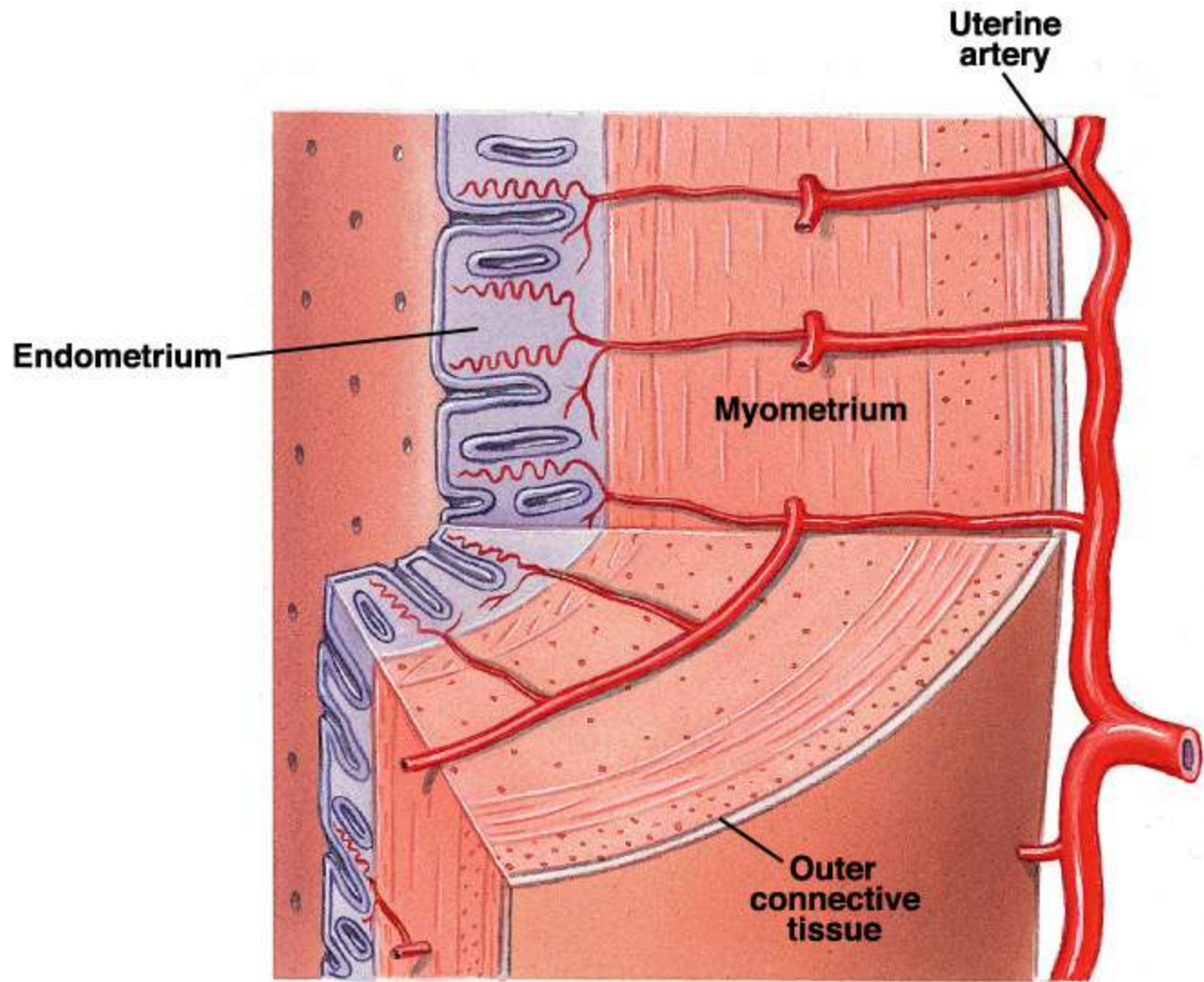
Bulb of clitoris

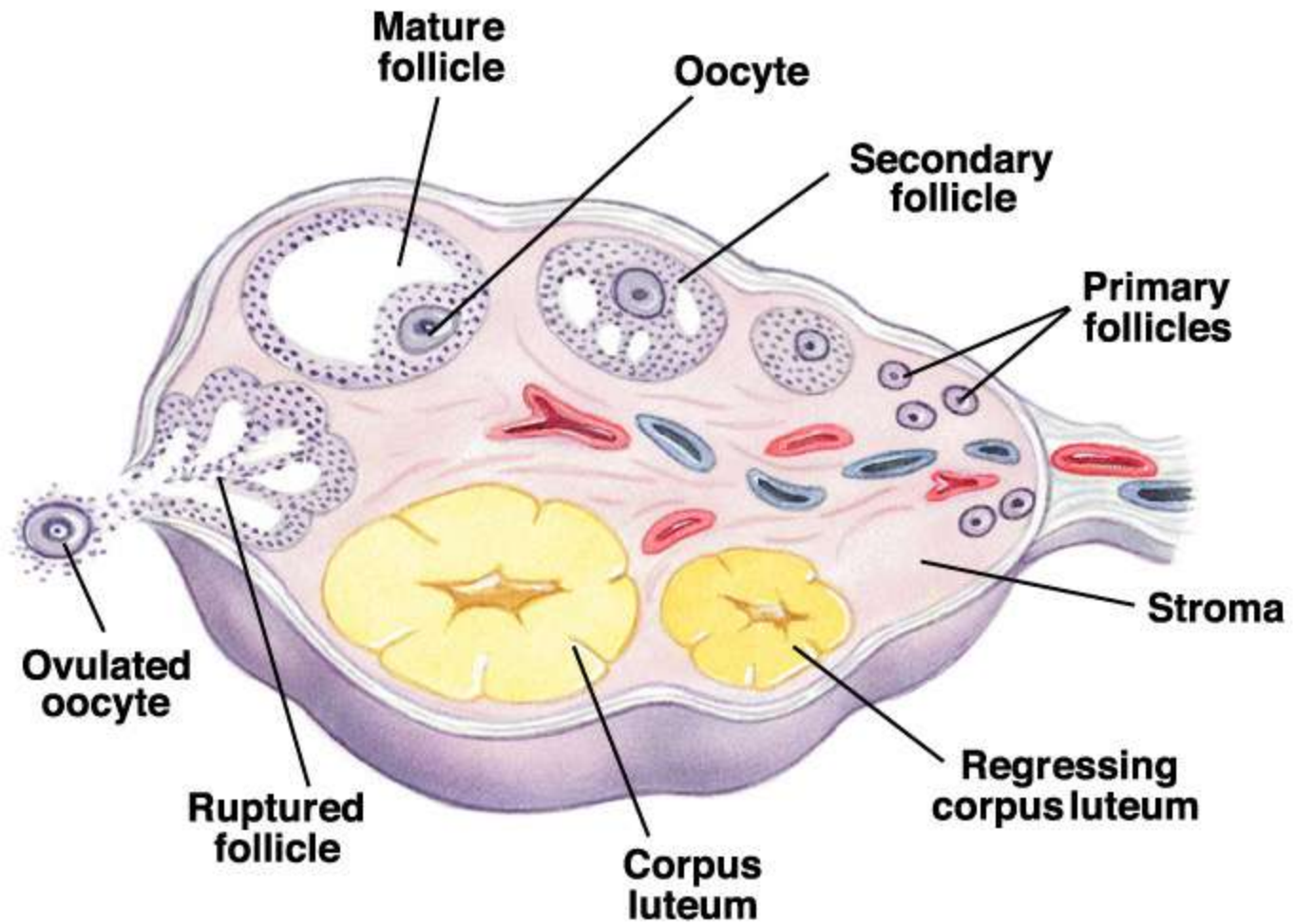
Female External Genitalia: Deep

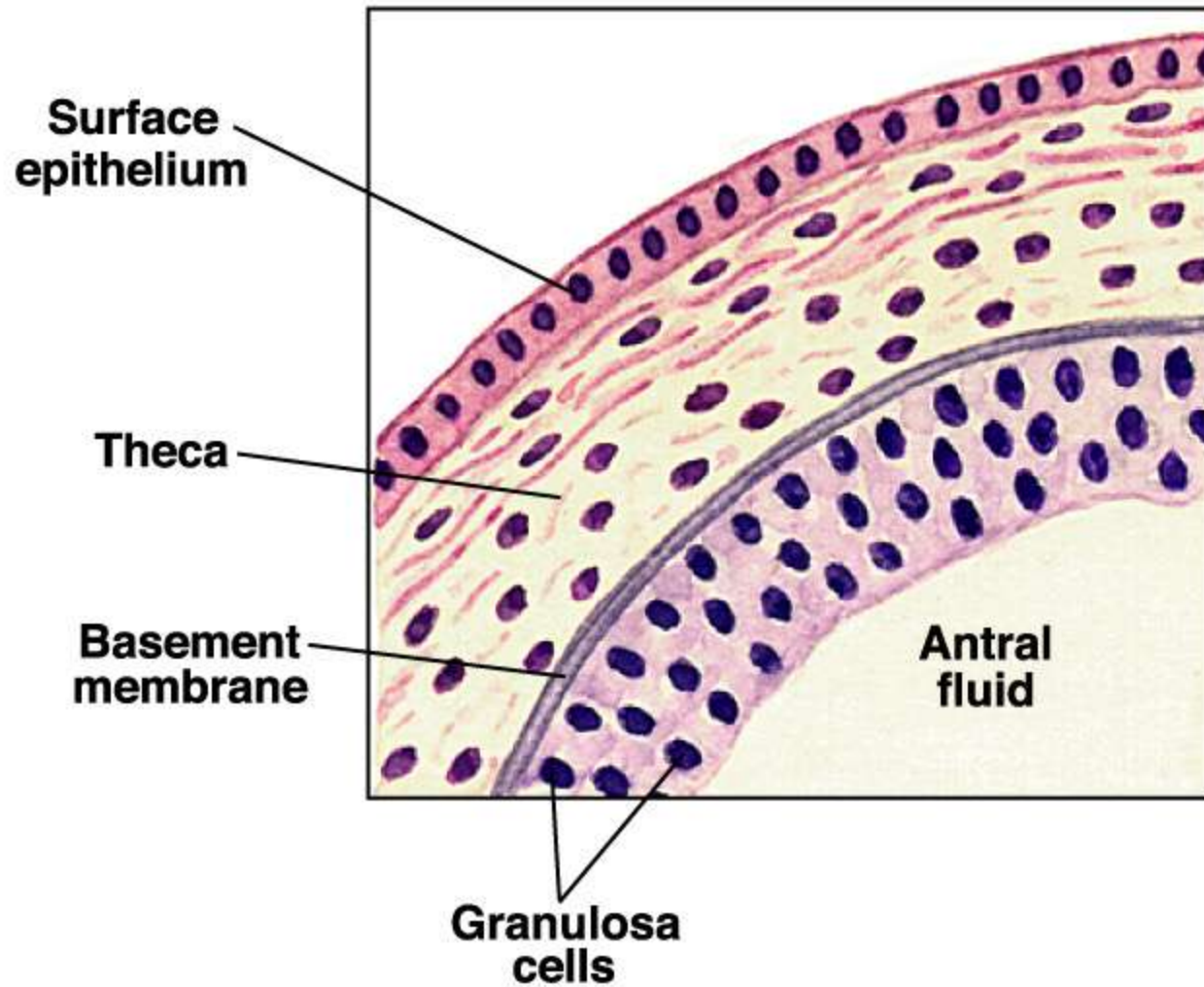


(b)









Feedback Mechanisms in Ovarian Function

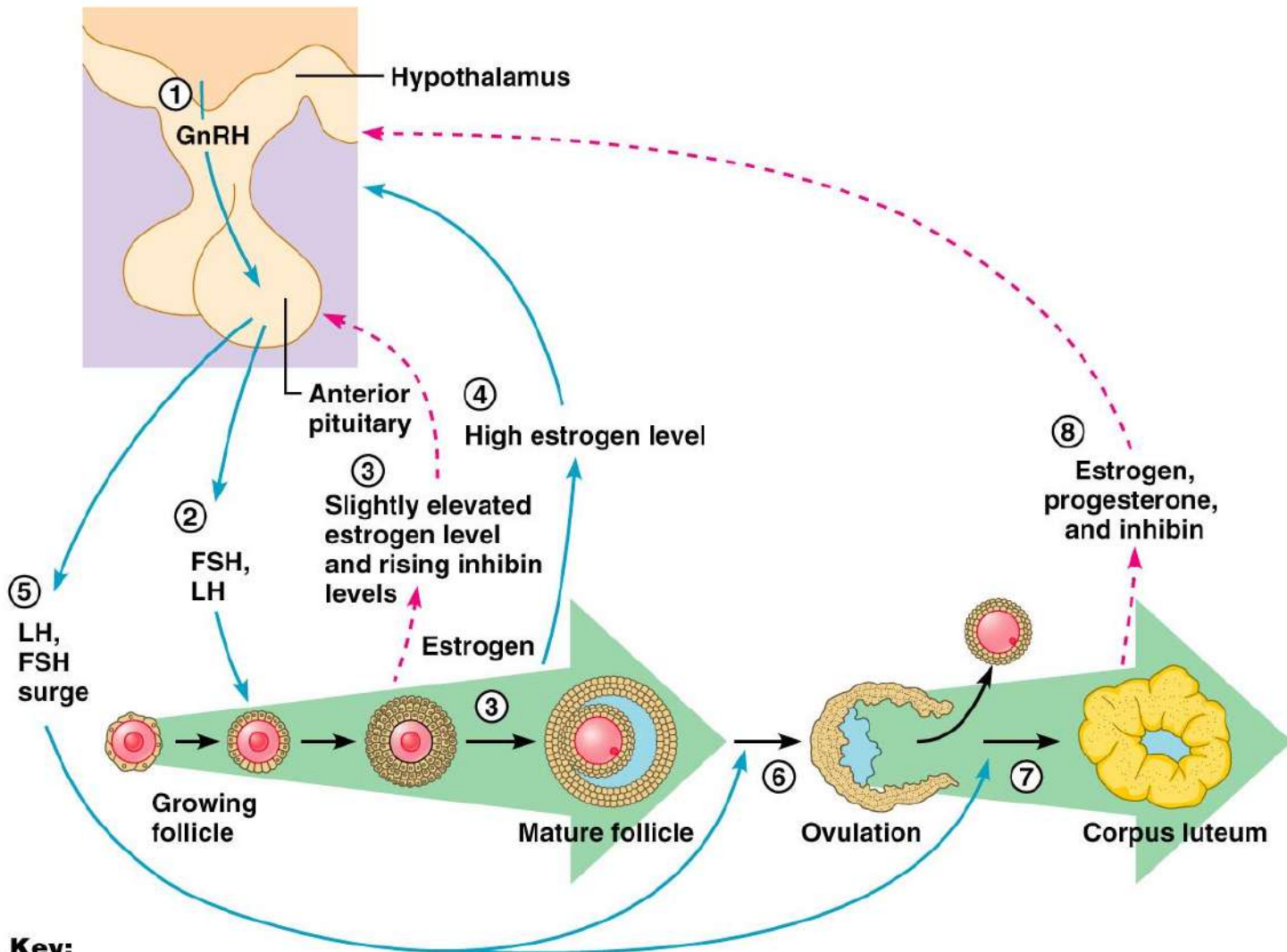
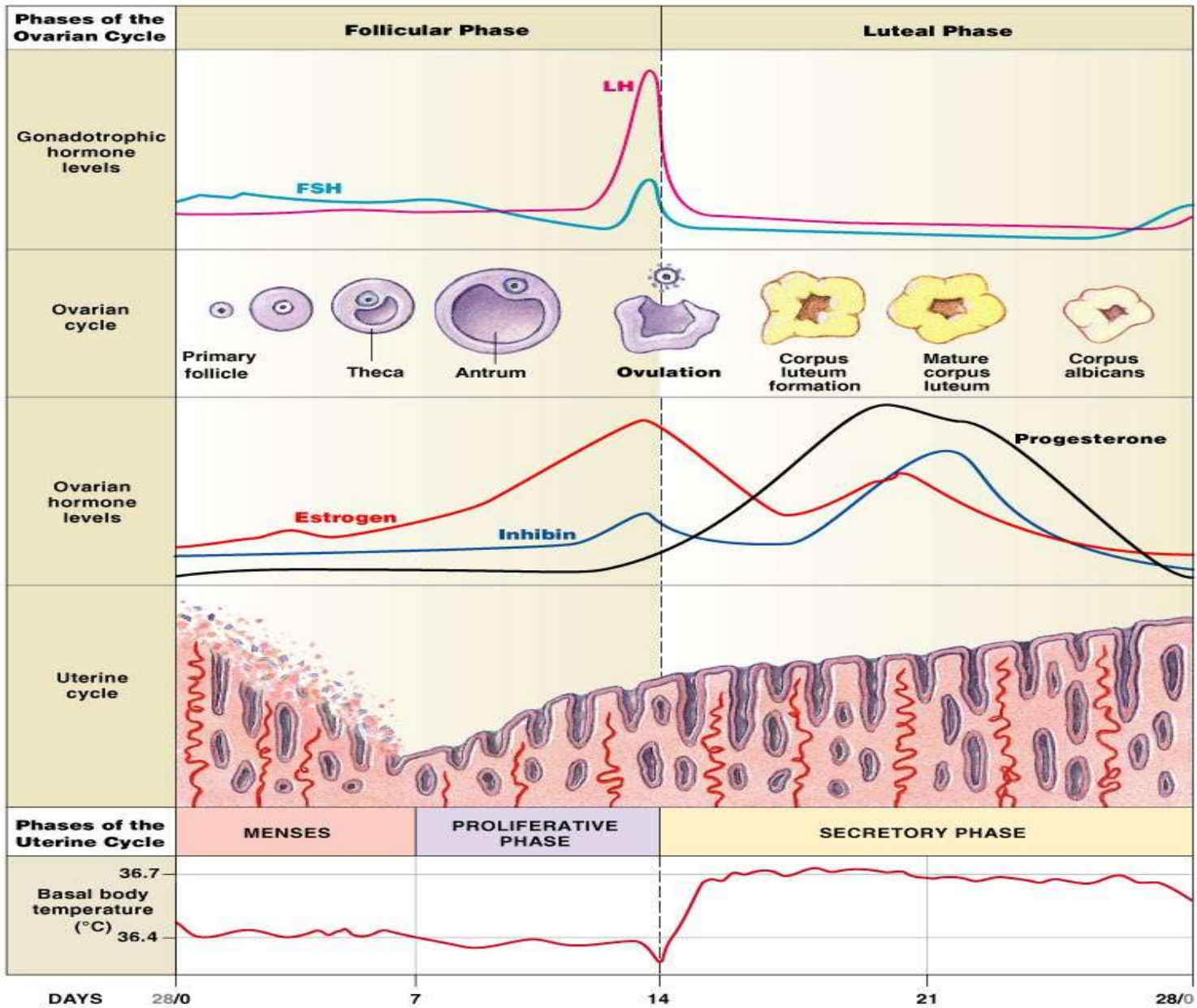


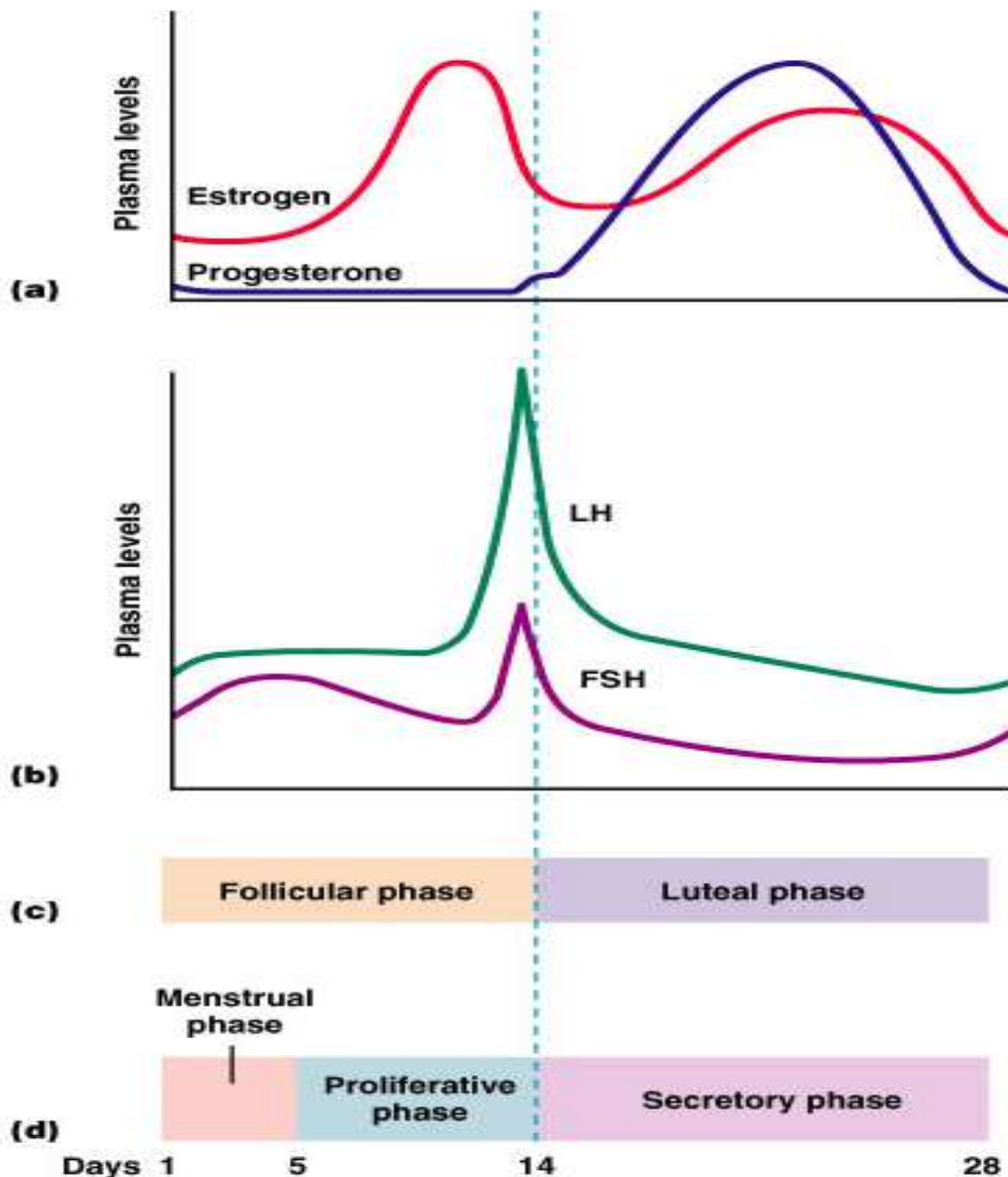
Figure 27.21



Copyright © 2007 Pearson Education, Inc., publishing as Benjamin Cummings.

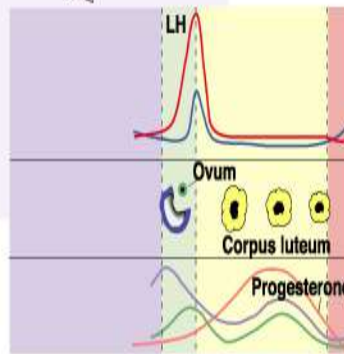
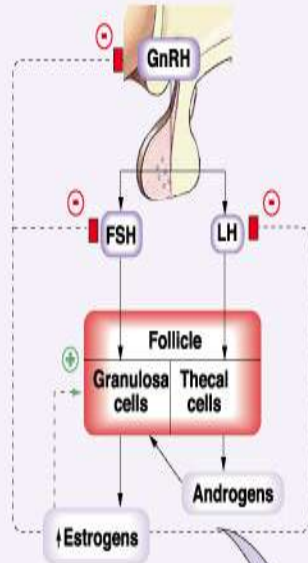
Figure 26-13

Hormonal Changes During Menstrual Cycle

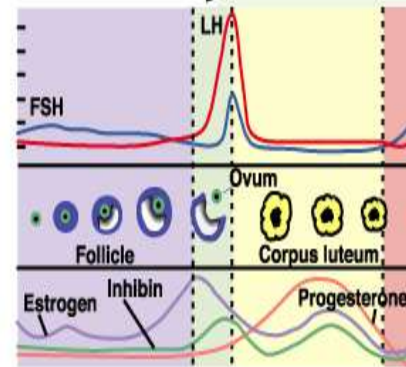
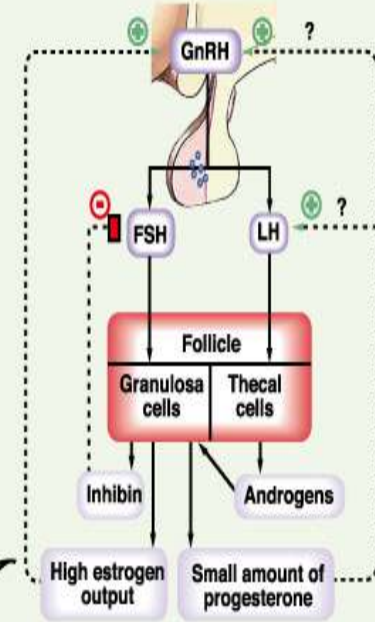


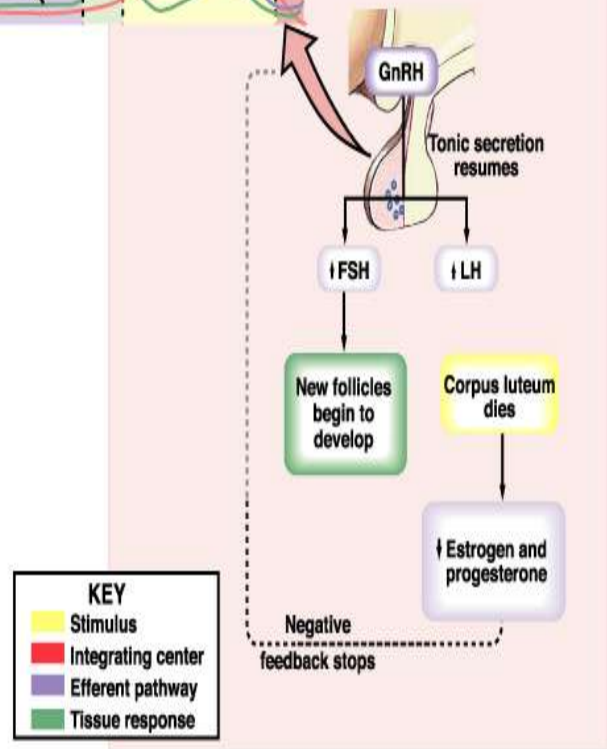
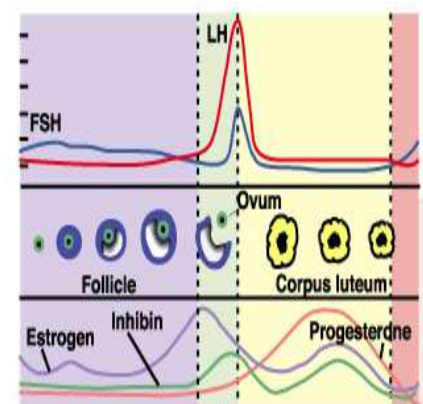
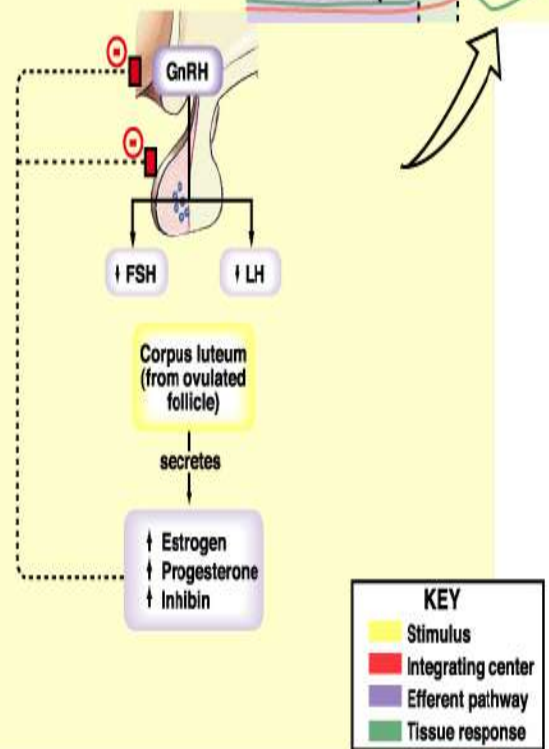
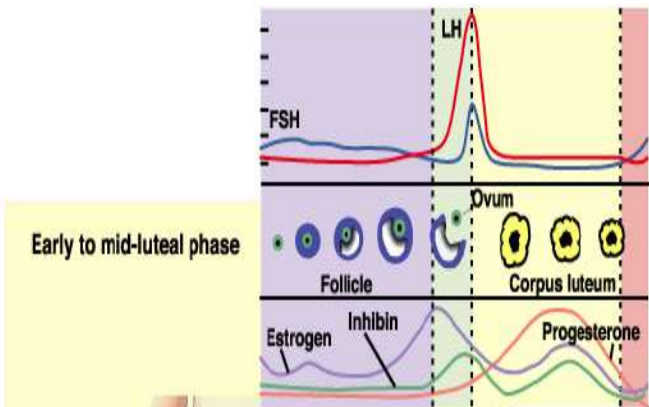
- Estrogen secreted from follicle 1st, then corpus luteum
- Progesterone secreted from corpus luteum
- LH and FSH secreted from anterior pituitary
- Estrogens and progesterone inhibit LH and FSH secretion

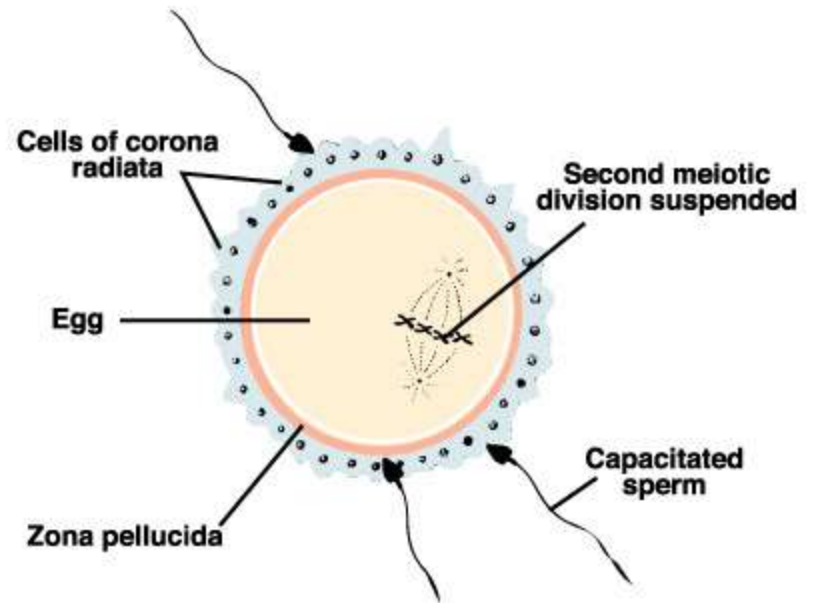
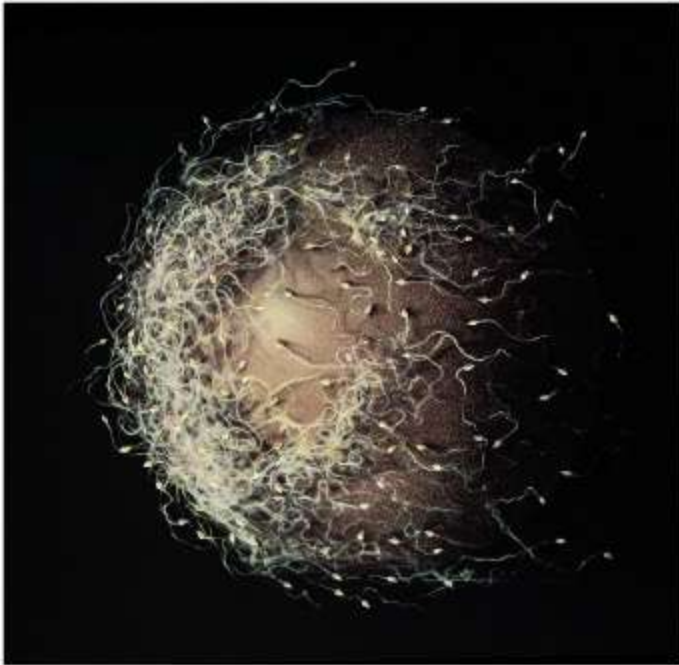Early to mid-follicular phase

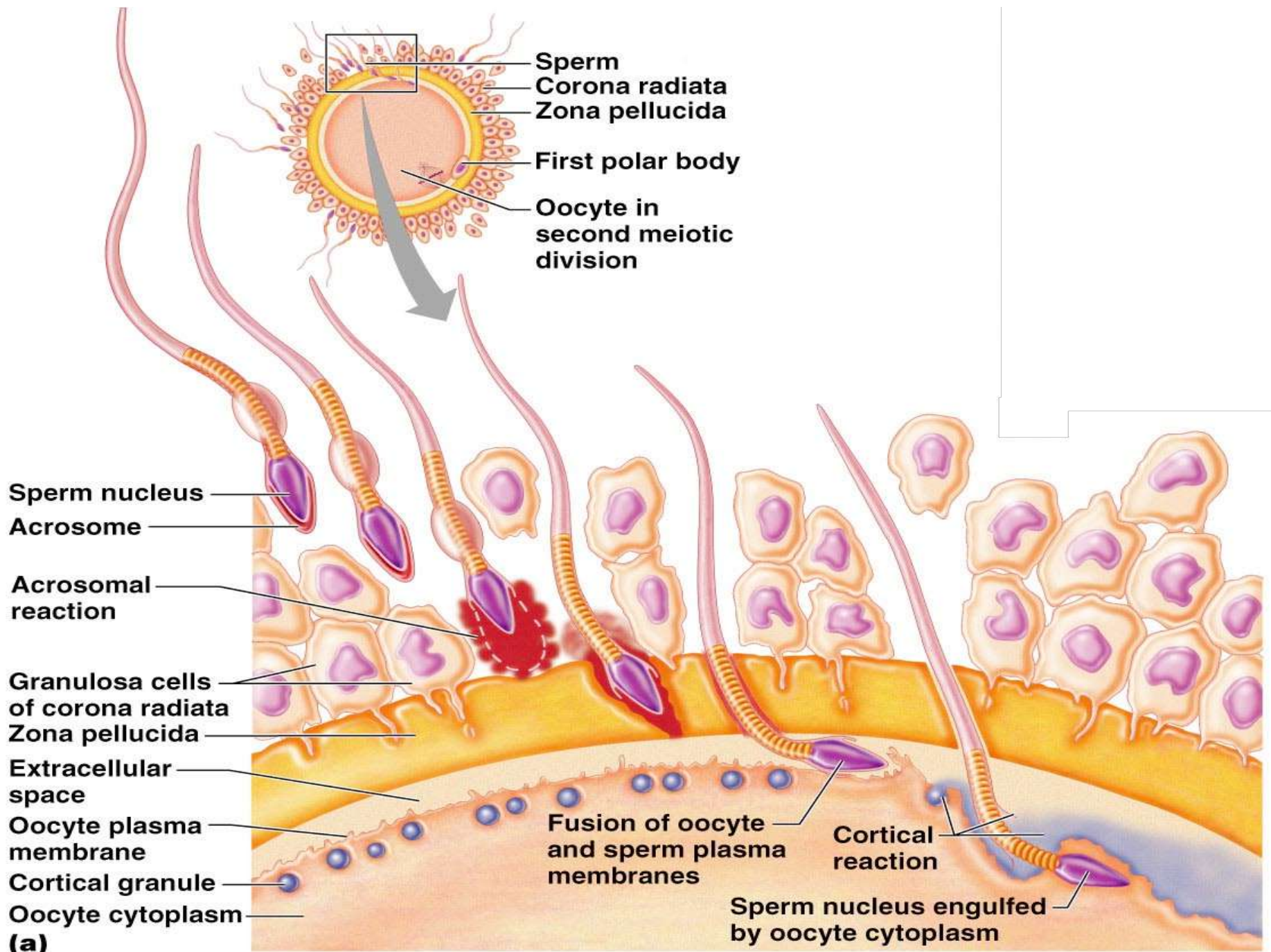


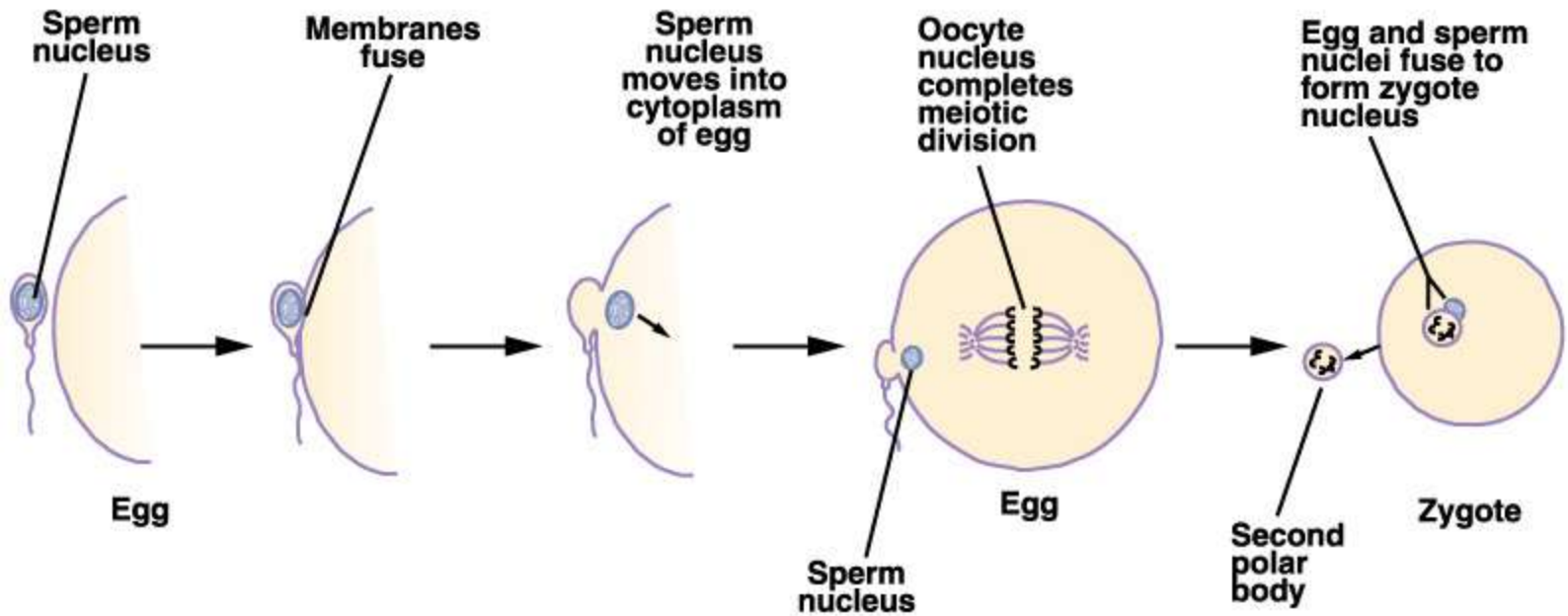
Late follicular phase and ovulation











Events Immediately Following Sperm Penetration

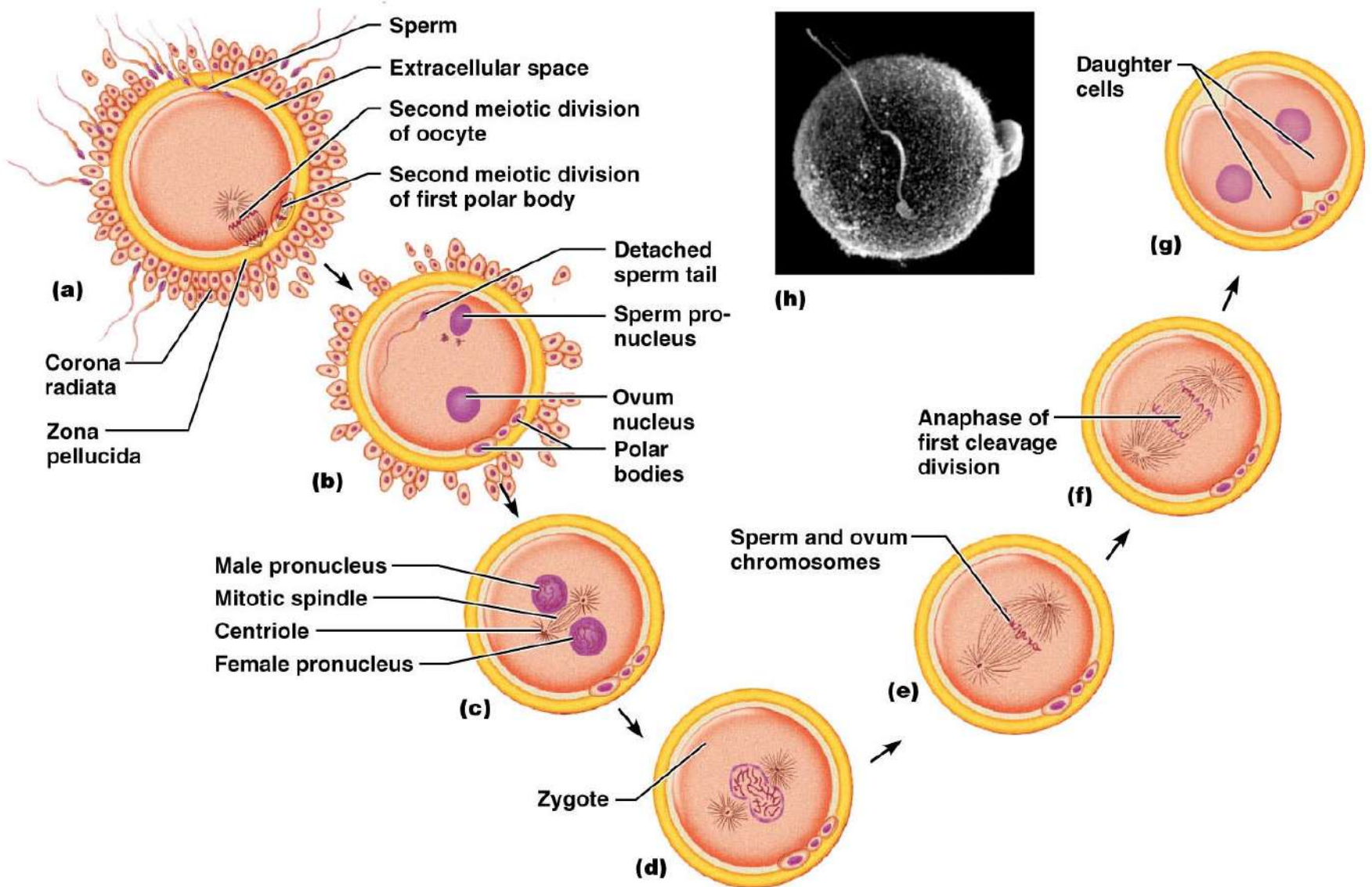
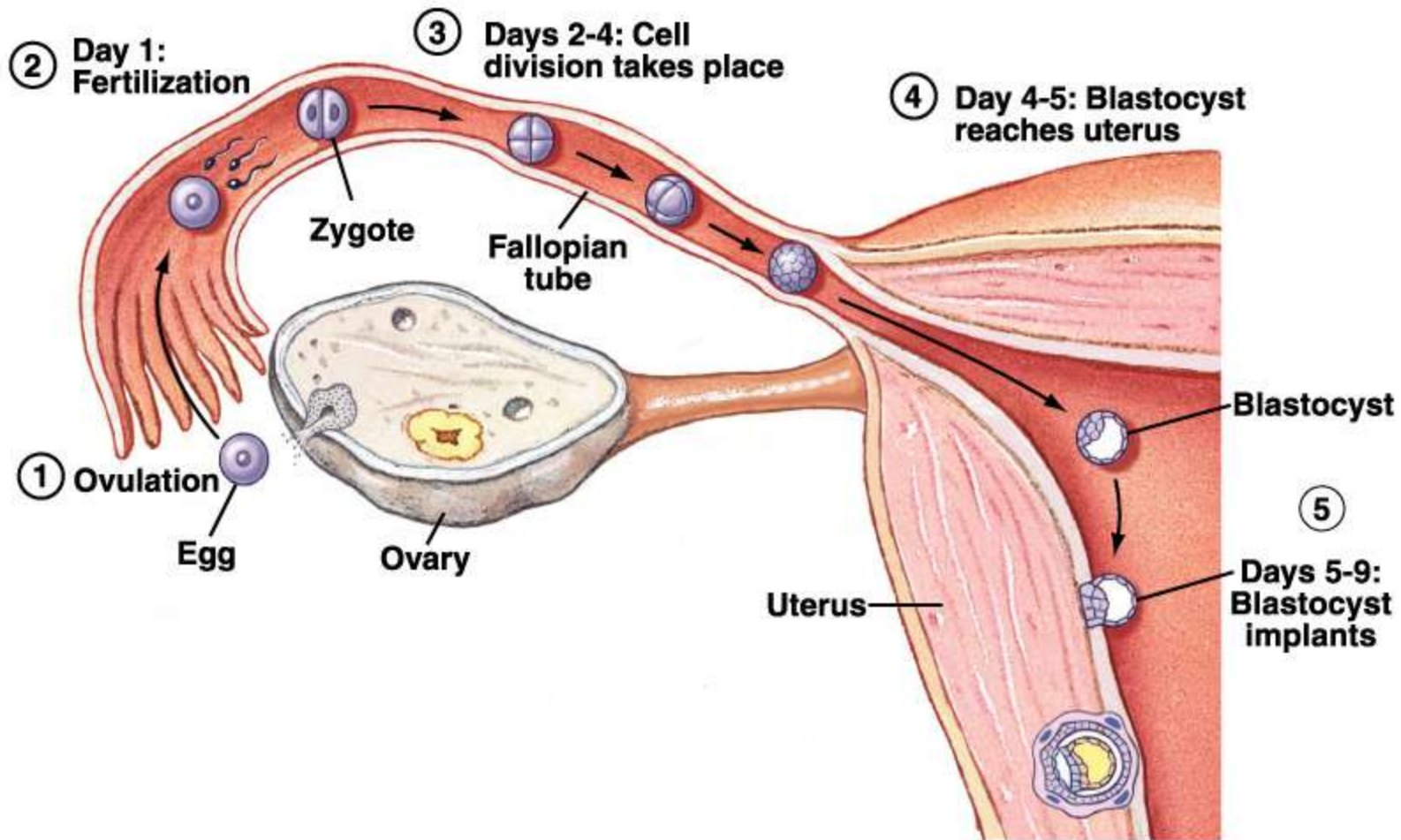
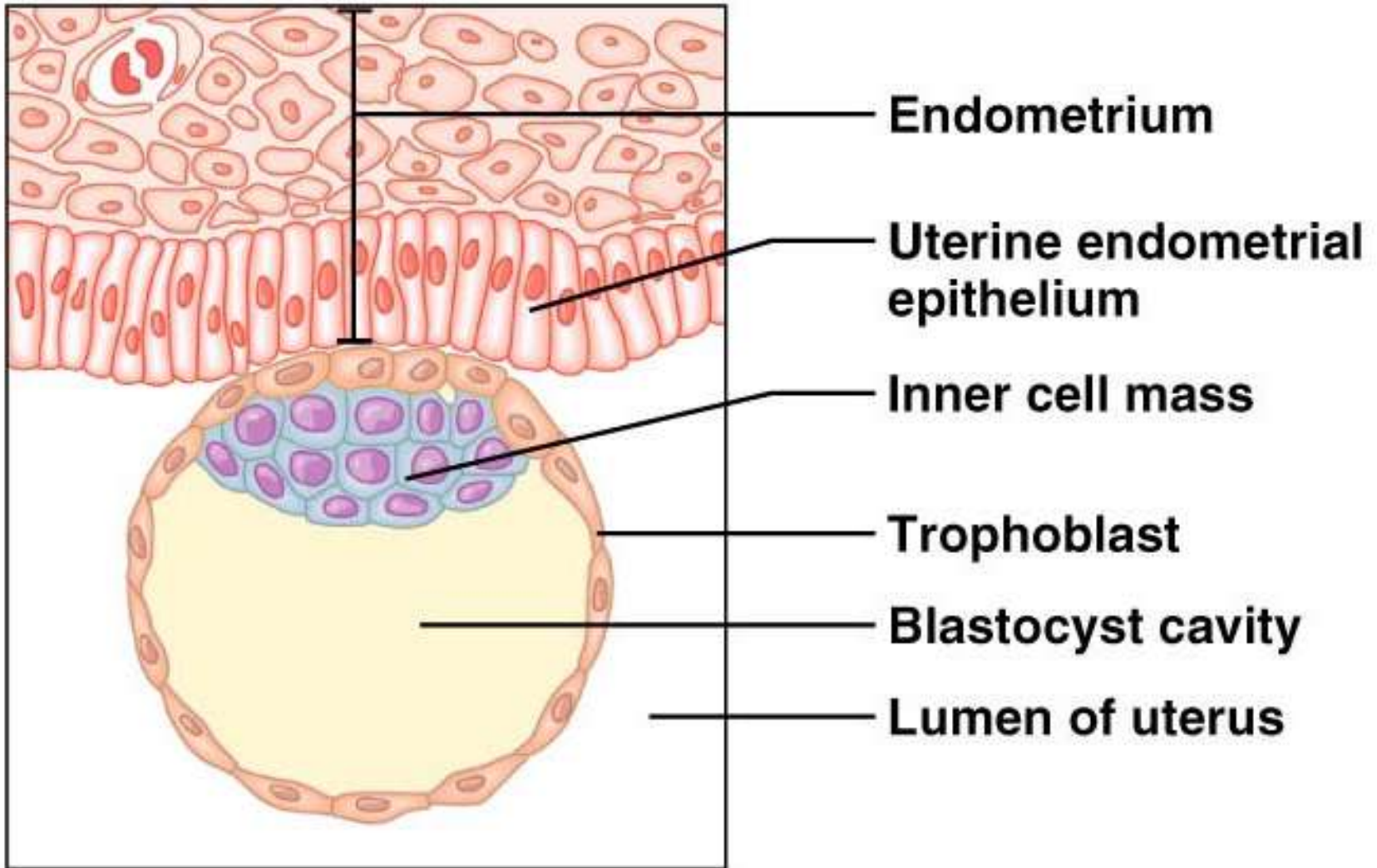


Figure 28.3

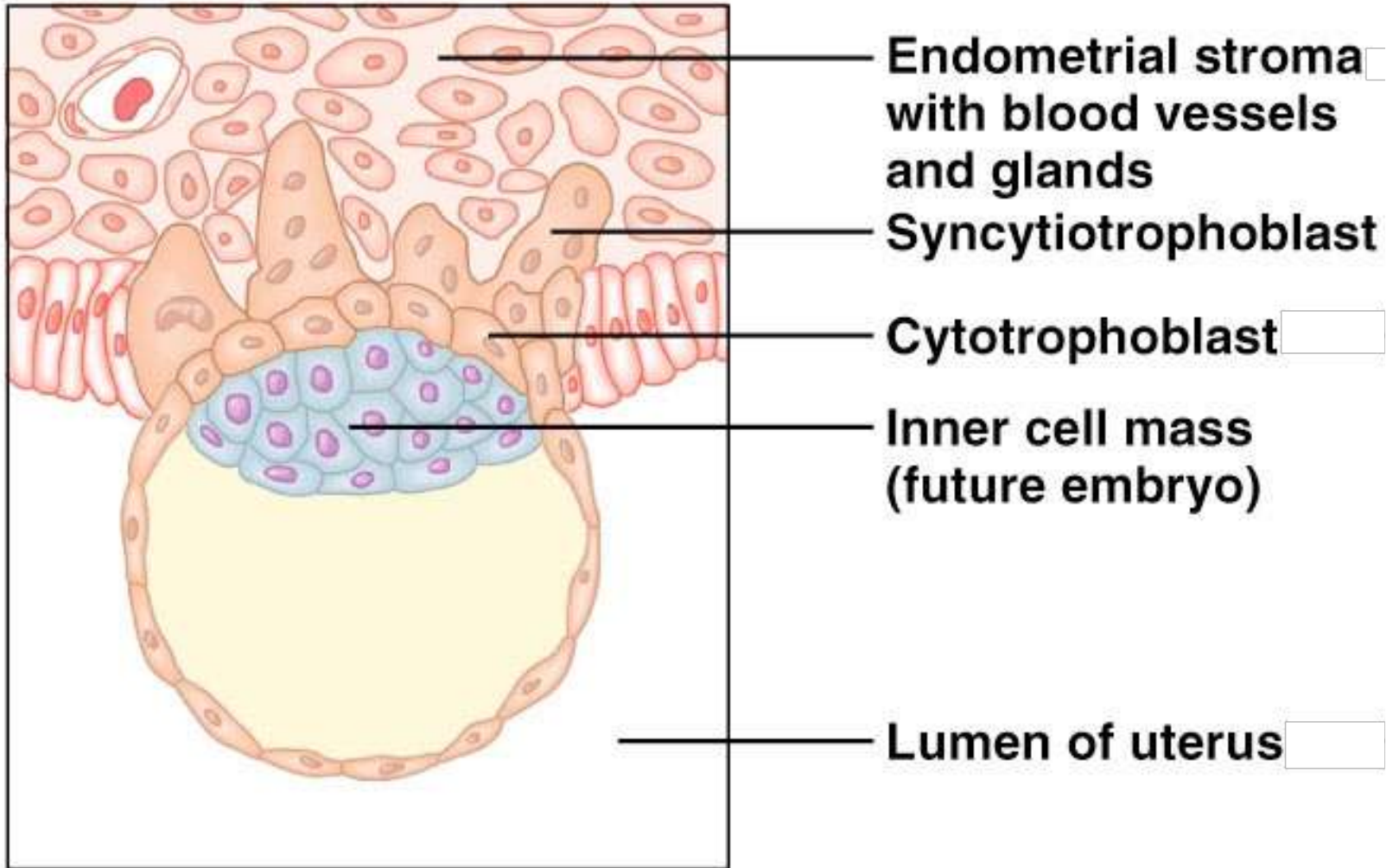


Implantation of the Blastocyst



(a)

Implantation of the Blastocyst



(b)

Hormonal Changes During Pregnancy

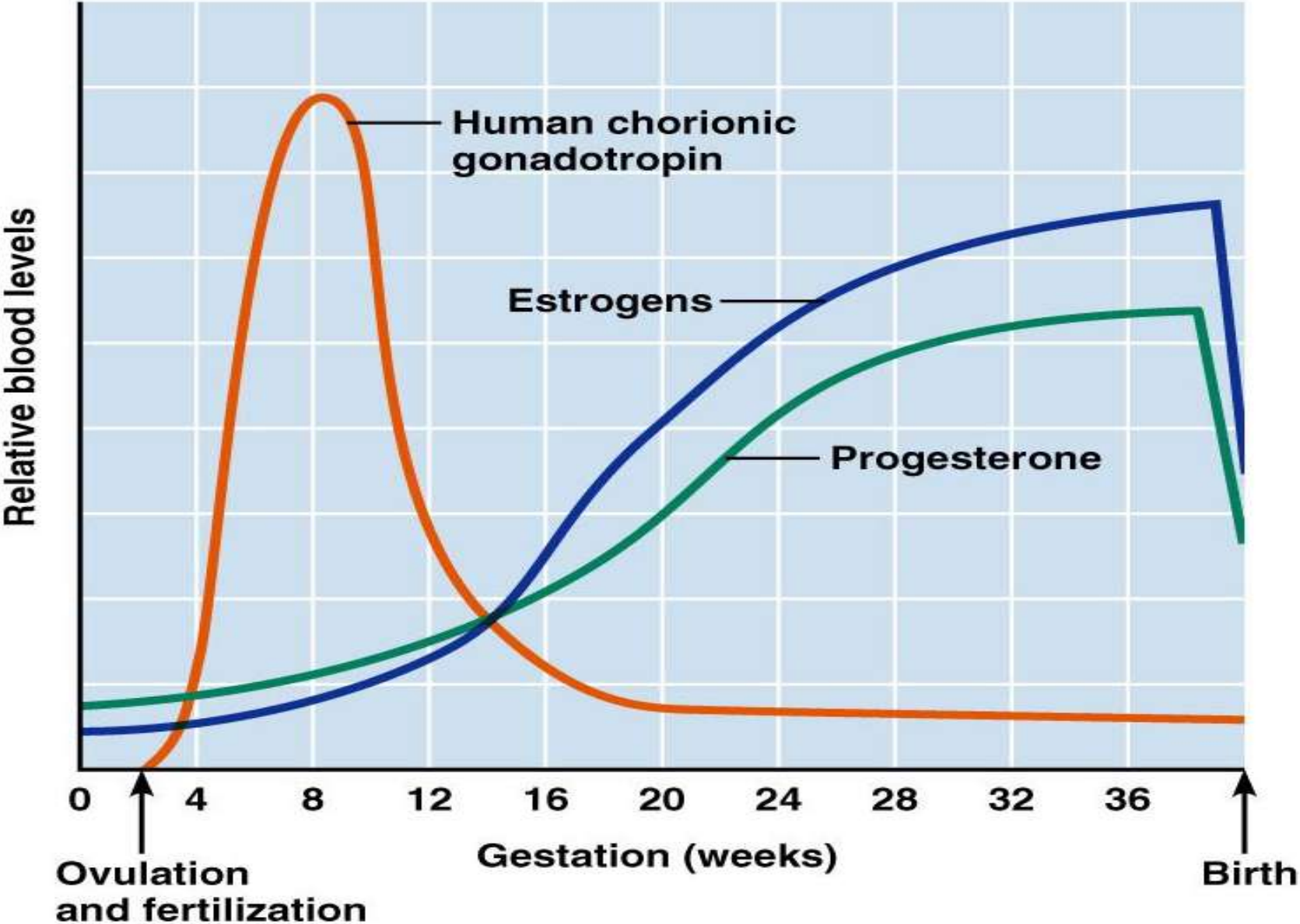
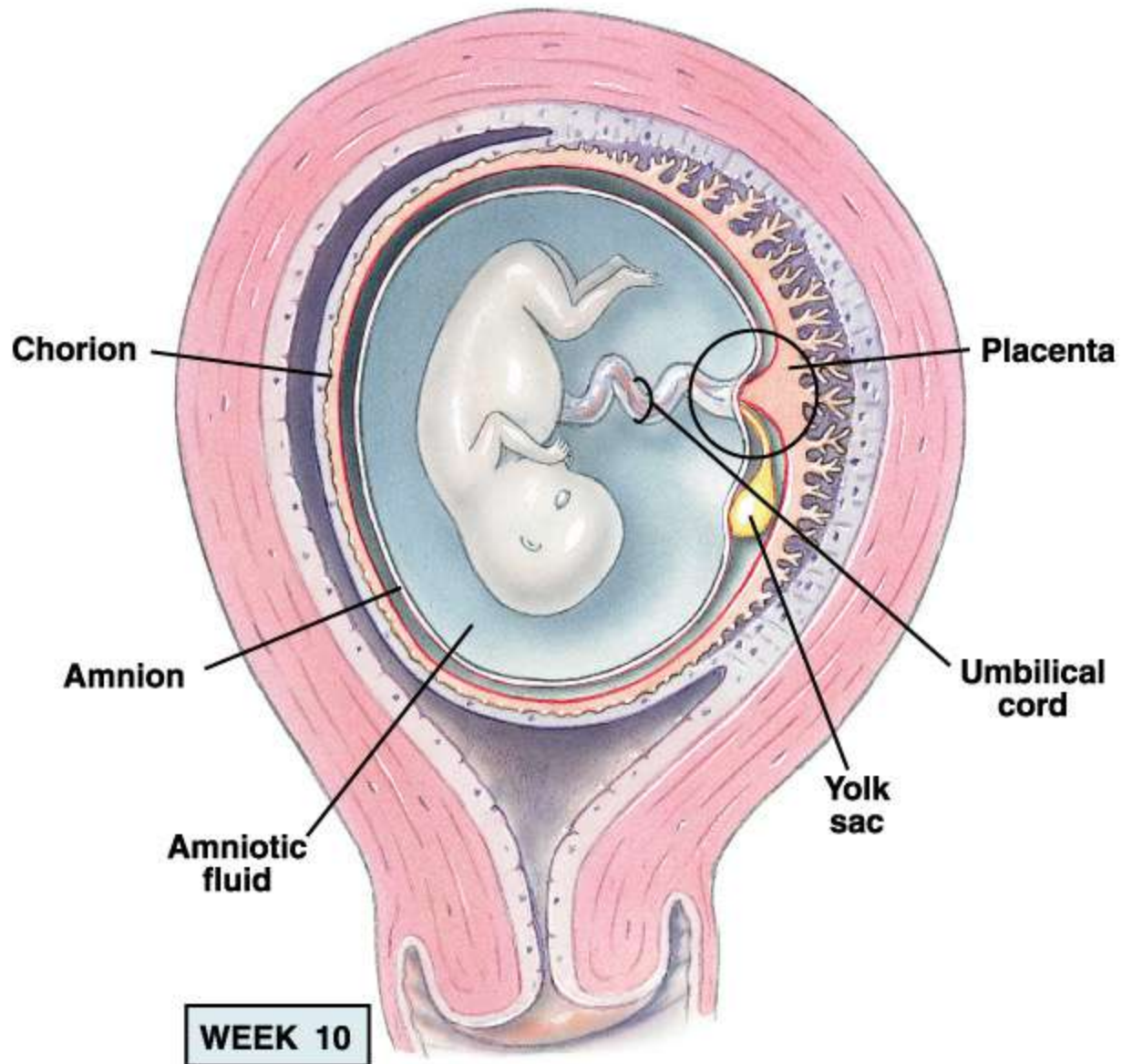
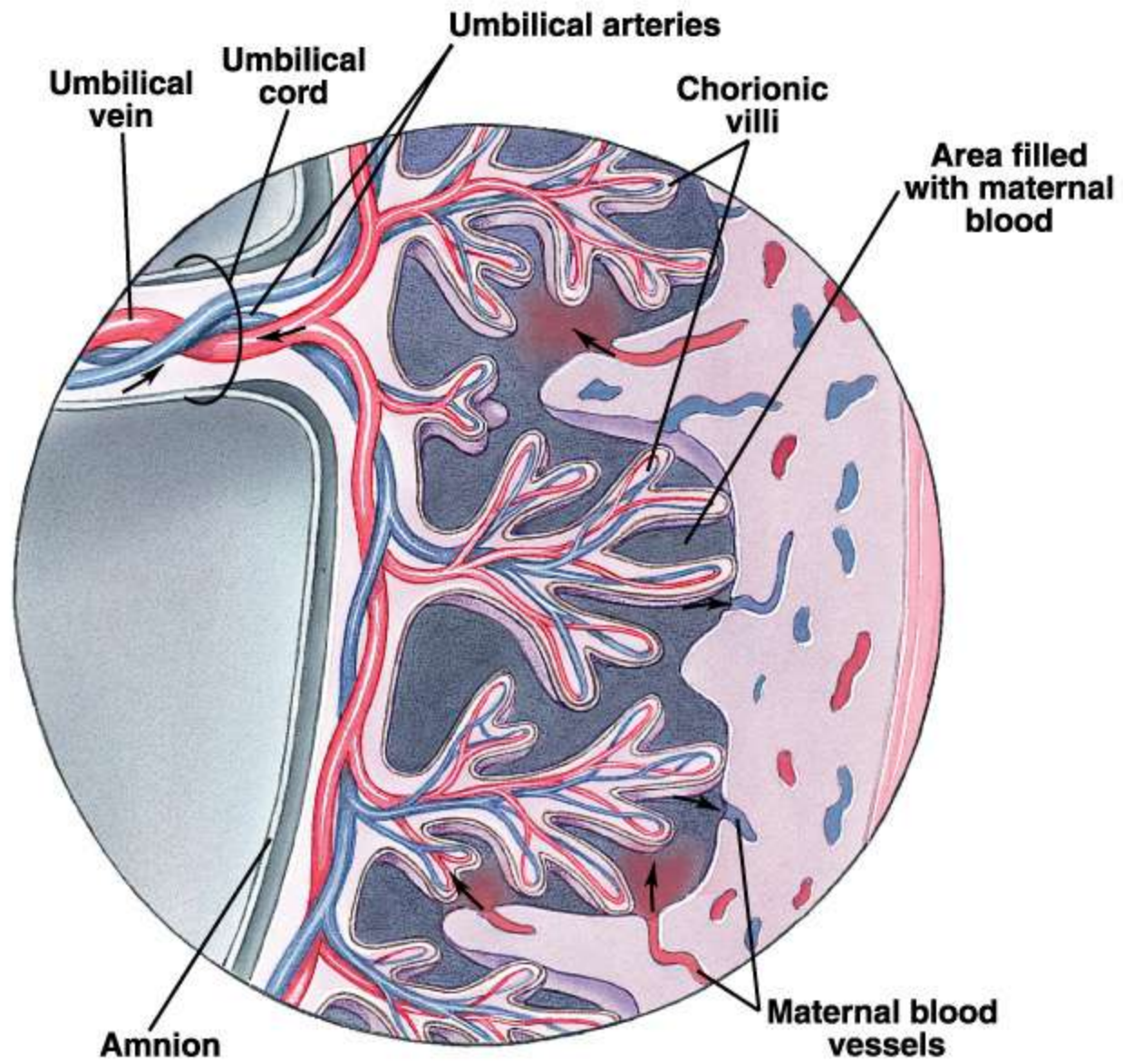
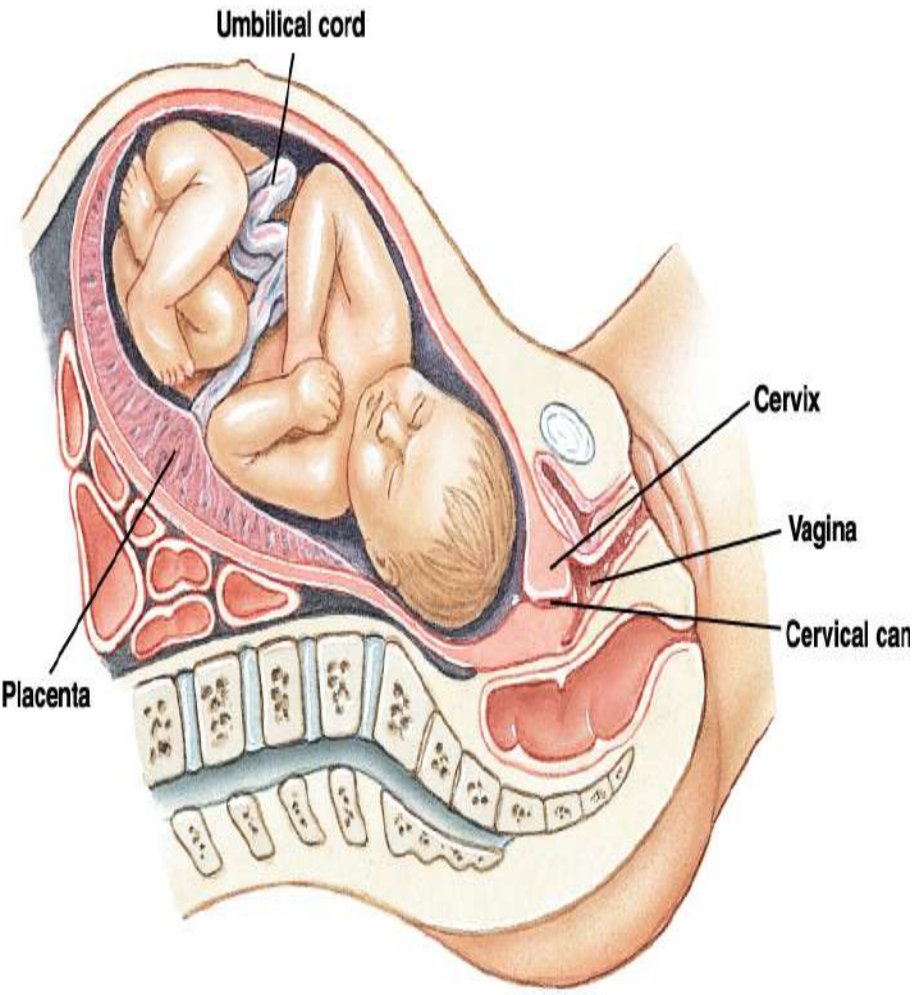


Figure 28.6

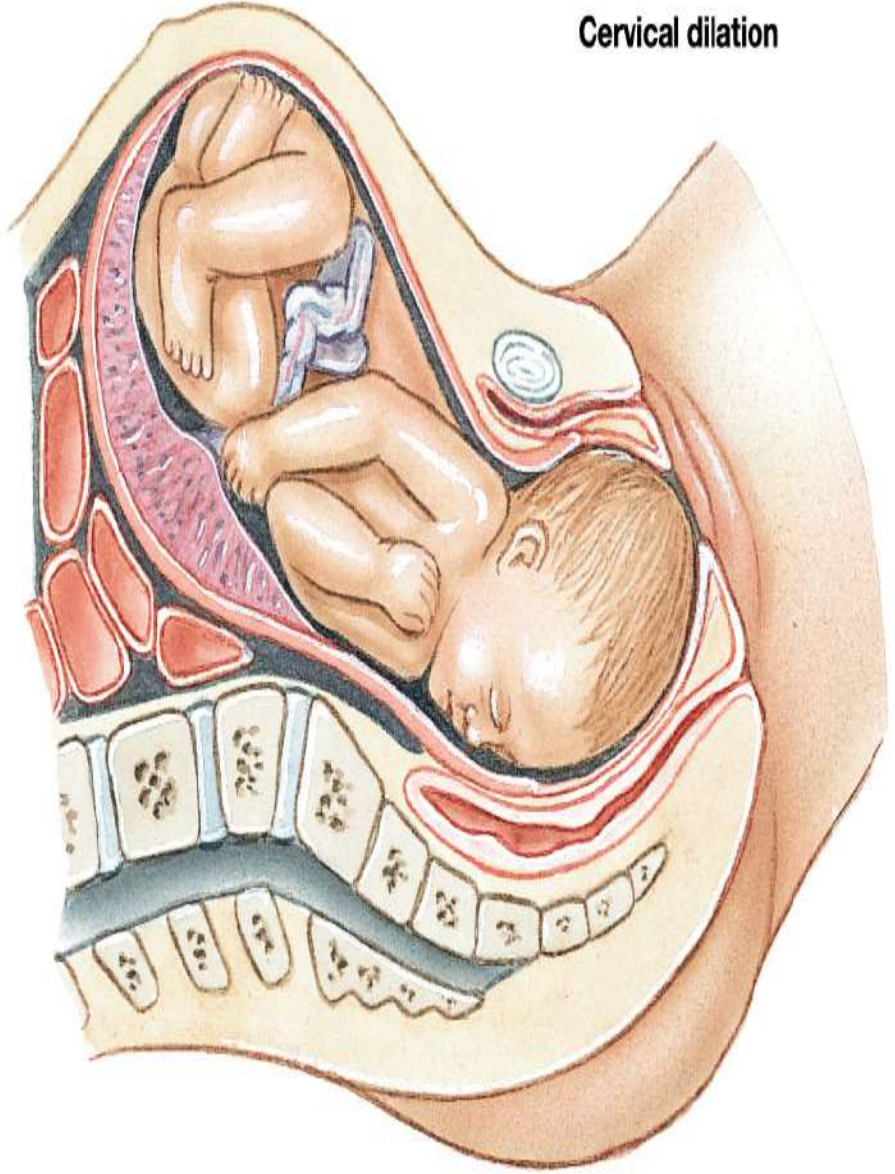




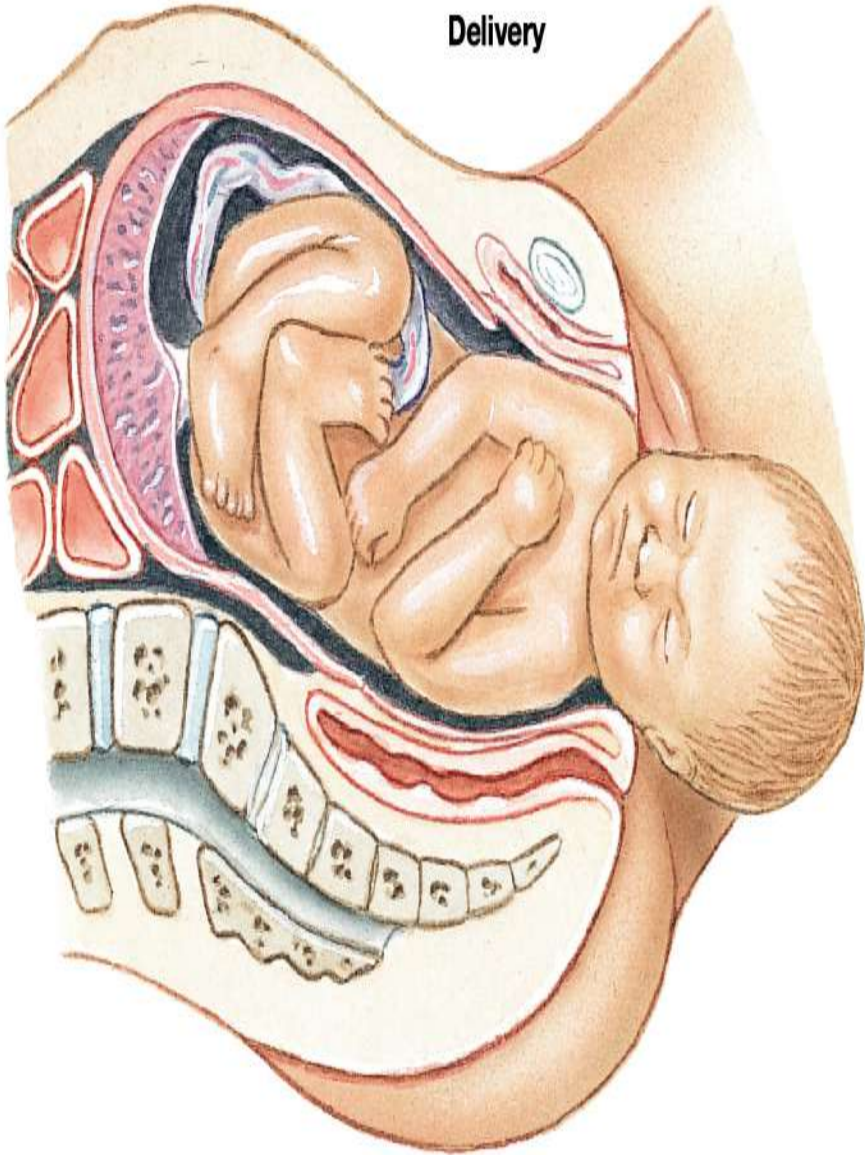
Fully developed fetus



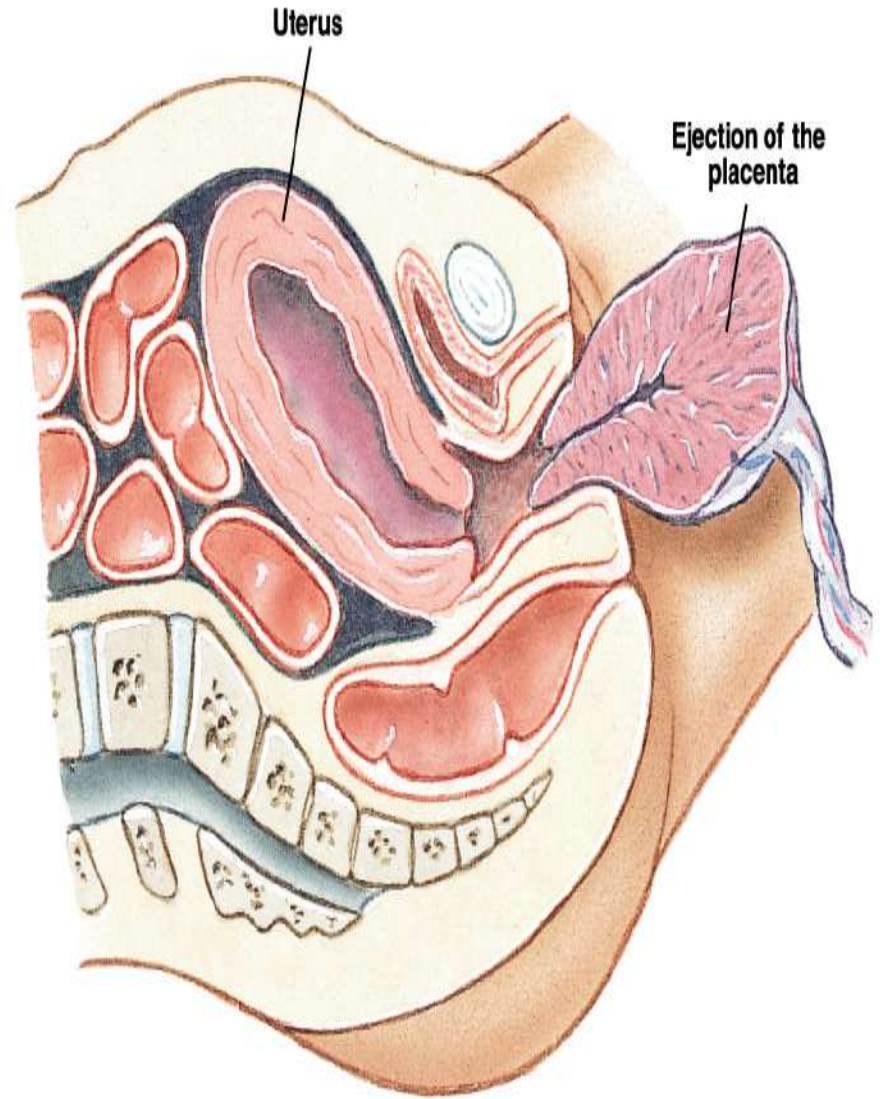
Cervical dilation

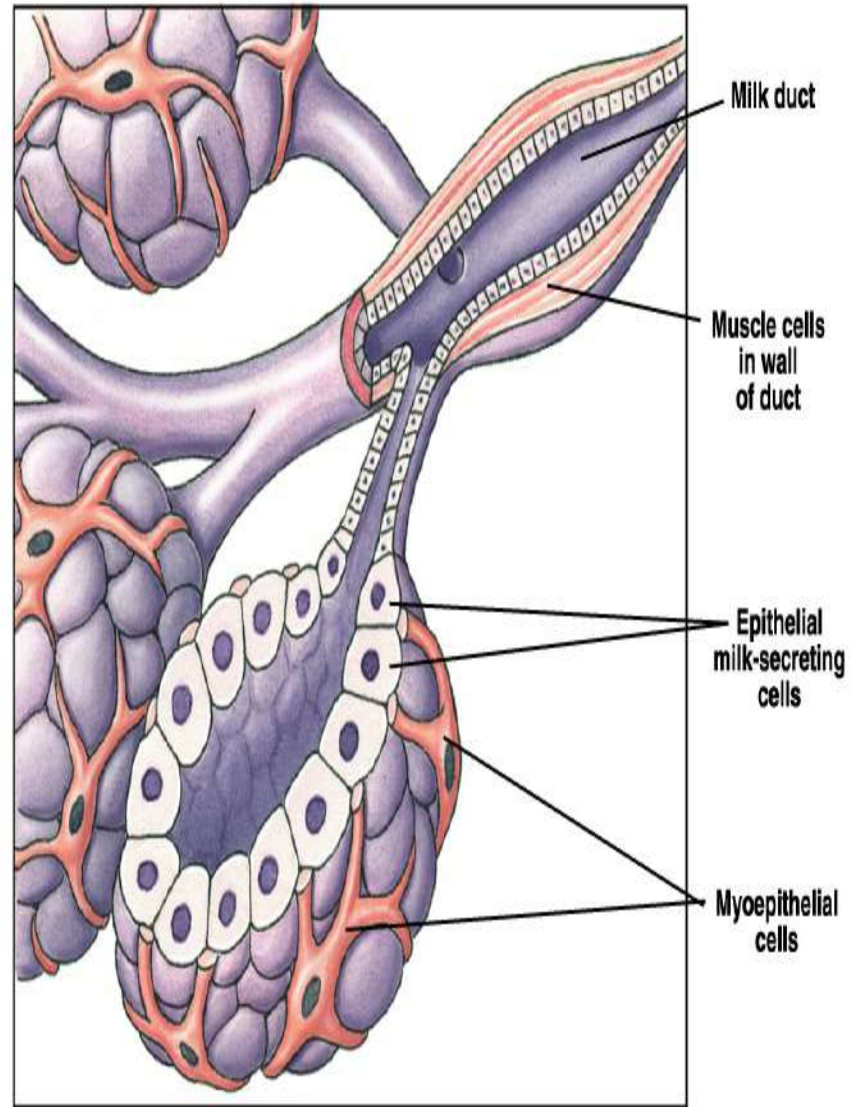
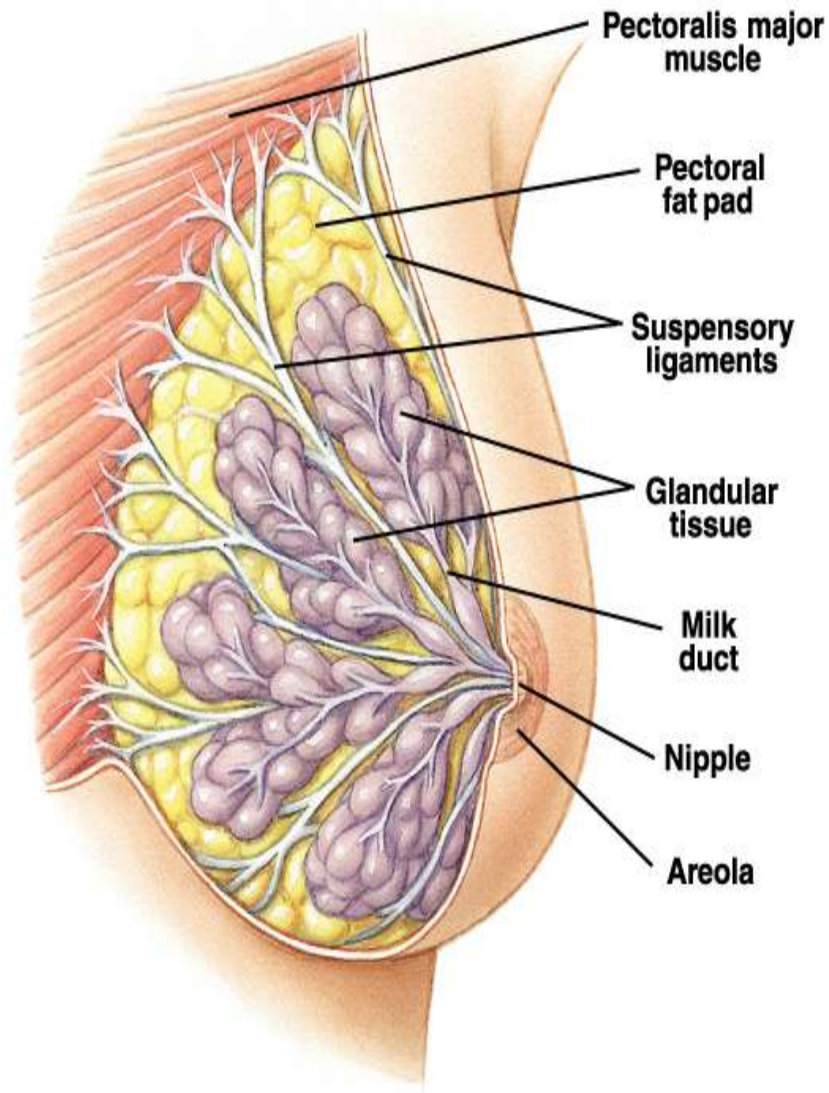


Delivery

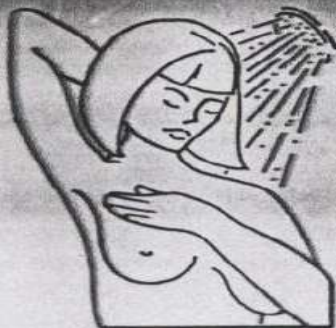

Expulsion of the placenta





1 In the bath or shower:



Examine your breasts during bath or shower. With flat fingers move gently over every part of each breast. Check for

lumps, hard knots, or thickenings.

2 Before a mirror:

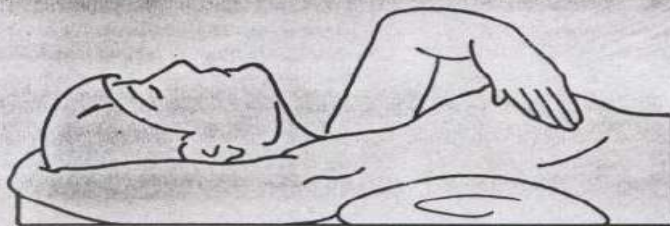Inspect your breasts with arms at your sides and then with your arms raised overhead. Look for any changes in each breast: a swelling, dimpling of skin or changes in the nipple.



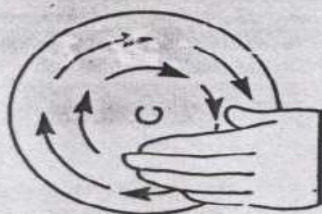Then, rest palms on hips and press down firmly to flex your chest muscles. Regular inspection shows what is

normal for you and will give you confidence in your examination.

3 Lying down:



To examine your right breast, put a pillow or folded towel under your right shoulder. Place right hand behind your head - this distributes breast tissue more evenly on the chest. With left hand, fingers flat,



press gently in small circular motions around an imaginary clock face. A ridge of firm tissue in the lower curve of

each breast is normal. Then move in an inch, toward the nipple, keep circling to examine every part of your breast, including nipple. Now slowly repeat procedure on your left breast.

Squeeze the nipple of each breast gently between thumb and index finger. Any discharge, clear or bloody, should be reported to your doctor immediately.

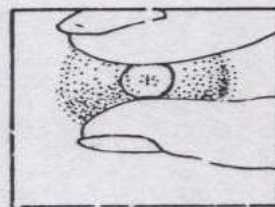
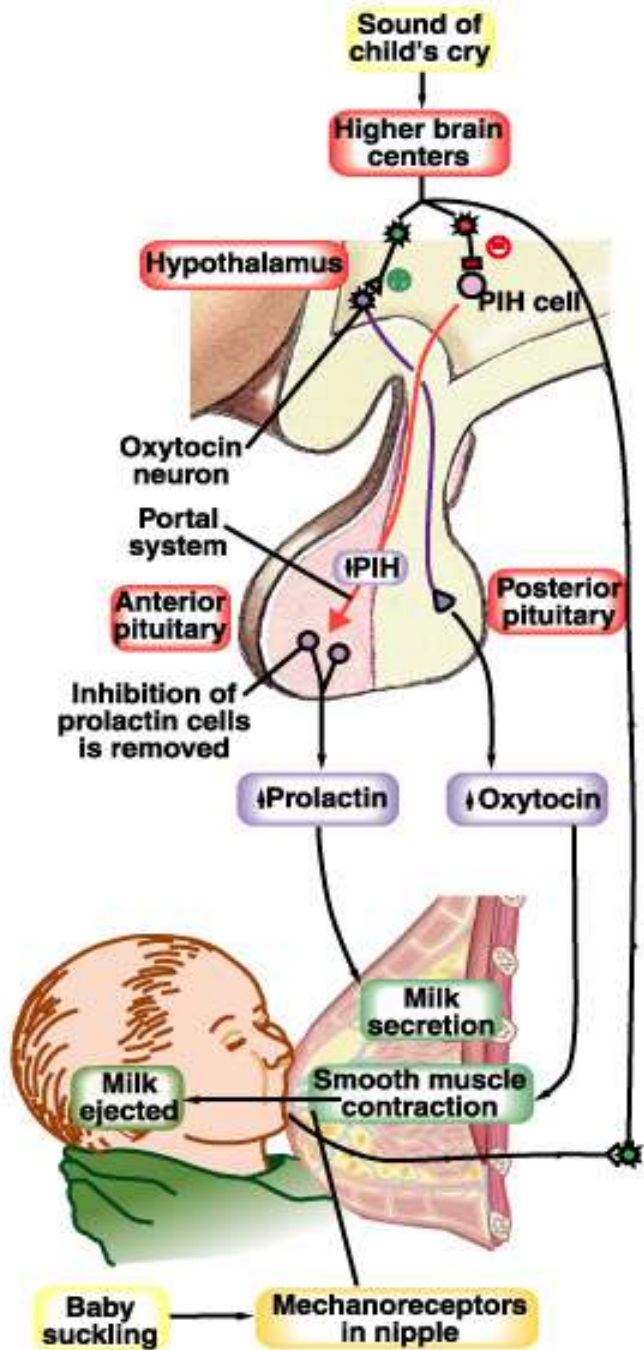


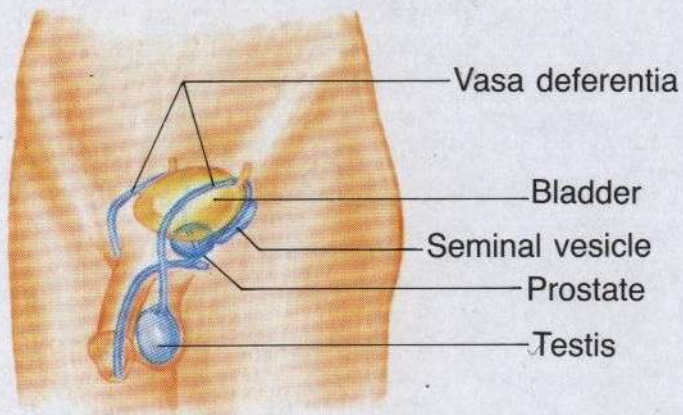
Figure 2-16 How to examine your breasts as a method to detect abnormal lumps and other changes.



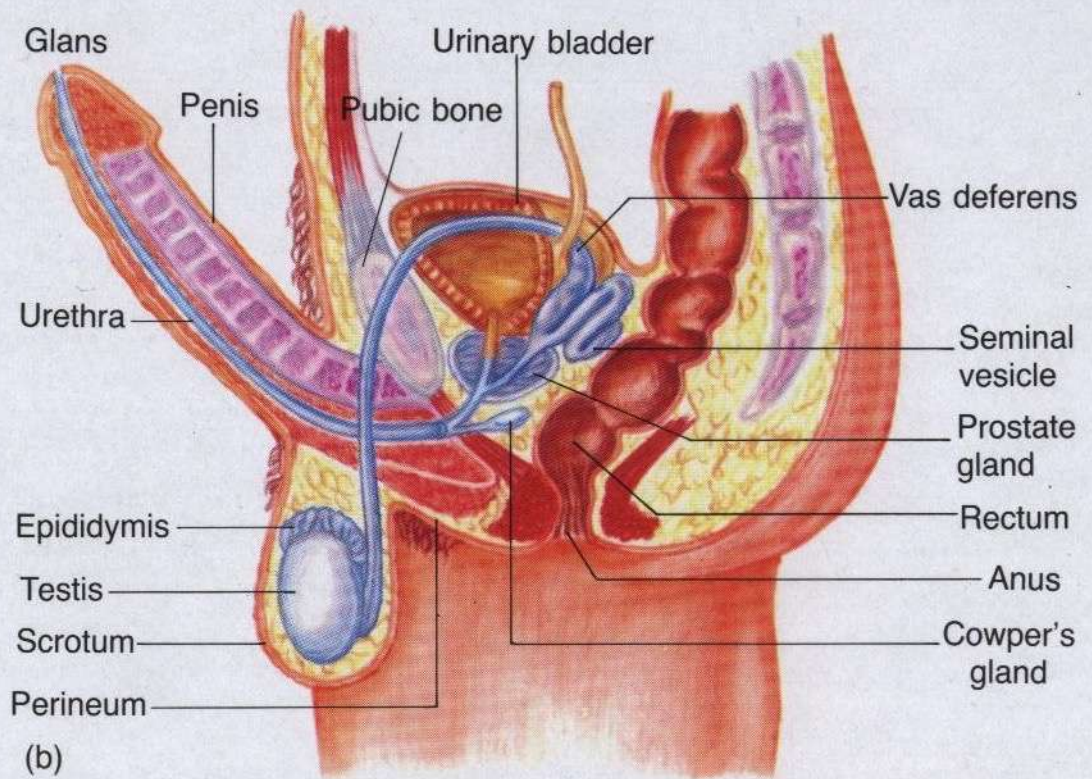
URINARY COMPONENTS



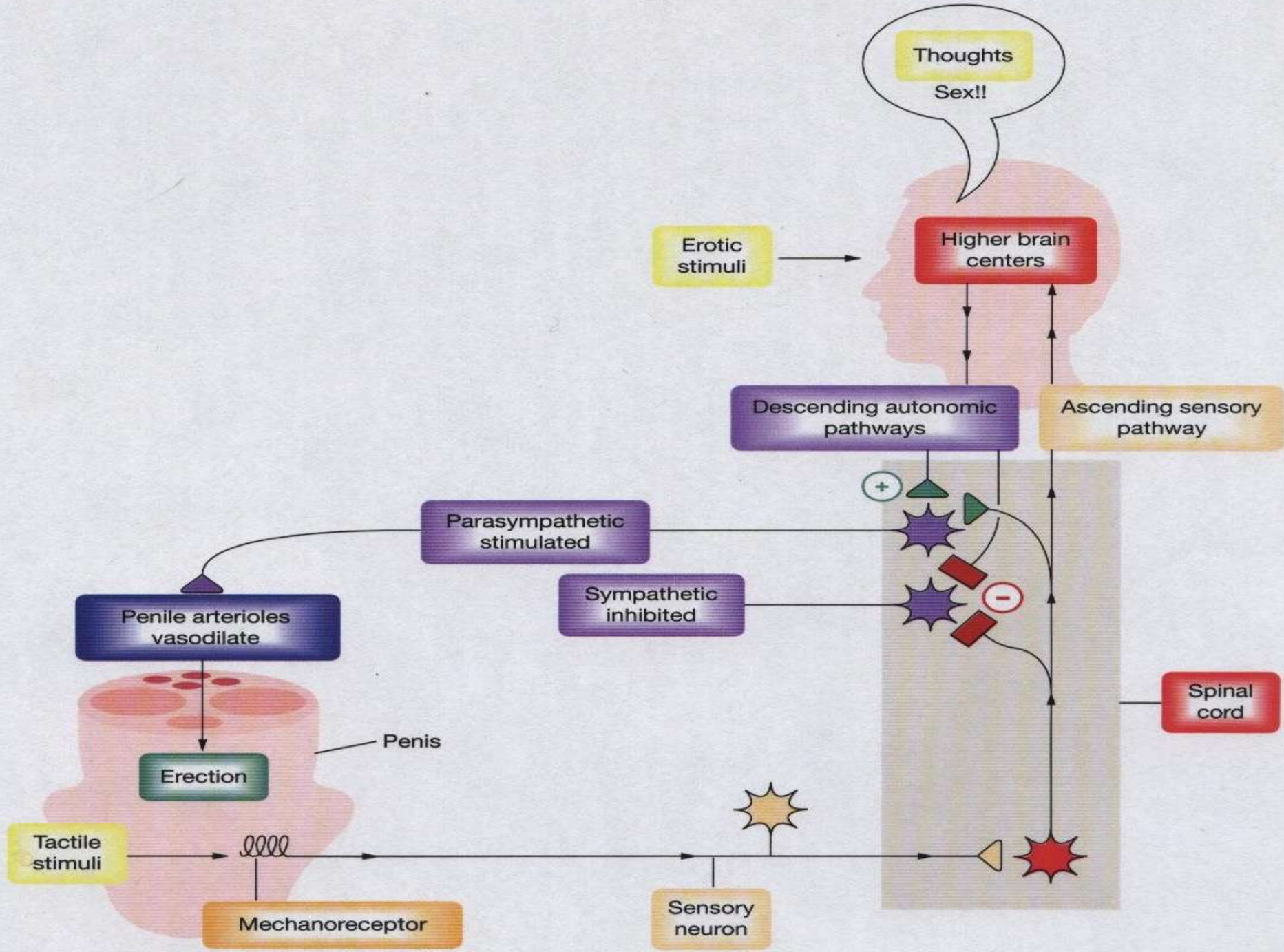
GENITAL COMPONENTS



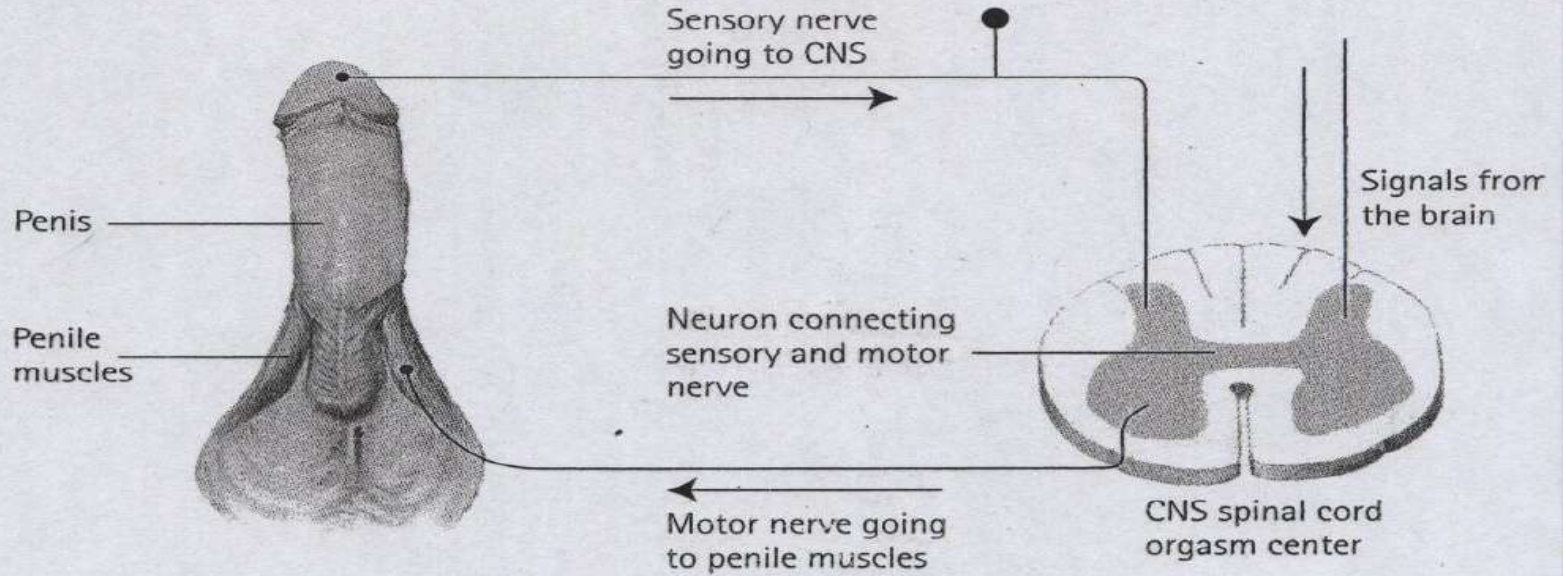
(a)



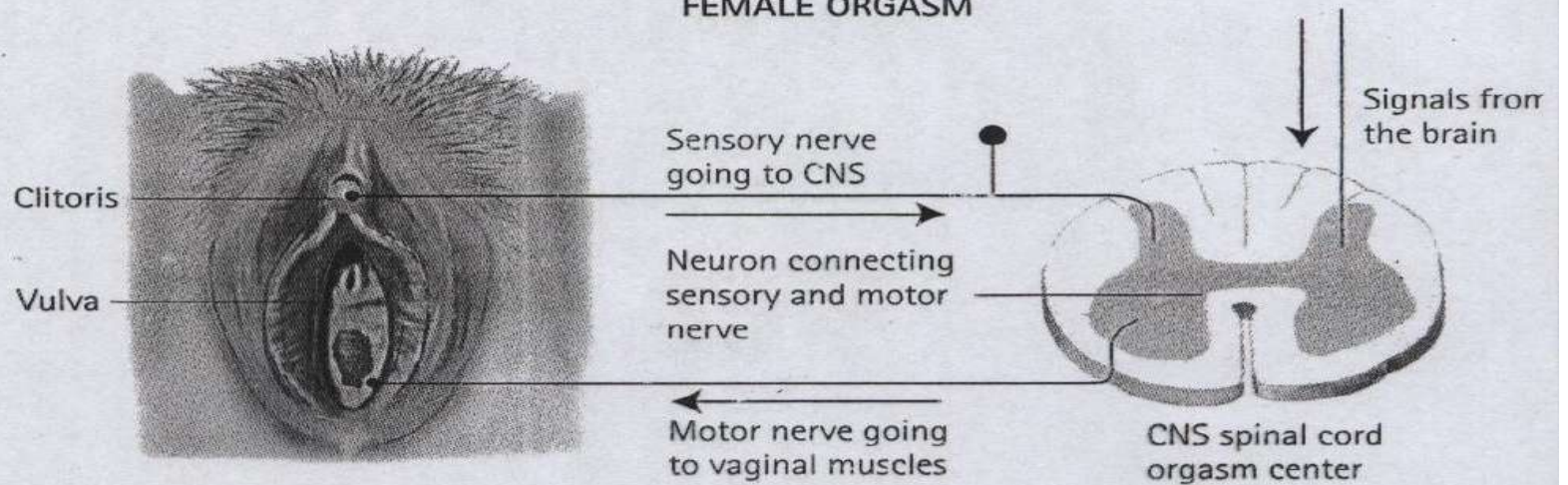
(b)

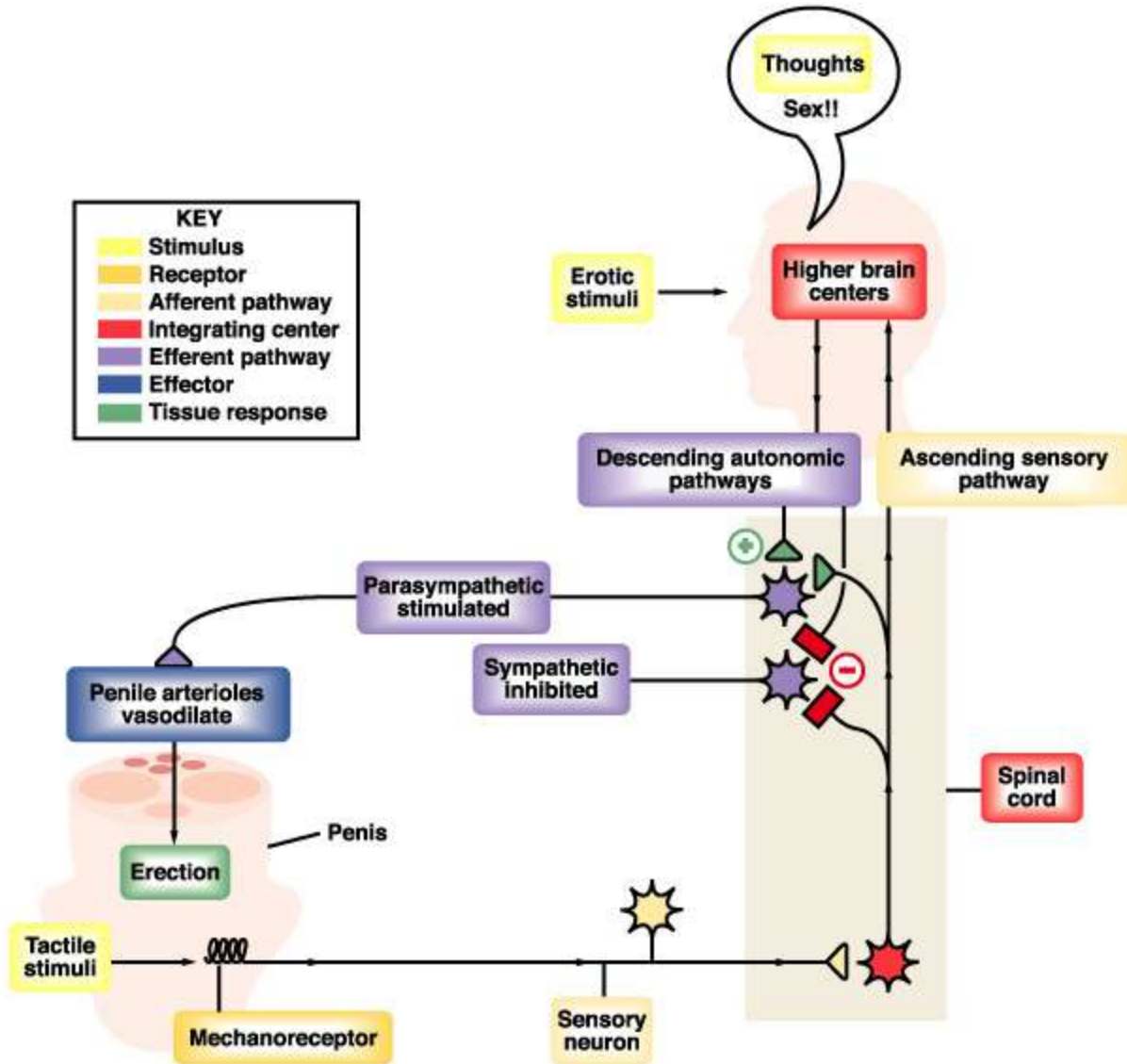


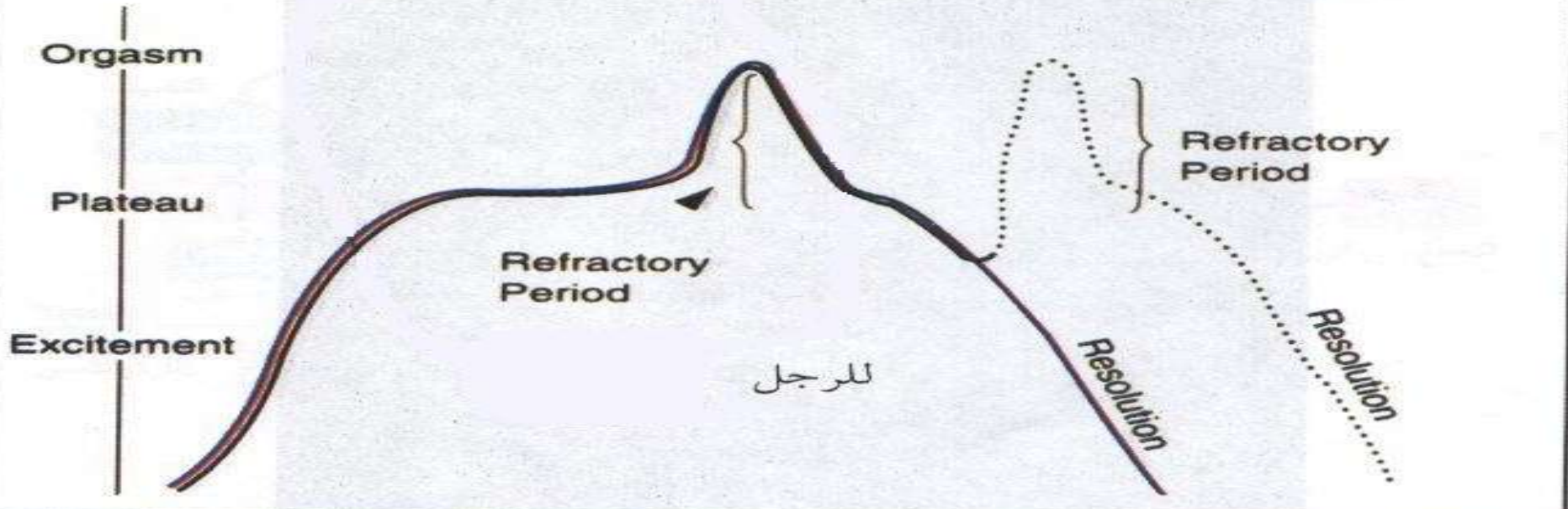
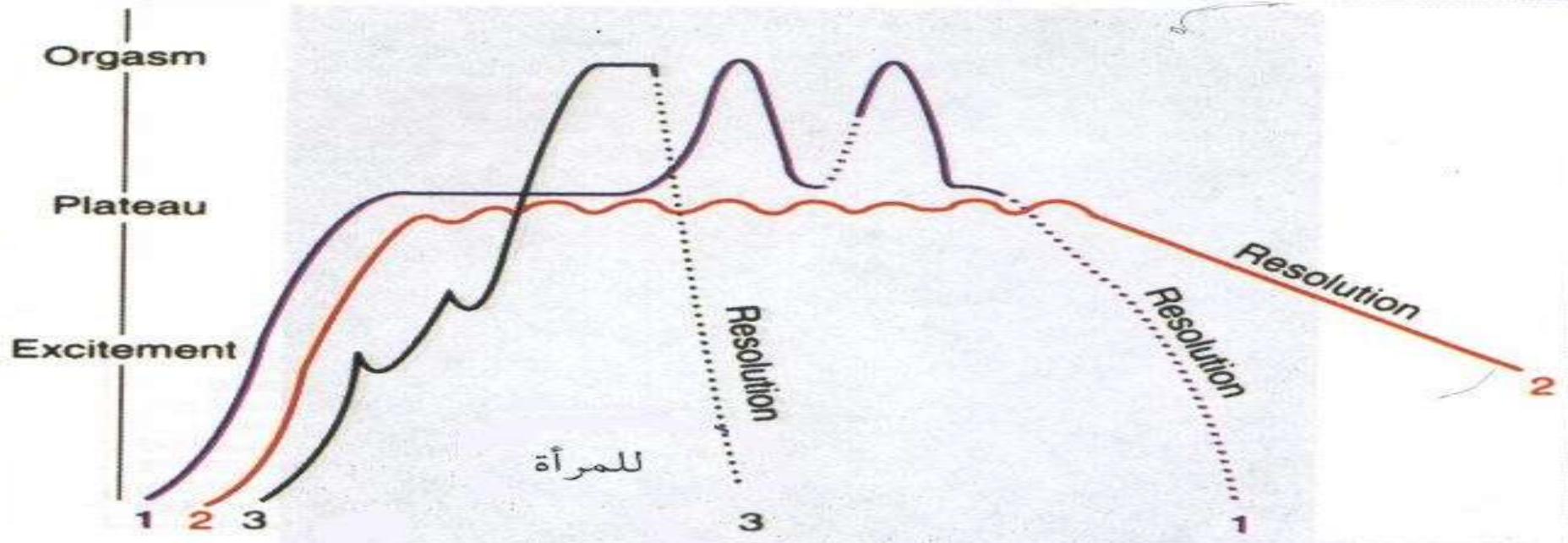
MALE ORGASM

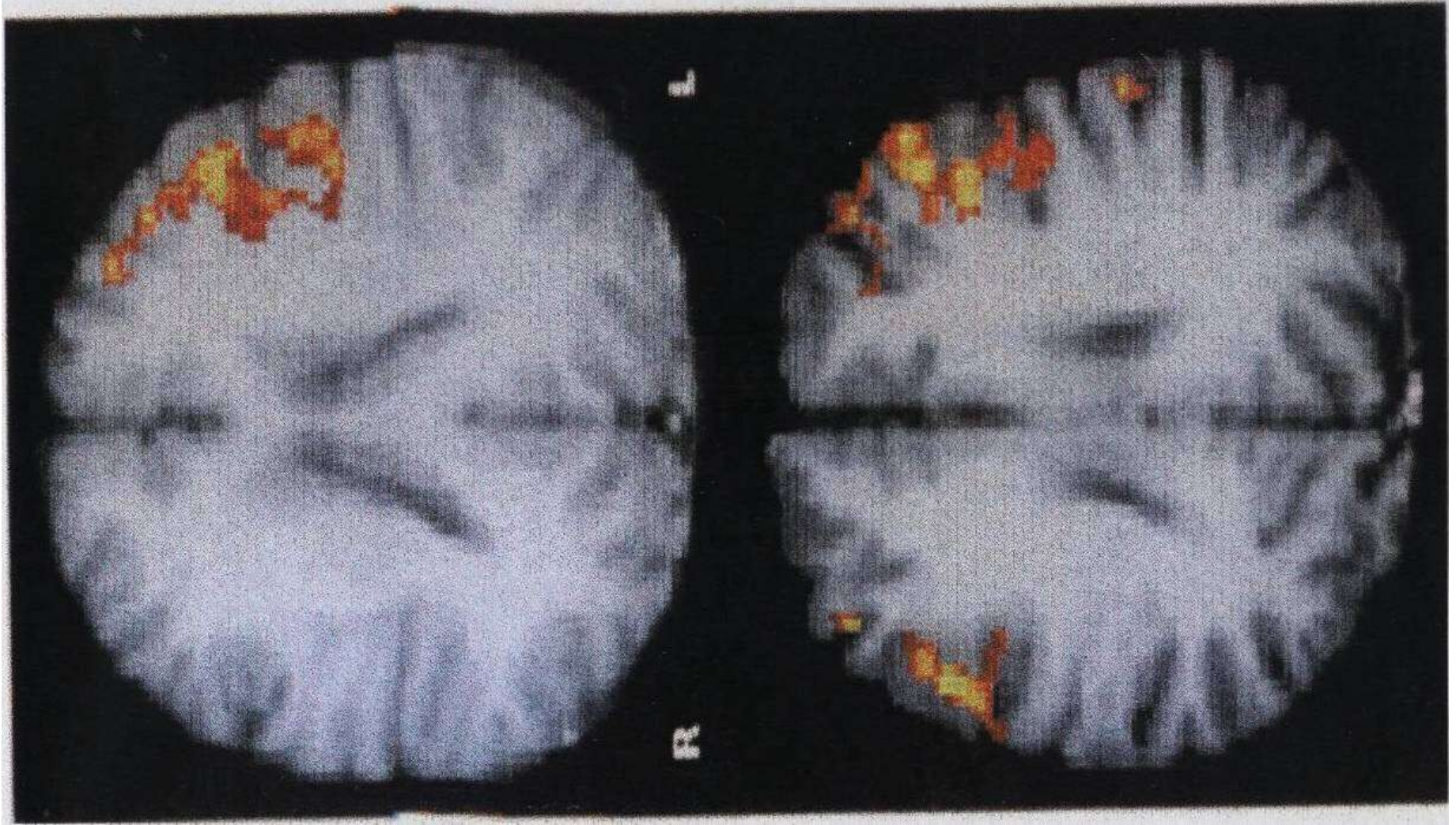


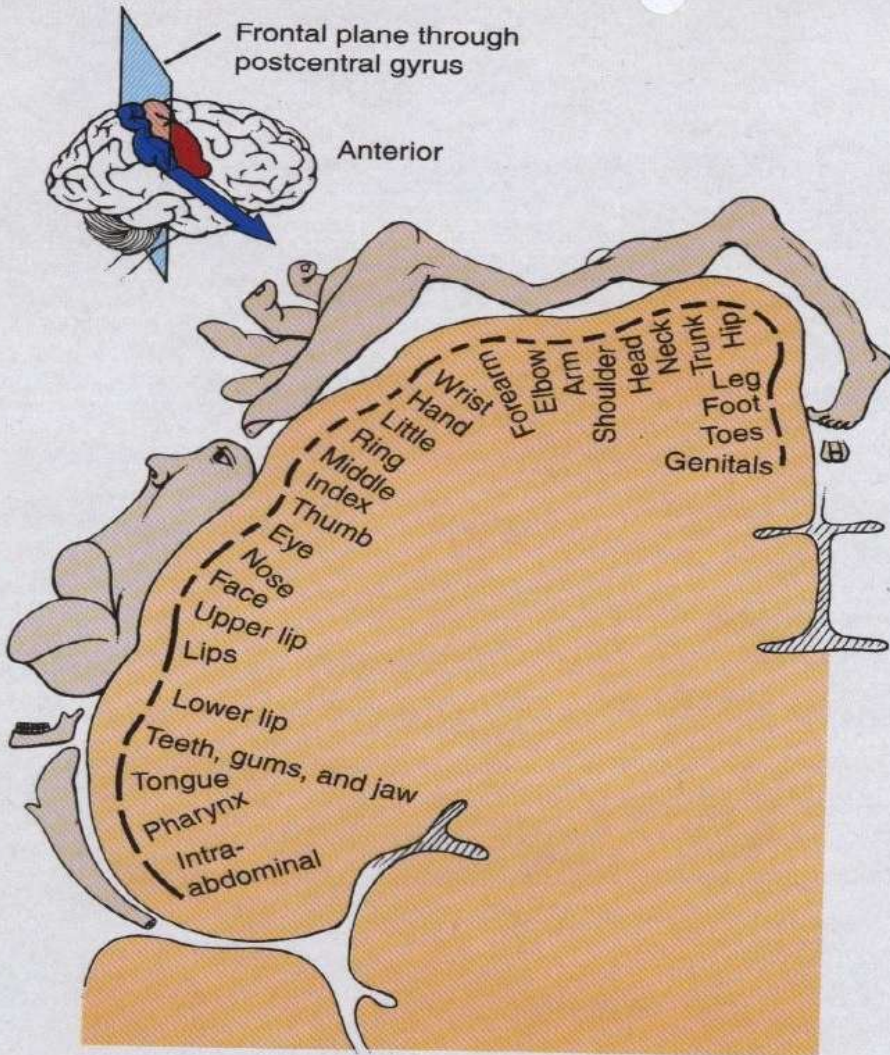
FEMALE ORGASM



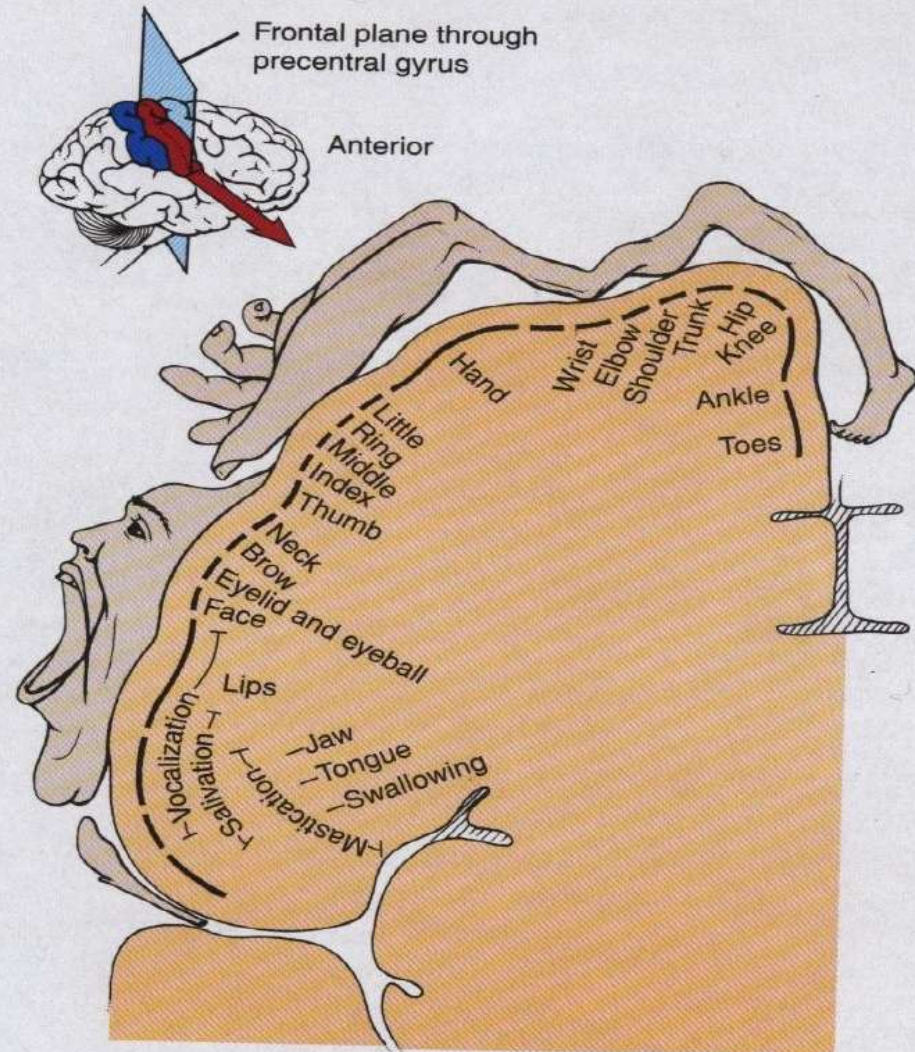








(a) Frontal section of primary somatosensory area in right cerebral hemisphere



(b) Frontal section of primary motor area in right cerebral hemisphere