

Dysphagia

HANEEN KIRREH, M.A. SPEECH THERAPY AND AUDIOLOGY (HADASSAH)

SWALLOWING DISORDERS

SPAU 430



Eating Competition

<https://www.youtube.com/watch?v=nKDDAKdgQTM>

Swallowing in general:

- It is occurred about 2000 times a day.
- This procedure requires the coordination between 26 muscles and 5 cranial nerves:

➤ V

➤ VII

➤ IX

➤ X

➤ XII

Breathing plays an important role in swallowing.

Normal swallowing

- Food preparation and mastication requires saliva

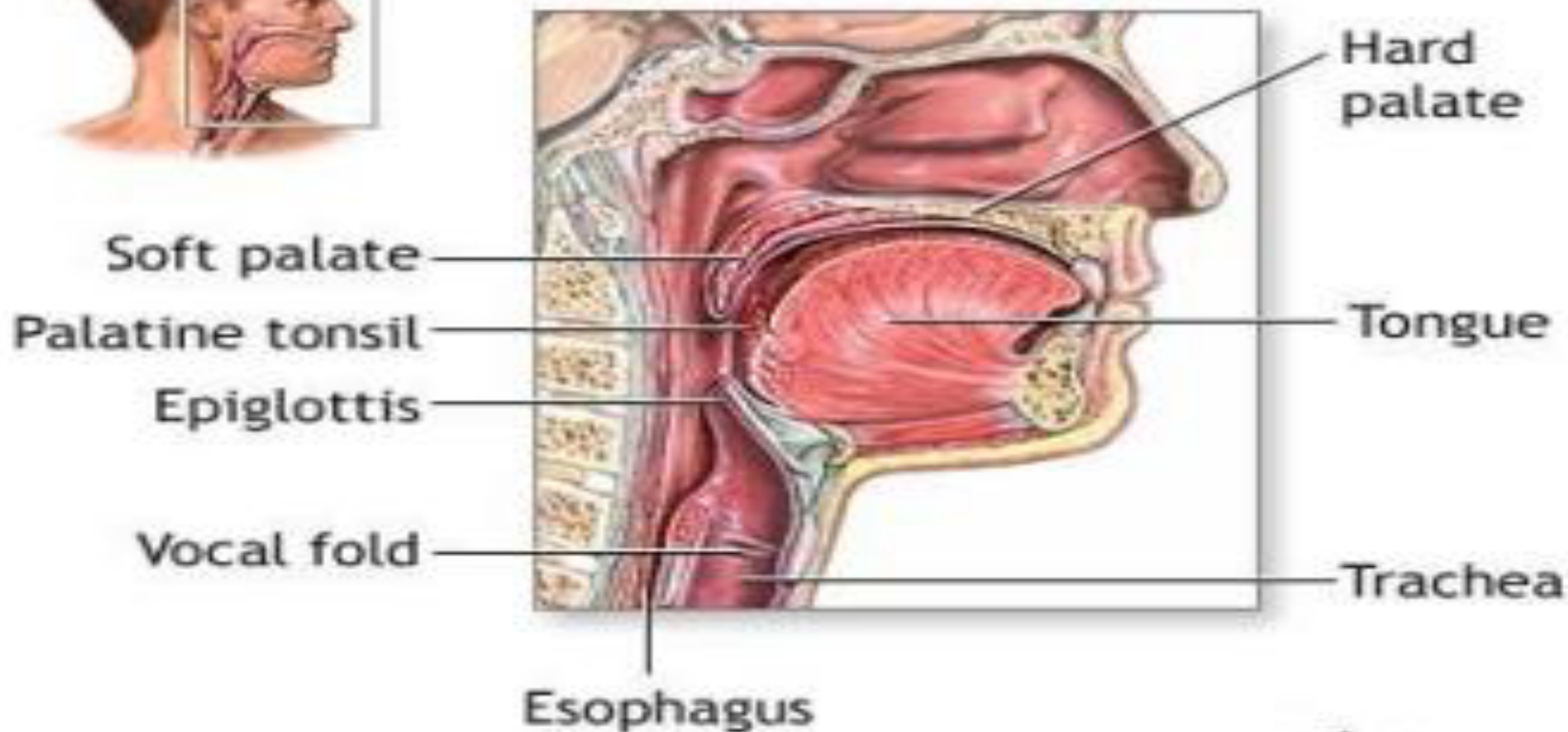
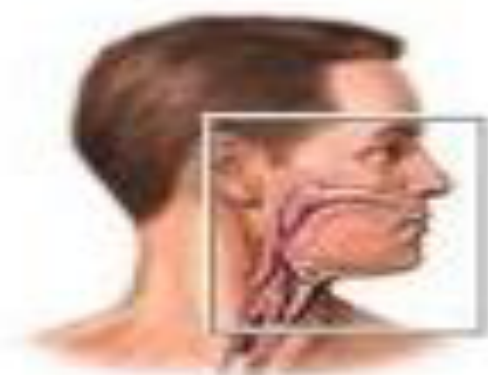Saliva from 3 pairs of salivary glands:

1. **Parotid gland**
2. **Submandibular gland**
3. **Sublingual gland**

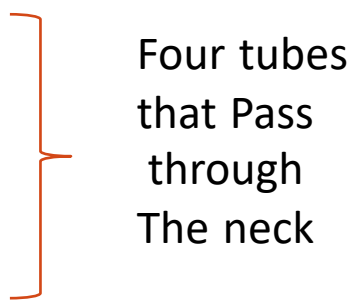
Saliva

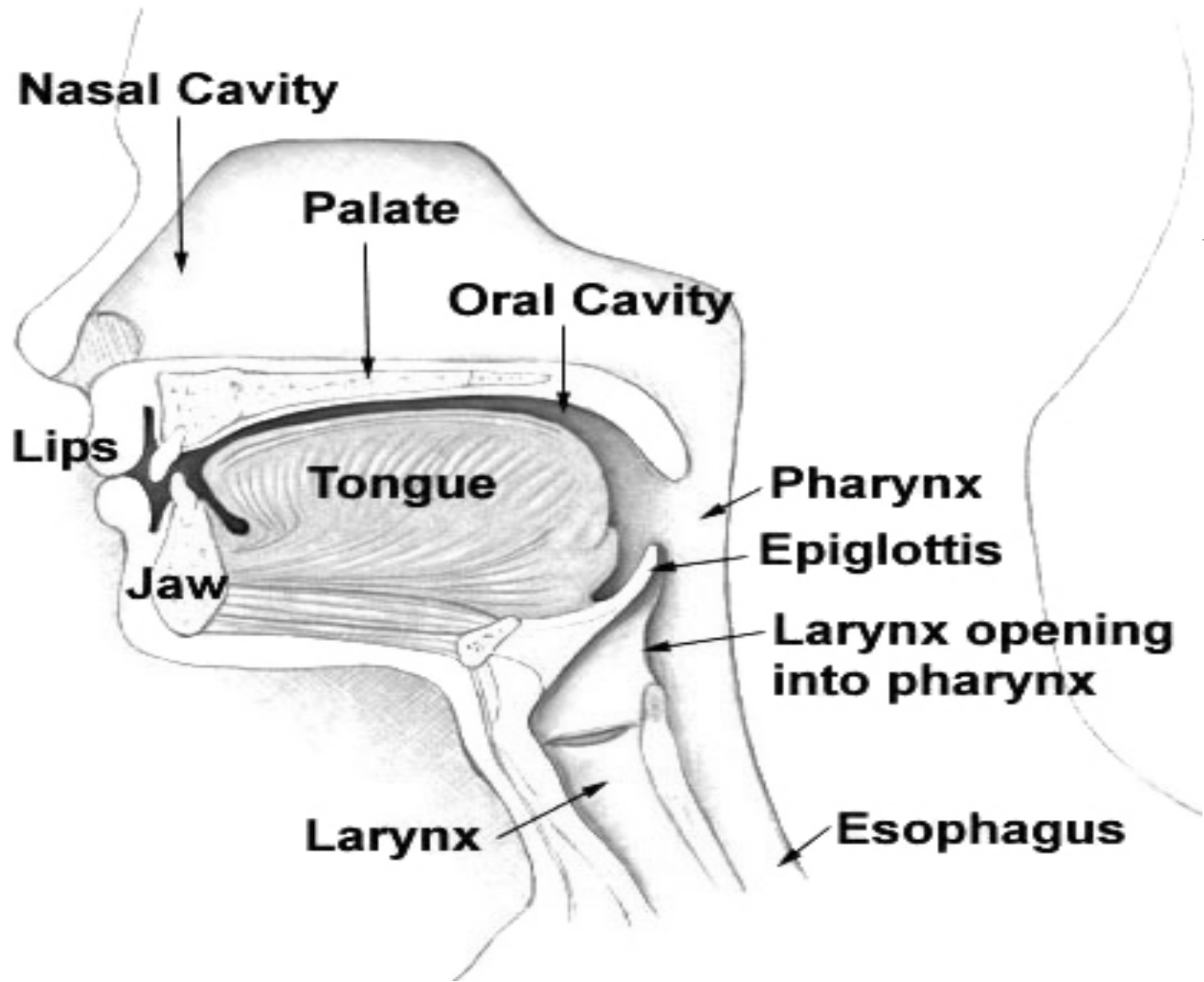
- Contains anti-infectious bacteria
- Provides minerals for teeth

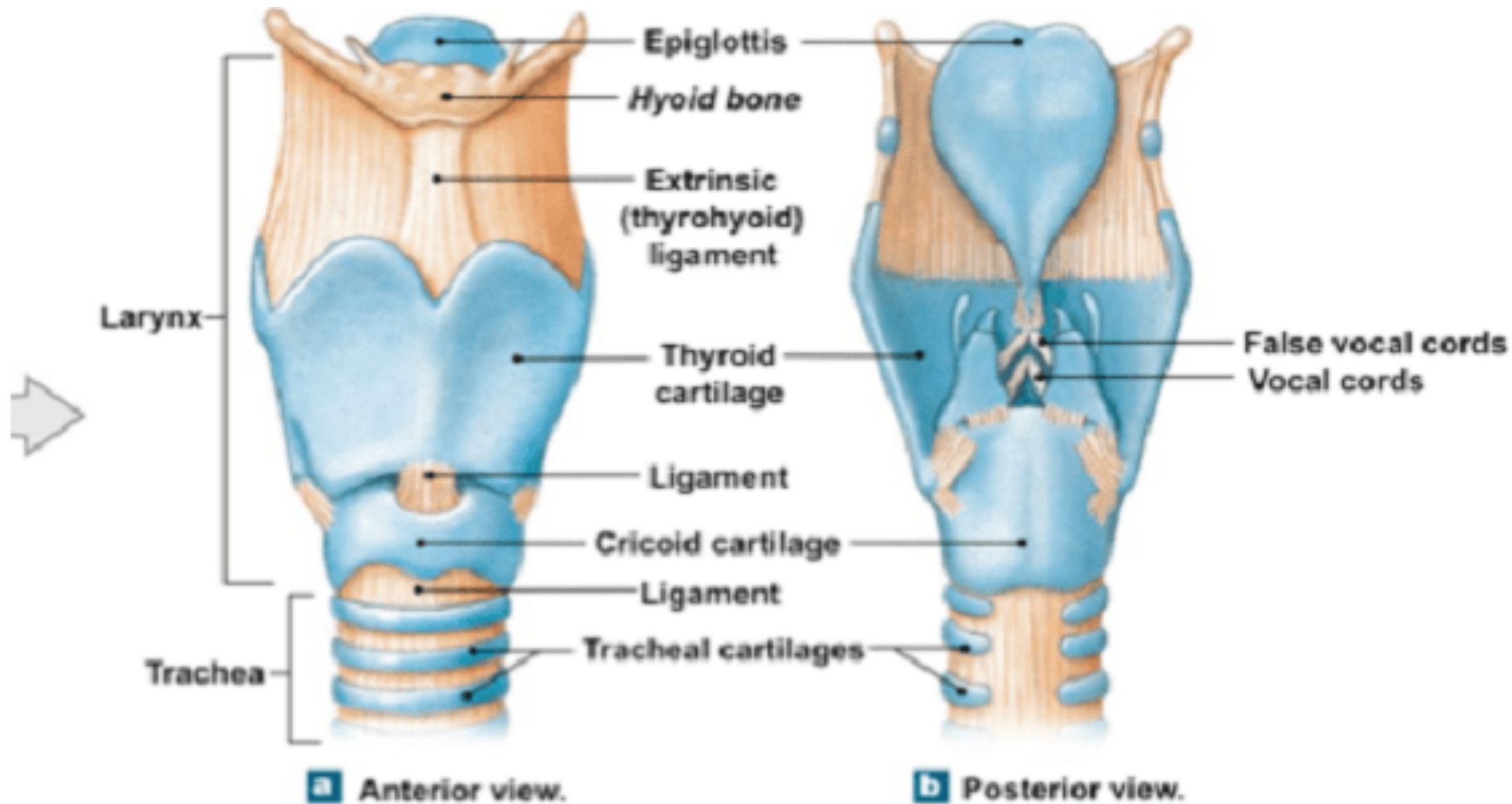
Is swallowing voluntary or involuntary process?

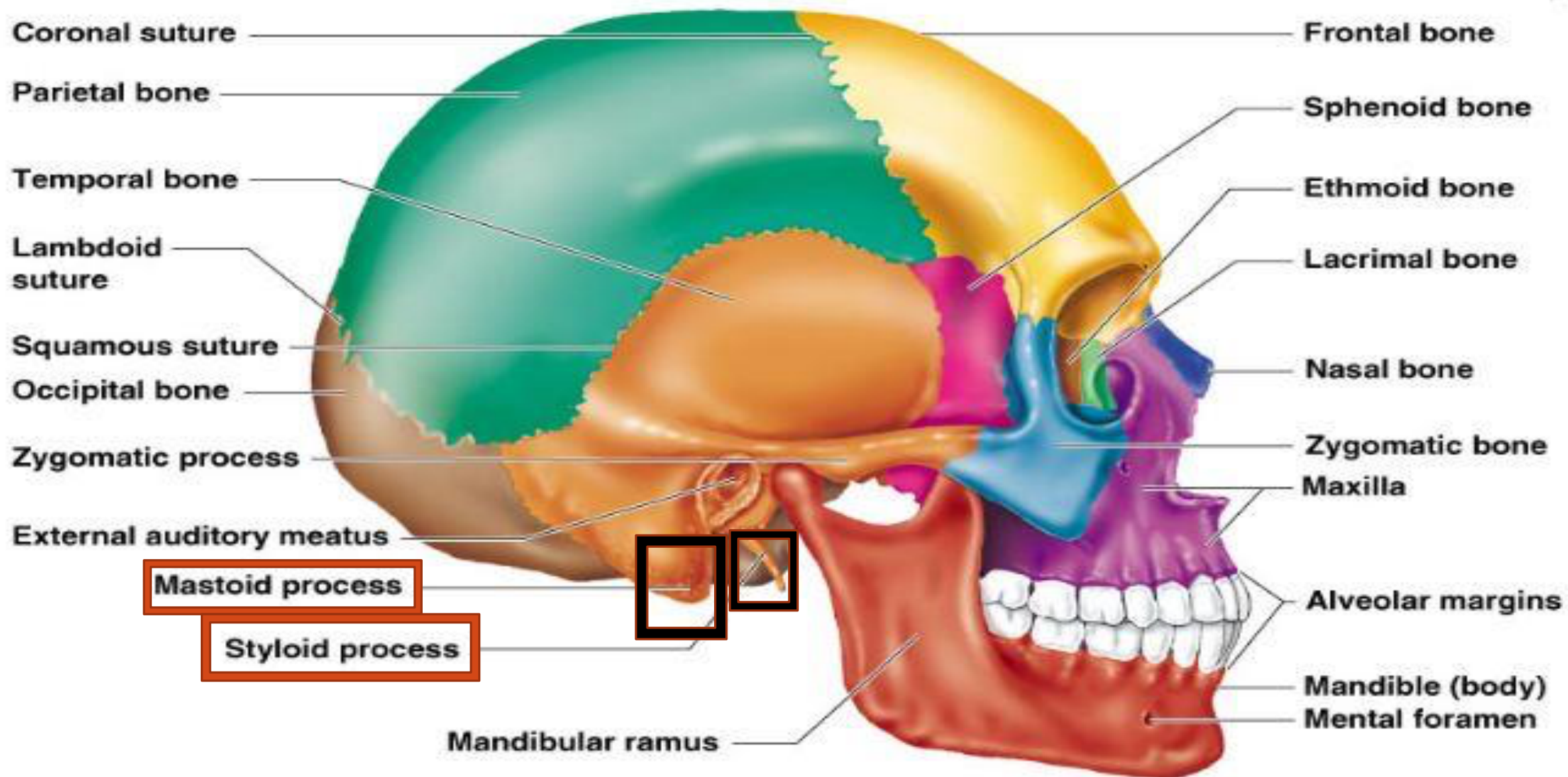


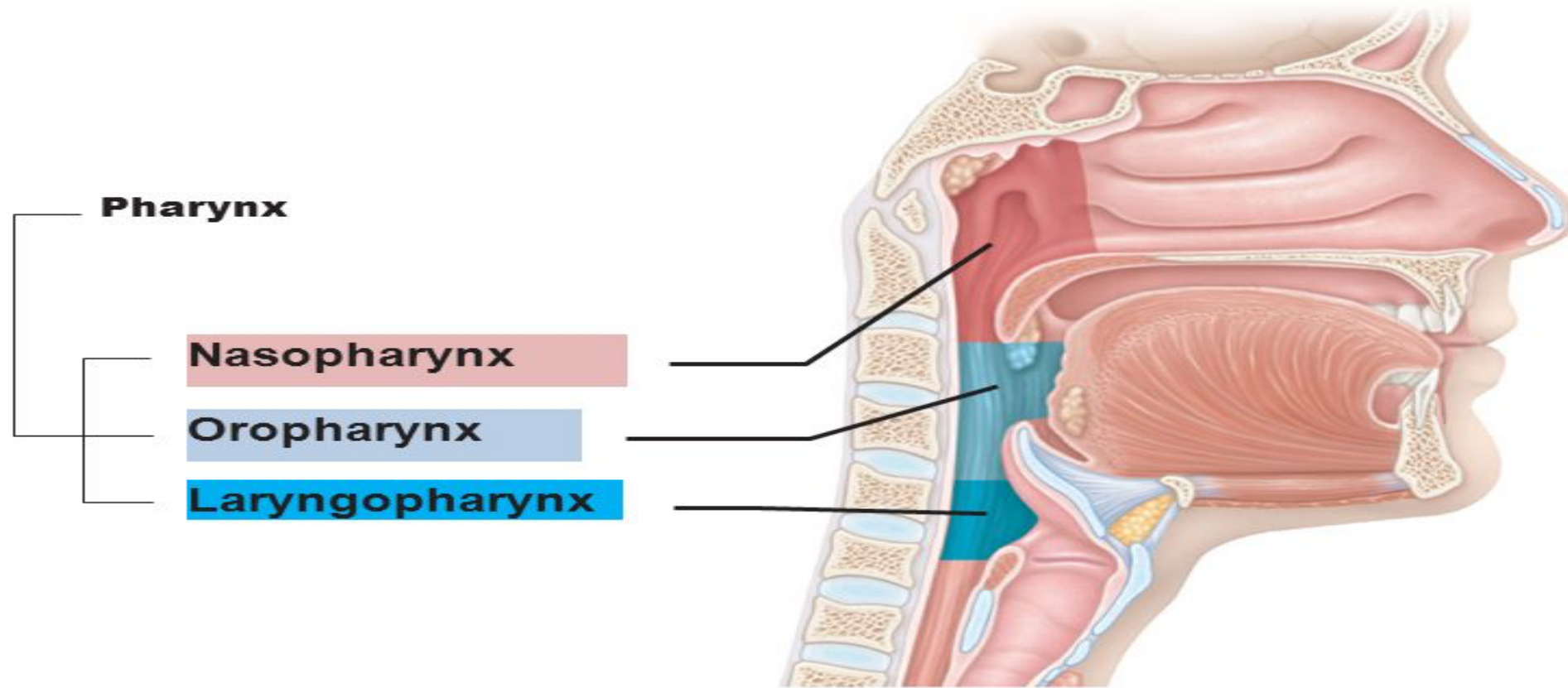
Muscles, bones, cartilage and cavities associated with swallowing:

- Oral cavity
 - Nasal cavity
 - Face
 - Pharynx
 - Larynx
 - Esophagus
 - Trachea
 - Lungs
- Four tubes
that Pass
through
The neck
- 









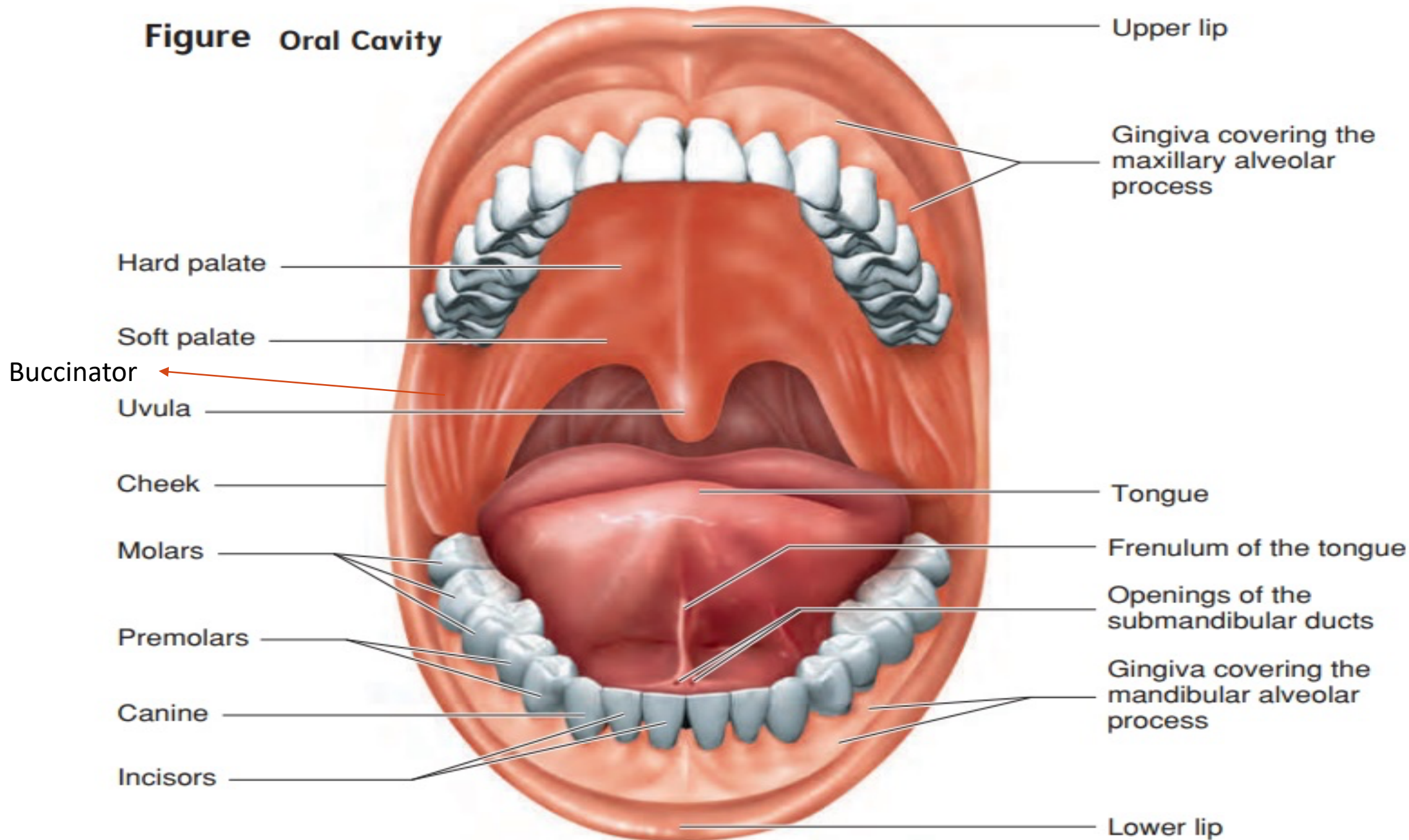
Nasopharynx

- Receptors to smell the food.
- Behind the nasal cavity is the nasopharynx.
- In certain situations of swallowing disorders, food is seen to pass into the nasal cavity.

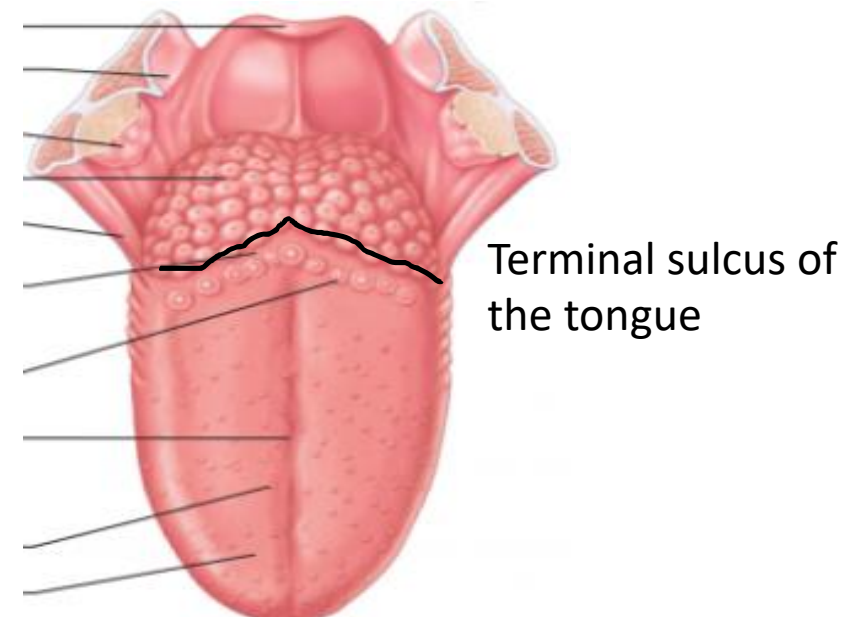
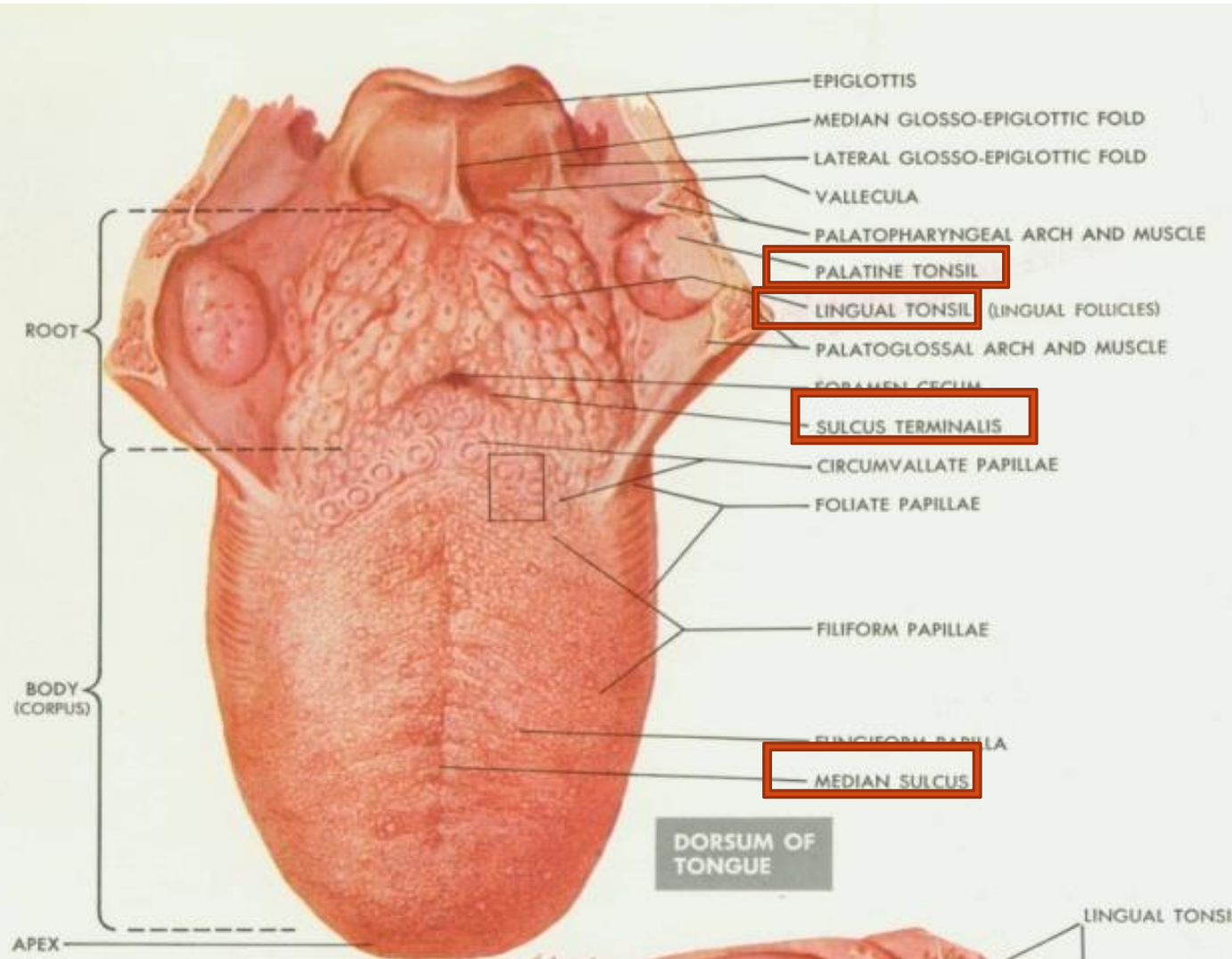
The Oral Cavity

- Extends from lips to nasopharynx
- Separated from nasal cavity by hard and soft palate
- Composed of
 - Lips
 - Tongue
 - Teeth
 - maxilla (hard + soft palate)
 - Velum work with posterior nasopharynx as VP port
 - Mandible
 - Buccal mucosa
 - Buccinator muscles

Figure Oral Cavity



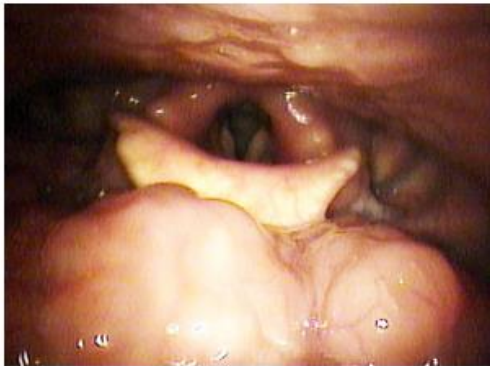The tongue – Oral cavity



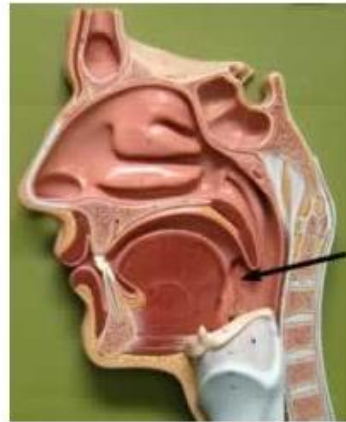
Tonsils

Causes of enlarged tonsils: infection, reflux, food allergies, cyst, cancer.

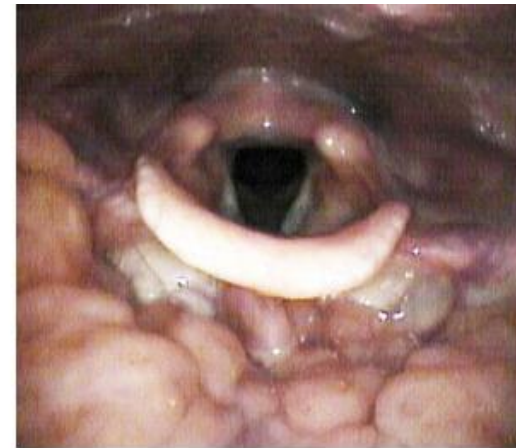Symptoms: sensitive gag, difficulty swallowing.



Note the enlarged lingual tonsils compared to normal appearance above.



Arrow pointing to the base of tongue region where the lingual tonsils are found.



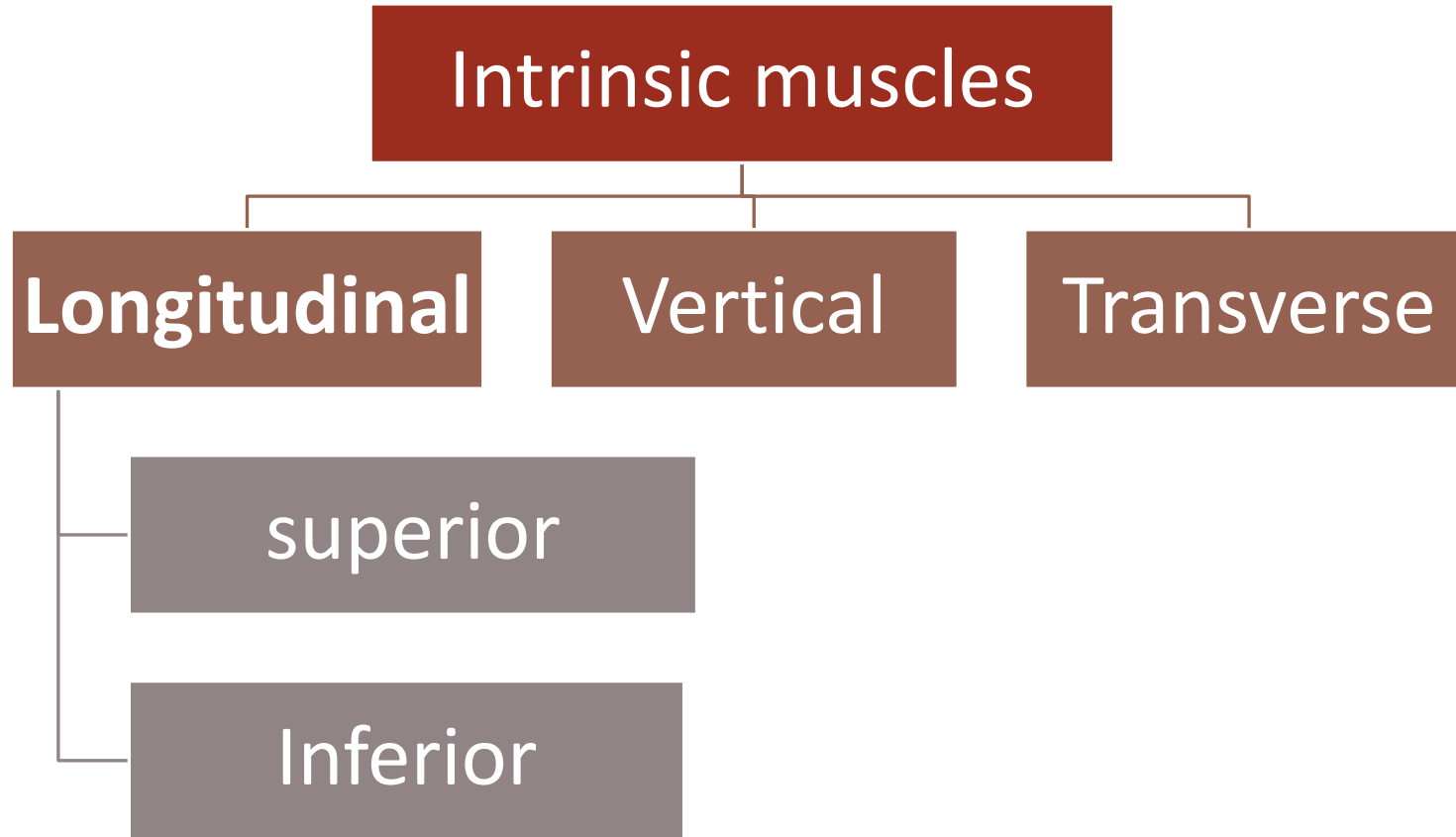
The bottom half of the picture is the base of tongue. The lingual tonsils are the lumpy masses found in this region and is normal.

This view is obtained using a fiberoptic endoscope.

Tongue

- Oral tongue: 2/3 anterior
 - Apex: The tip of the tongue
 - Corpus: The body of the tongue
 - Pharyngeal tongue: 1/3 posterior
 - Also called the root / base of the tongue
- ❖ The oral tongue begins in the apex and ends in the soft palate. The pharyngeal tongue begins in the soft palate and ends in its connection to the hyoid bone (Logemann 1997).
- ❖ Anatomical: The terminal sulcus separates between the oral part the pharyngeal part of the tongue
- ❖ The tongue is made up of **internal** muscles that determine the **shape** of the tongue, and is connected to other areas through the **External** muscles that determine the **position** of the tongue.

Tongue



Intrinsic Muscles of the Tongue

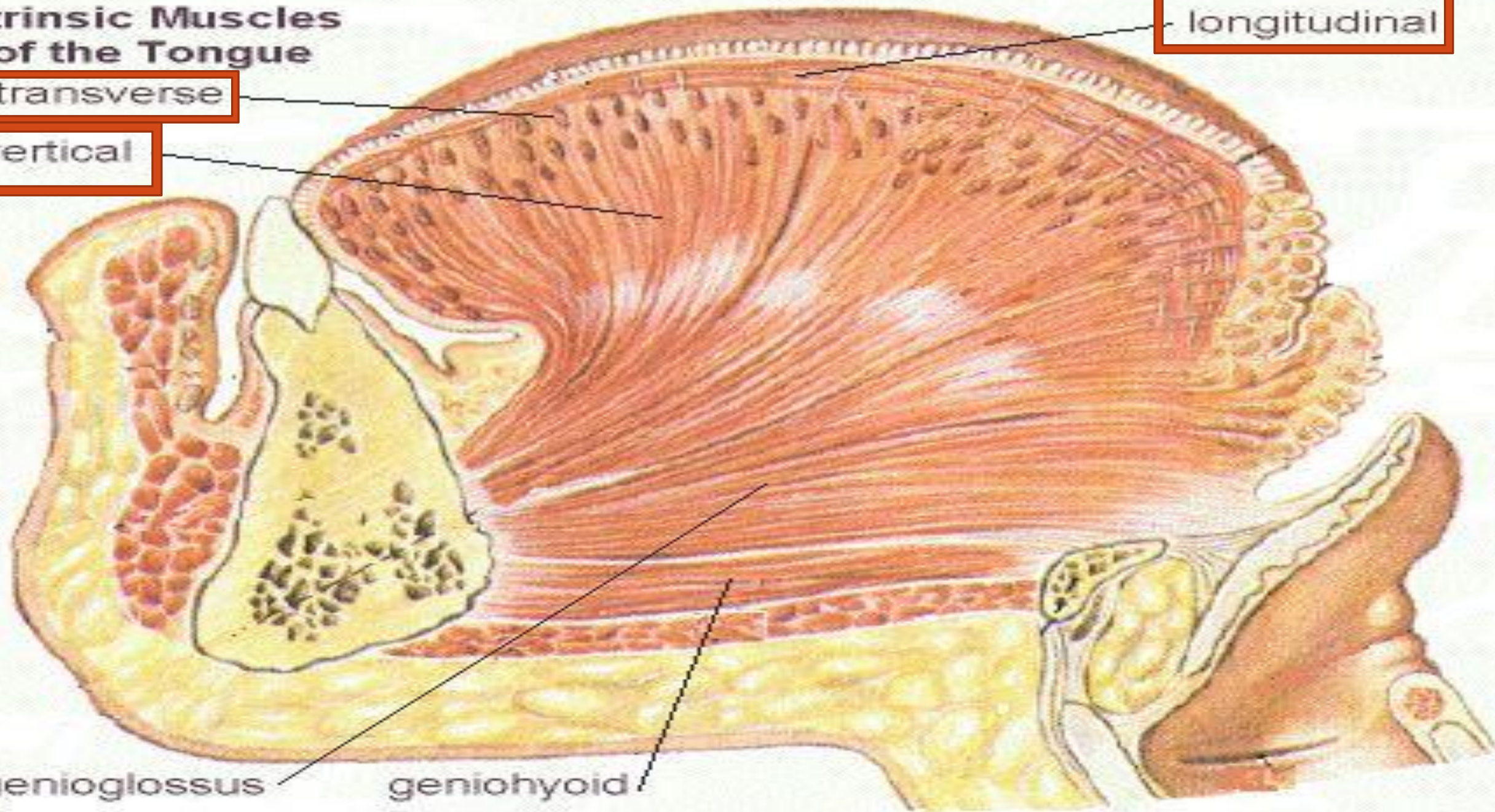
transverse

vertical

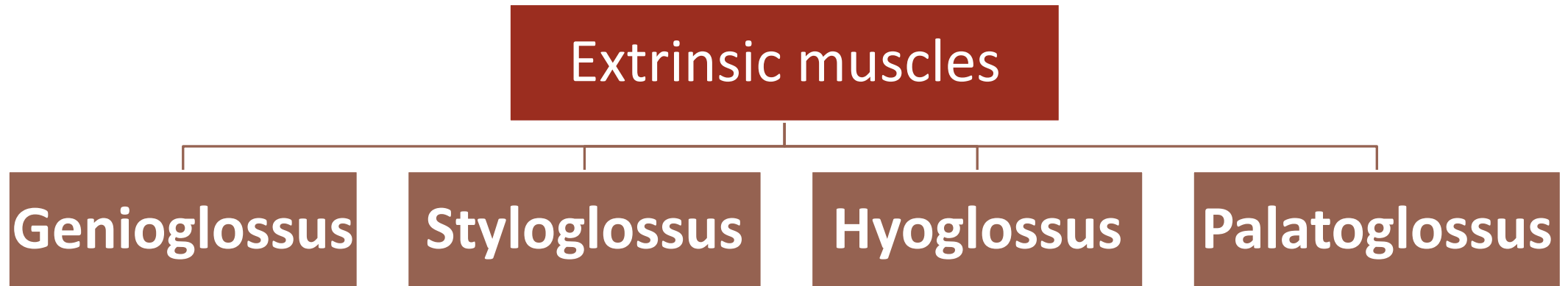
longitudinal

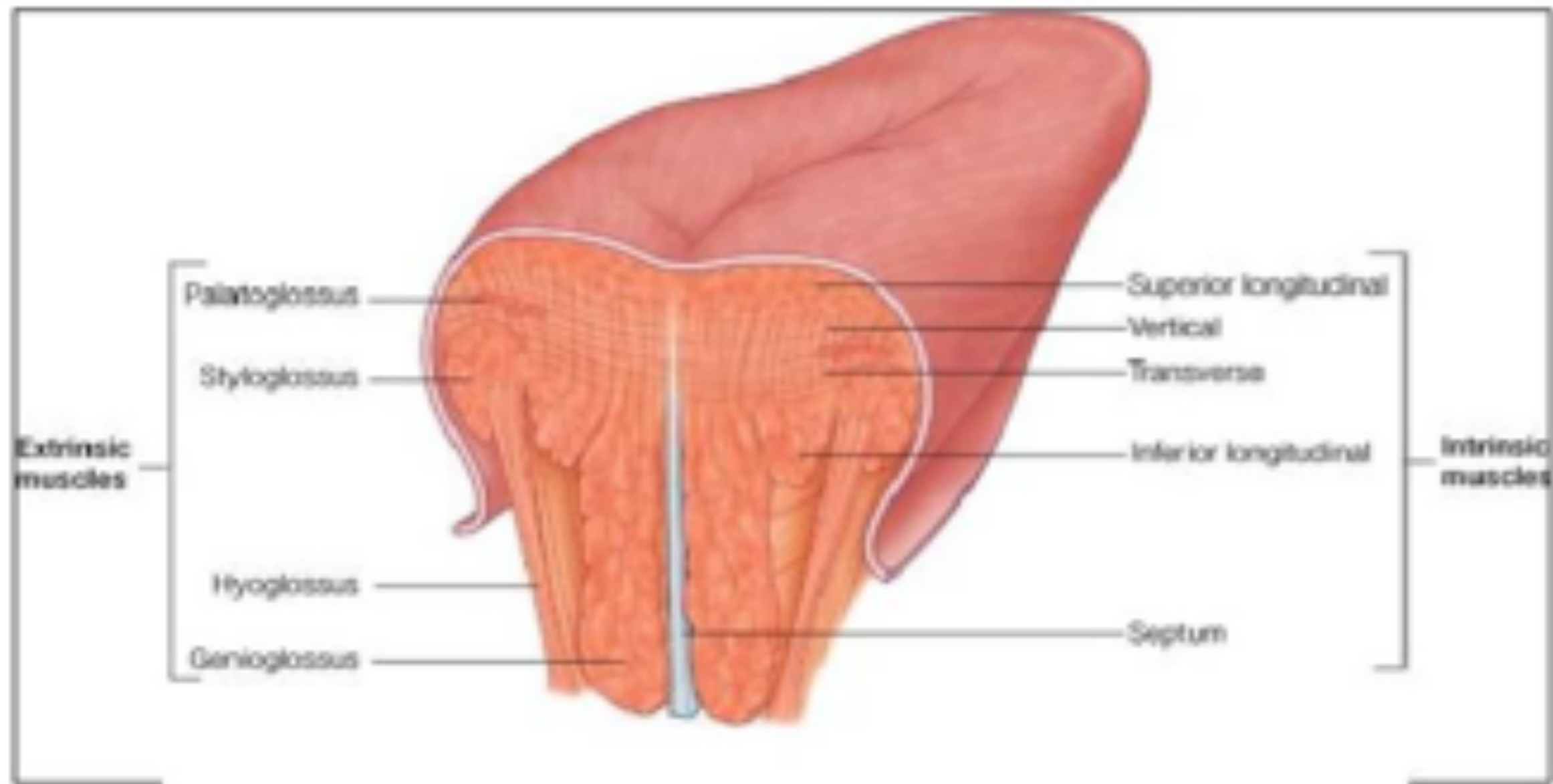
genioglossus

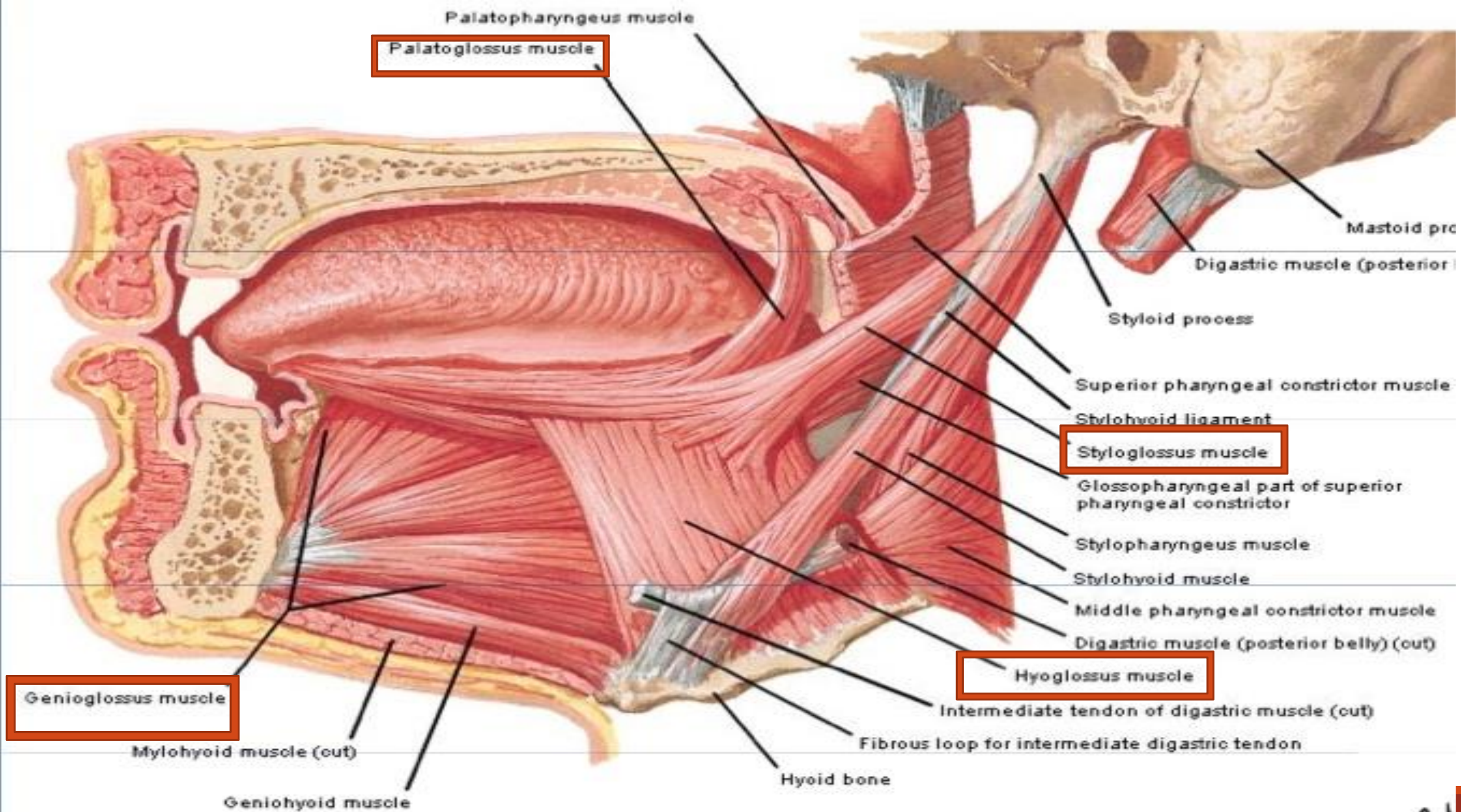
geniohyoid



Tongue







Oral Cavity - Soft palate muscles

1. Levator veli palatini
2. Tensor veli palatini
3. Palatoglossus
4. Palatopharyngeus
5. Uvular

Tensor veli
palatini muscle

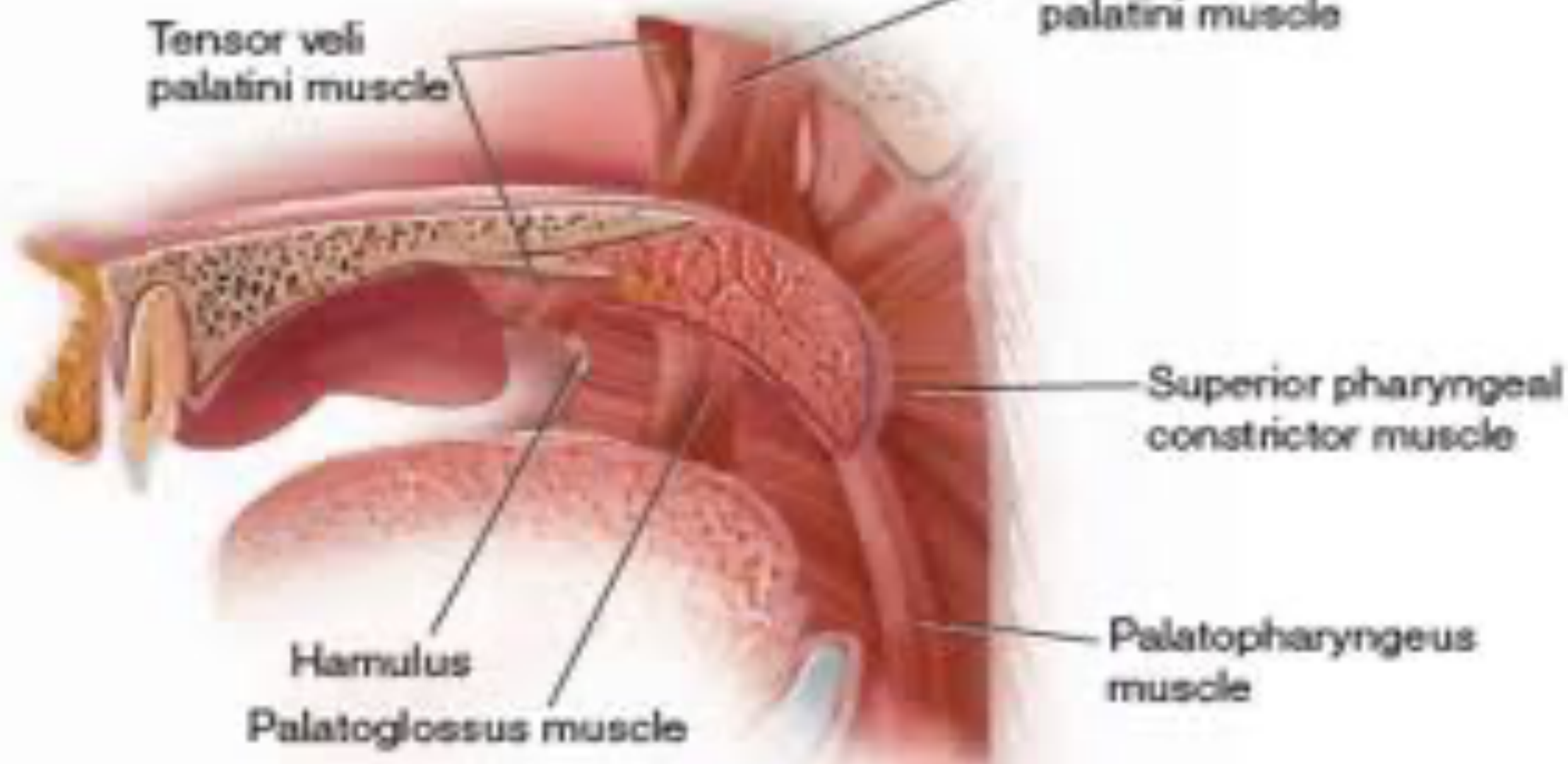
Levator veli
palatini muscle

Superior pharyngeal
constrictor muscle

Hamulus

Palatoglossus muscle

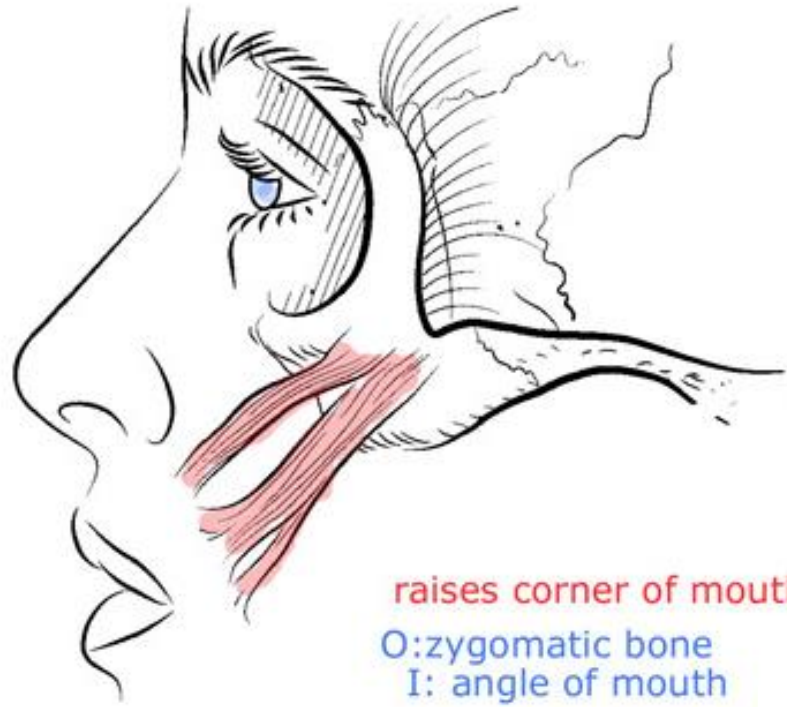
Palatopharyngeus
muscle



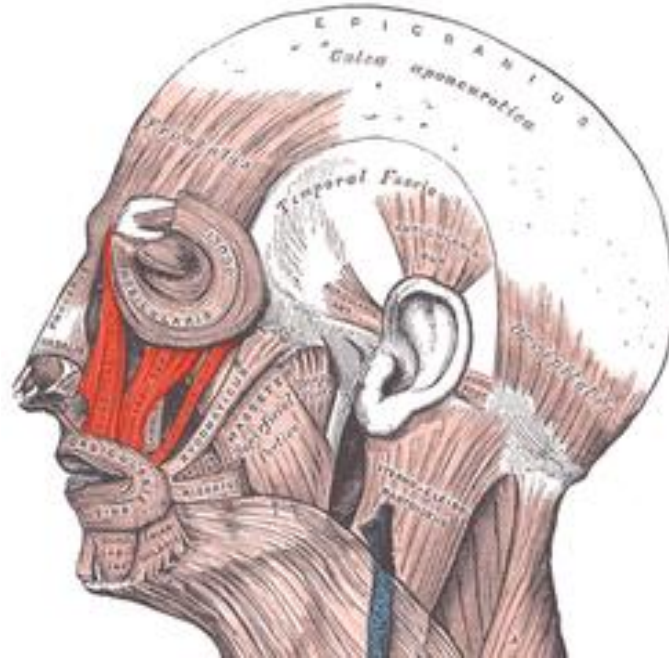Muscles of expression and lips

1. Zygomaticus
2. Quadratus labii superioris (levator labii superioris)
3. Depressor labii inferioris
4. Orbicularis oris
5. Risorius

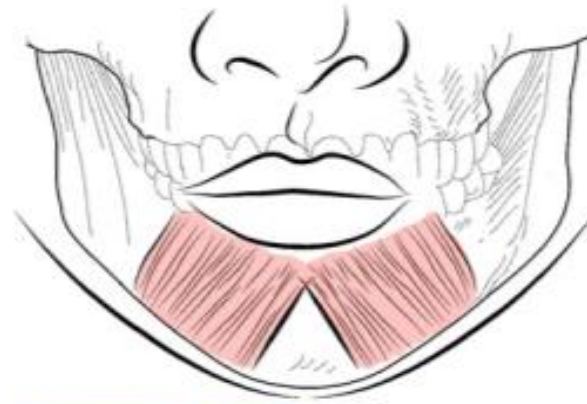Zygomaticus



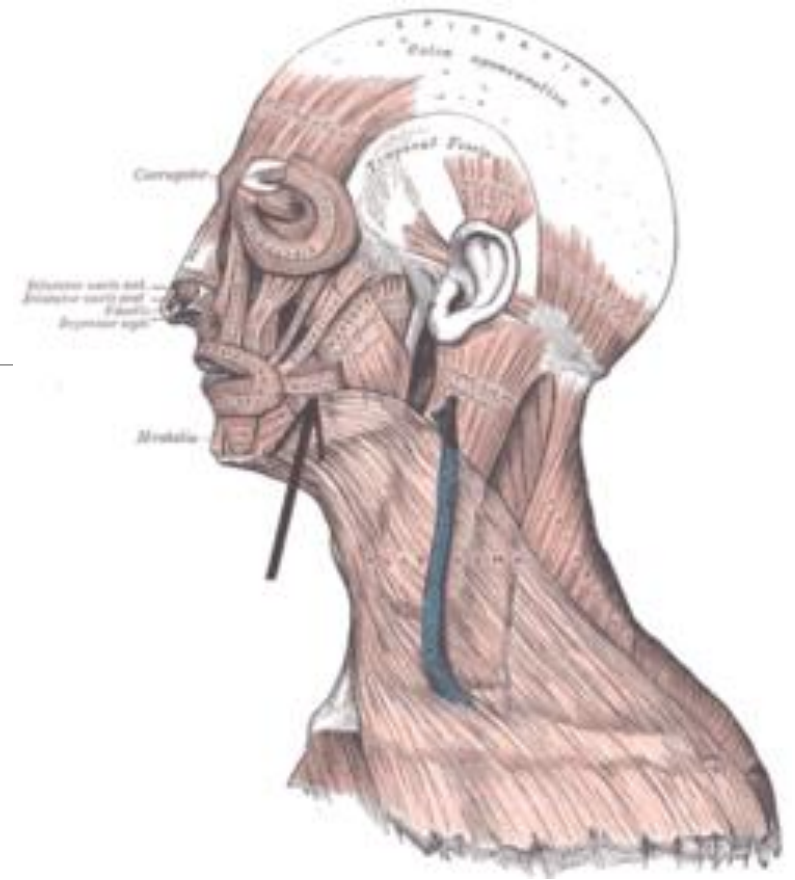
raises corner of mouth
O: zygomatic bone
I: angle of mouth



depressor labii inferioris
depresses lower lip

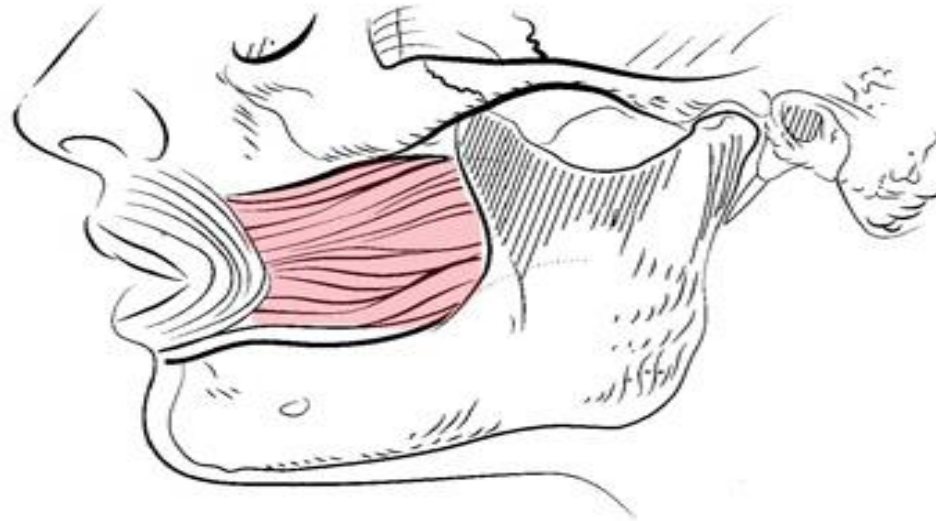


O: inferior border of mandible
I: skin of inferior lip and orbicularis oris muscle



The Cheek muscles

Buccinator



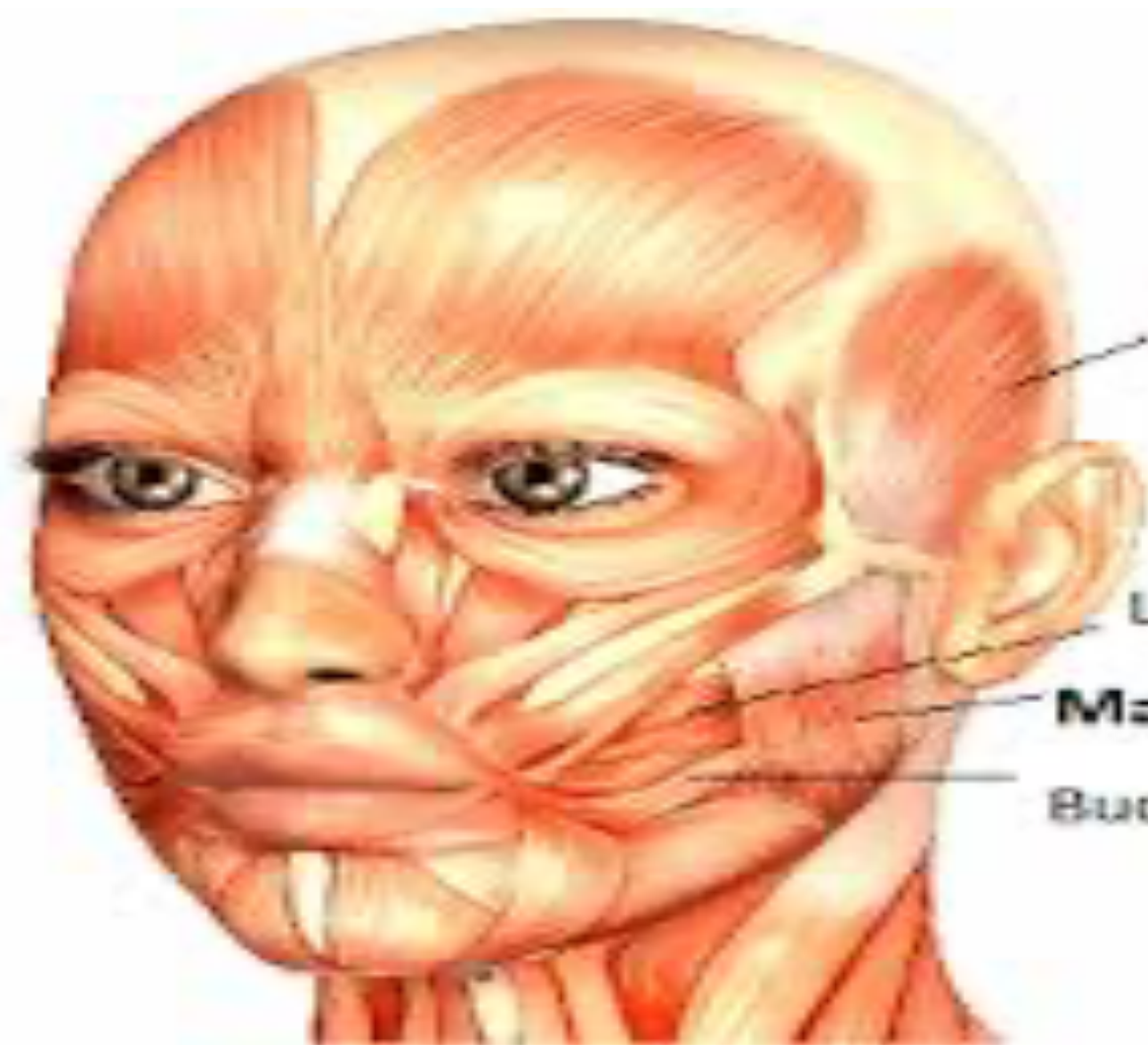tightens the cheek

O: mandible and maxilla

I: orbicularis oris

The Chewing muscles

- Temporalis
- Masseter
- Medial (Internal) pterygoid
- Lateral (External) pterygoid



Temporalis Muscle

Lateral Pterygoid

Masseter Muscle

Buccinator Muscle

Salivary glands

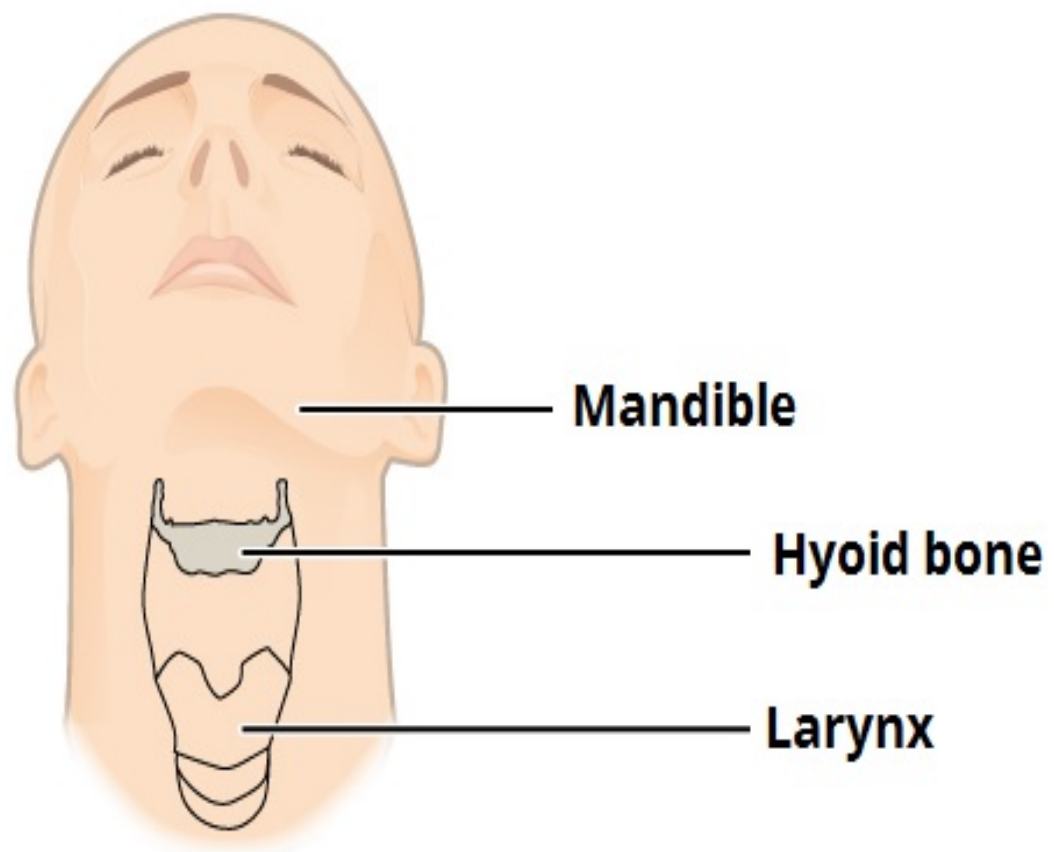
- The salivary glands produce two types of saliva:
 - Thick saliva that is important for lubrication (produced even without stimulation)
 - Thin saliva is rich in protein and important for digestion (produced in response to irritation).
 - 1- Sub-Mandibular
 - 2- Sub-lingual
 - 3- Parotid
- The parotid gland produces 50% of the amount of saliva produced in response to a stimulus. Contributes 20% of the amount of saliva in non-irritating situations.
- The three glands together provide 90% of saliva.

The importance of the saliva

- Cleaning the oral cavity
- Protection of the teeth
- Protecting the esophagus
- Serves as protection against bacteria with the help of proteins found in saliva.
- Maintaining mucus moisture.
- Homogeneous bolus
- The sense of taste

Hyoid bone

- Height C3.
- Above the larynx, below the mandible and the base of the tongue
- It is floating bone
- Its movement depends on forces operated on it
- Grip point of lots of muscles:
 - Supra-hyoid muscles
 - Infra-hyoid muscles
- While swallowing, the hyoid moves forward and up



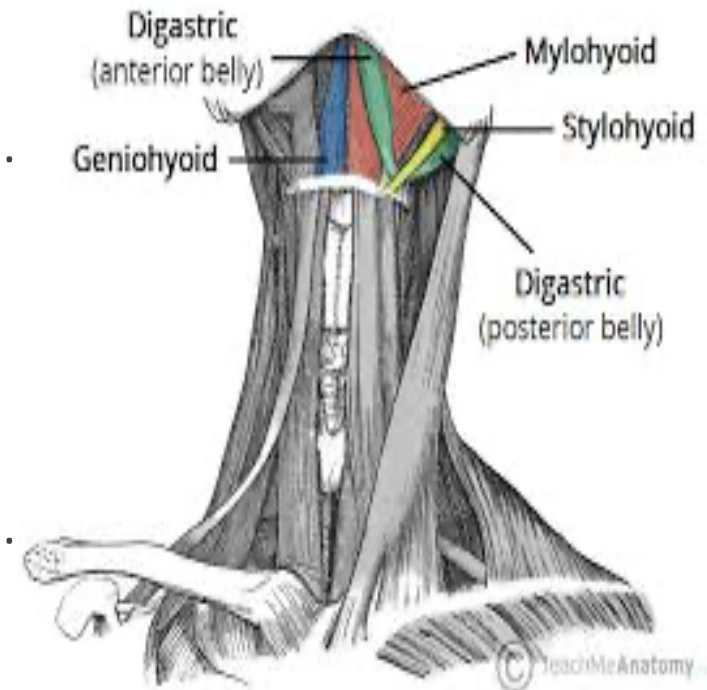
Suprahyoid muscles

- **Anterior belly of digastric**

- From the mandibular protrusion to the hyoid.
- ❖ When the hyoid is fixed - opens the jaw.
- ❖ When the hyoid is not fixed - pulls the hyoid and throat up and forward.

- **Mylohyoid**

- From the inner margins of the mandible to the Hyoid.
- ❖ When the hyoid is fixed - opens the jaw.
- ❖ When the hyoid is not fixed - pulls the hyoid and throat up and forward.



- **Geniohyoid**

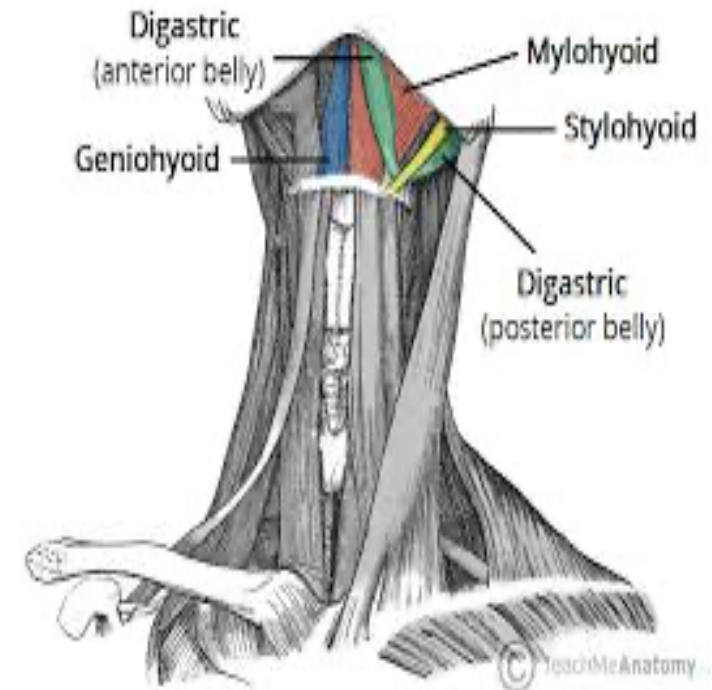
- From the mandibular displacement to the hyoid
- ❖ When the hyoid is fixed - opens the jaw
- ❖ When the hyoid is not fixed - pulls the hyoid and throat up and forward.

- **Posterior belly of digastric**

- From the mastoid to the hyoid
- ❖ Pulls the hyoid (and the back of the tongue) up and back

- **Stylohyoid**

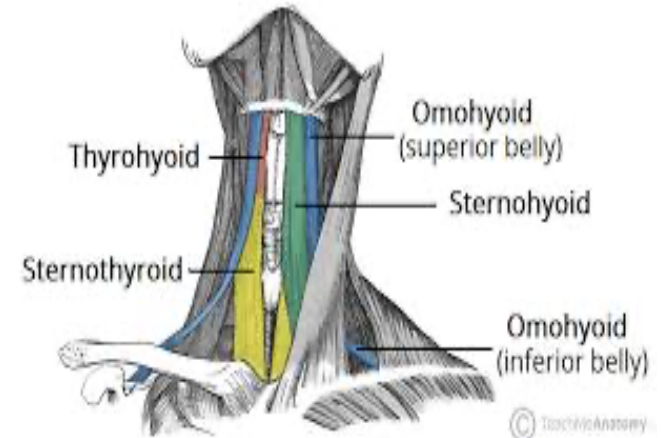
- From the styloid to the hyoid
- ❖ Pulls the hyoid (and the back of the tongue) up and back



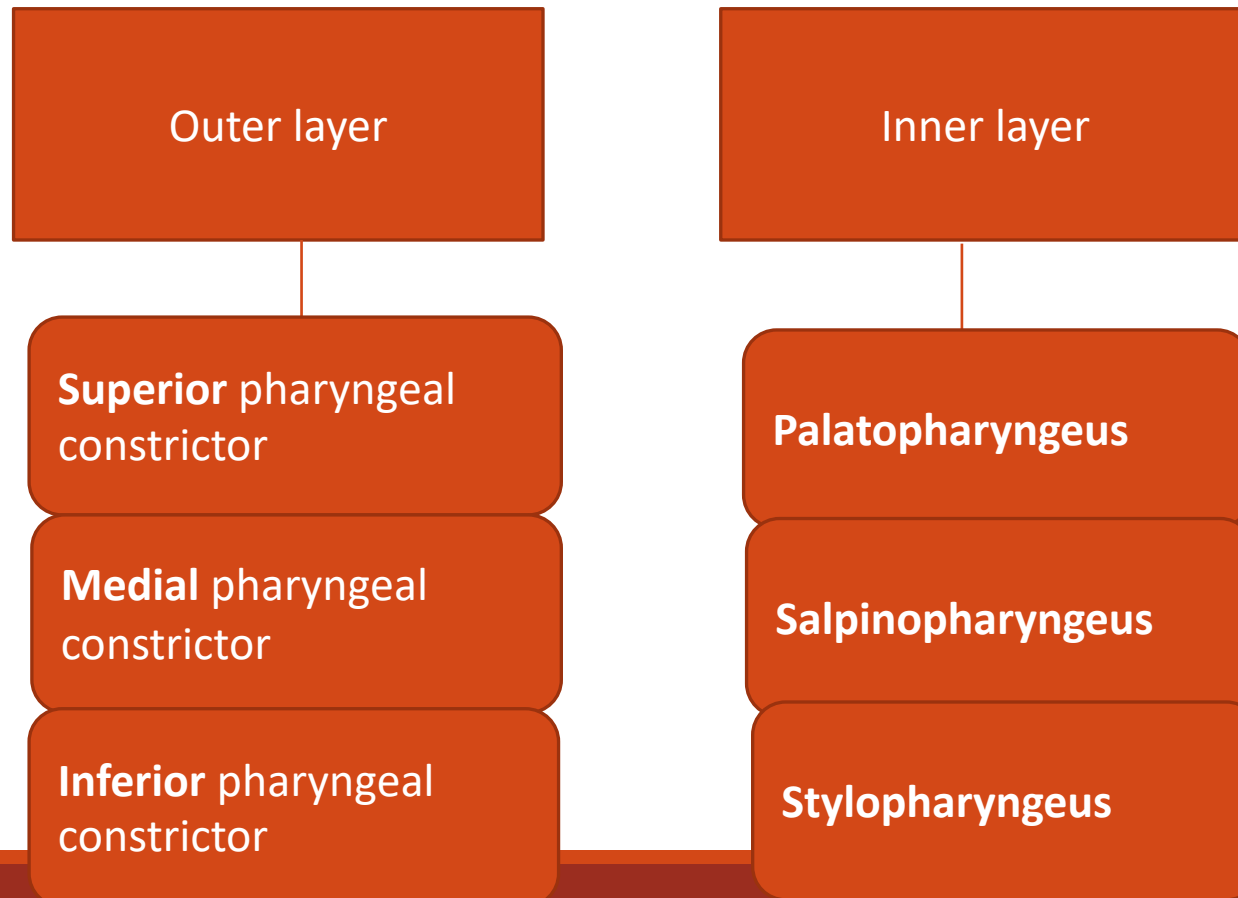
Infra-hyoid muscles

- **Omohyoid** - from scapula to hyoid
- **Sternohyoid** - from sternum to hyoid
- **Sternothyroid** - from sternum to thyroid
- **Thyrohyoid** - from thyroid to hyoid

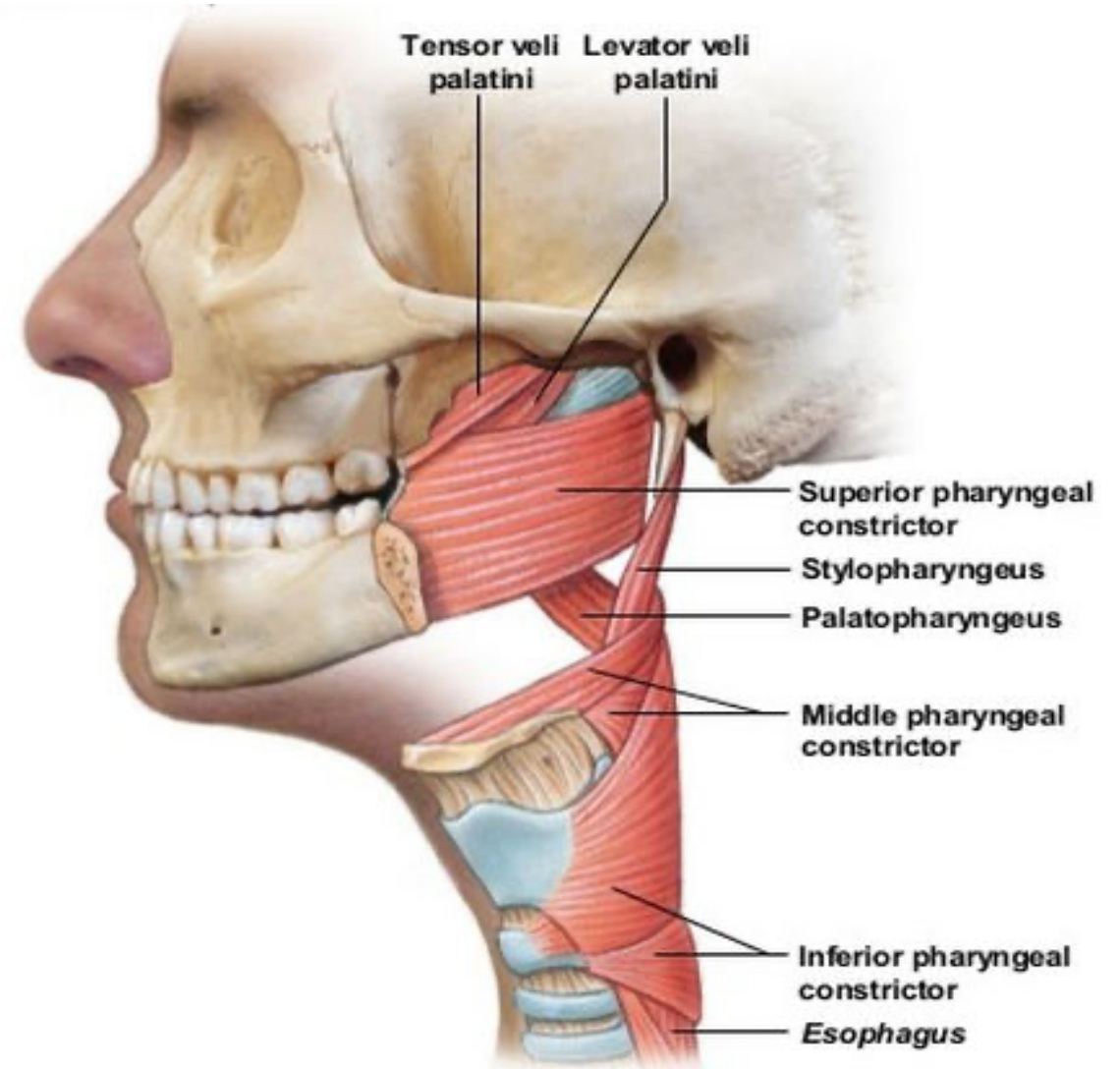
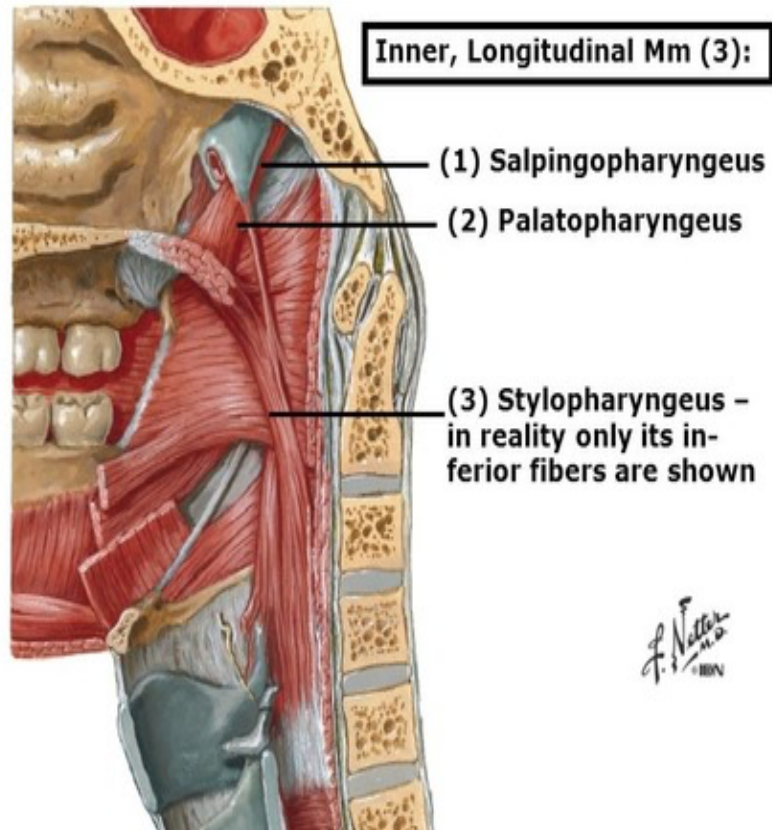
Pull the hyoid down / fix the hyoid in place (fixation is important when opening the jaw)



Pharyngeal muscles

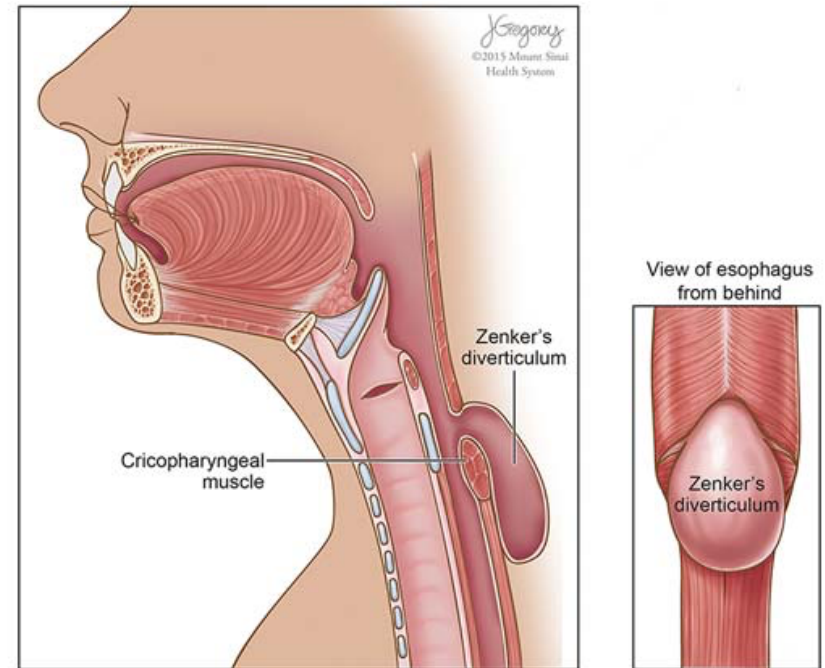
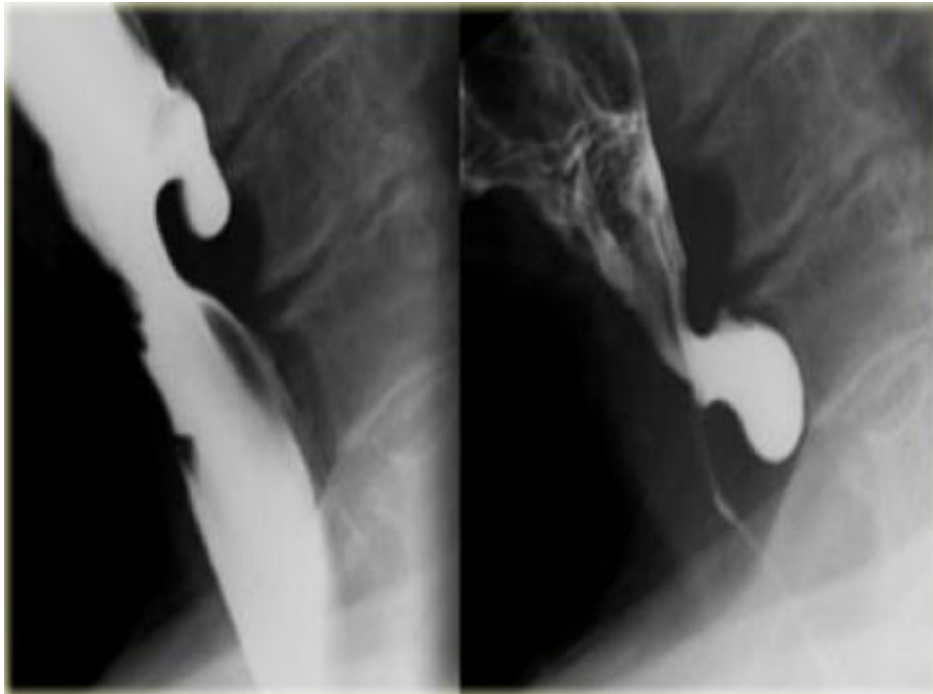

Muscles of Pharynx: Median (Sagittal) Section



Zenker's Diverticulum

Also called pharyngeal pouch, is a **diverticulum** of the mucosa of the human pharynx, just above the cricopharyngeal muscle (i.e. above the upper sphincter of the esophagus).



Different structures and cavities in the pharynx

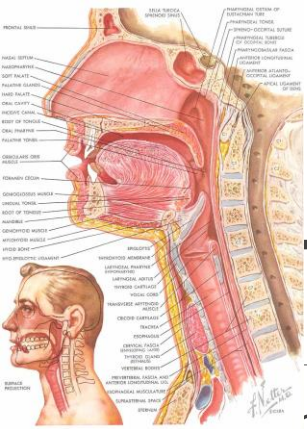
In addition to the muscles there are :

The base of
the tongue
/the
pharyngeal
tongue

Epiglottis

Vallecula

pyriform sinus



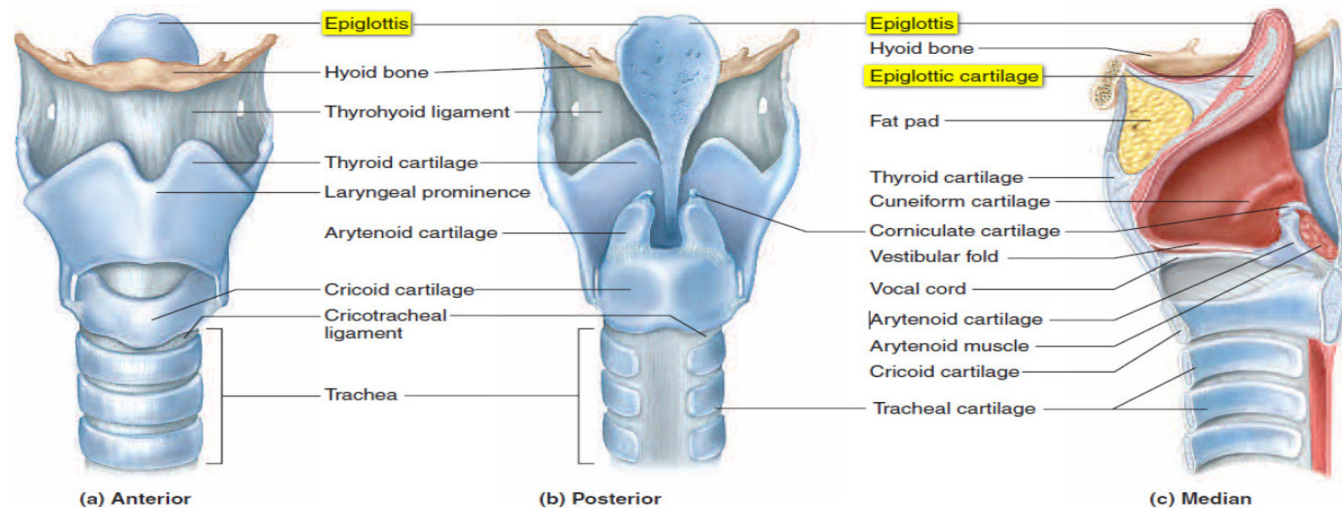
the base of the tongue

, an important role in transferring the bolus from the oral cavity to the pharyngeal cavity.

- After passing the bolus from the mouth to the pharyngeal cavity, the base of the tongue moves backwards towards the wall of the posterior pharynx
- Pressure is created on the bolus and causes it to move downwards towards the hypo-pharynx and esophagus.

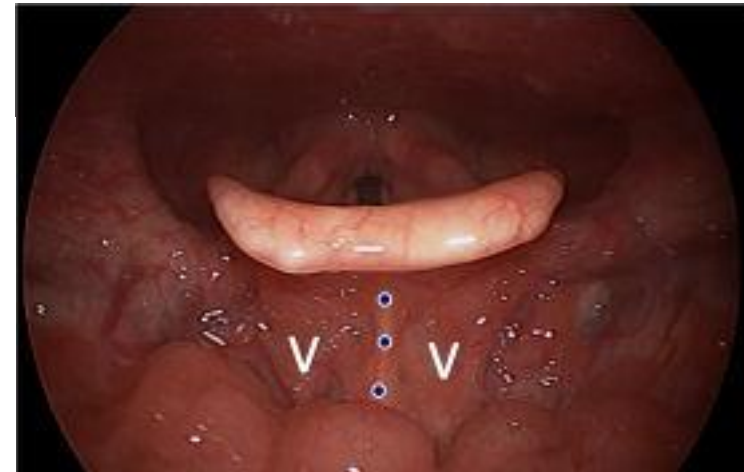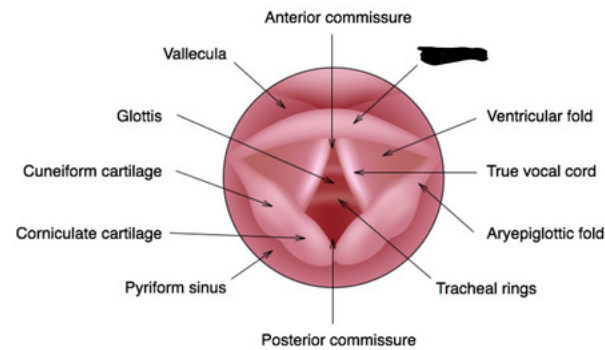
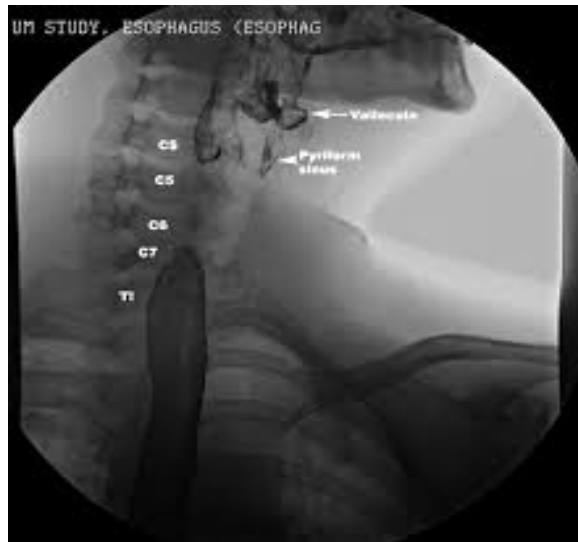Epiglottis

- a leaf-shaped cartilaginous "valve".
- Location: behind the base of tongue.
- Breathing and speaking – it is in a vertical position to allow airflow.
- Swallowing- it is in a horizontal position to protect the trachea and lungs from inhalation of the bolus, and in order to "direct" the bolus towards the esophagus.



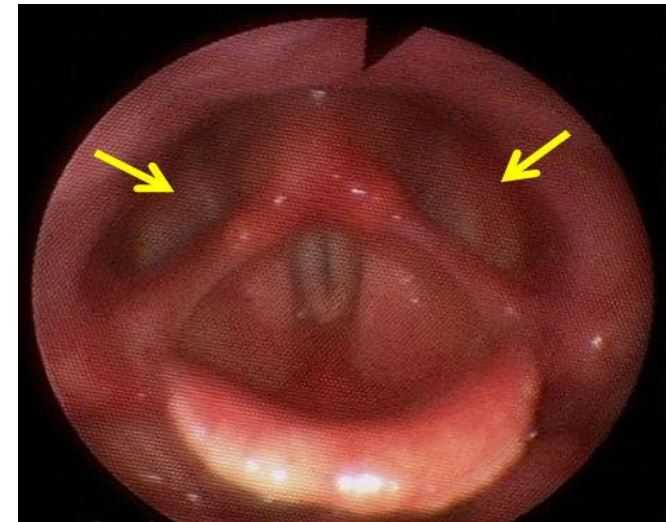
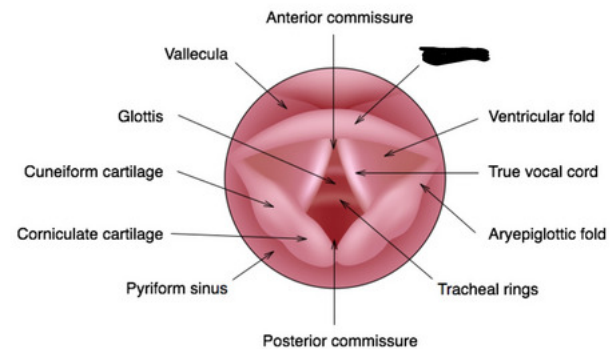
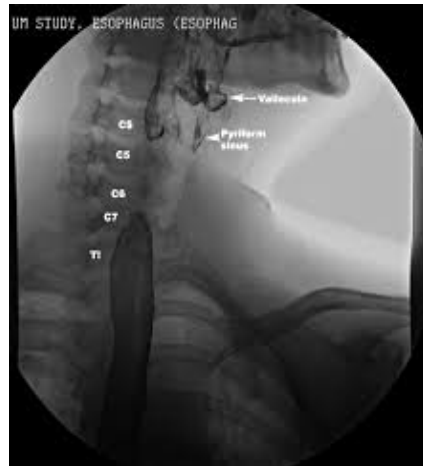Vallecula & Pyriform sinuses

- Vallecula: A concave space bounded by the base of the tongue in front and the lingual part of the epiglottis in the back. Divided into two by the glosso-epiglottic fold.



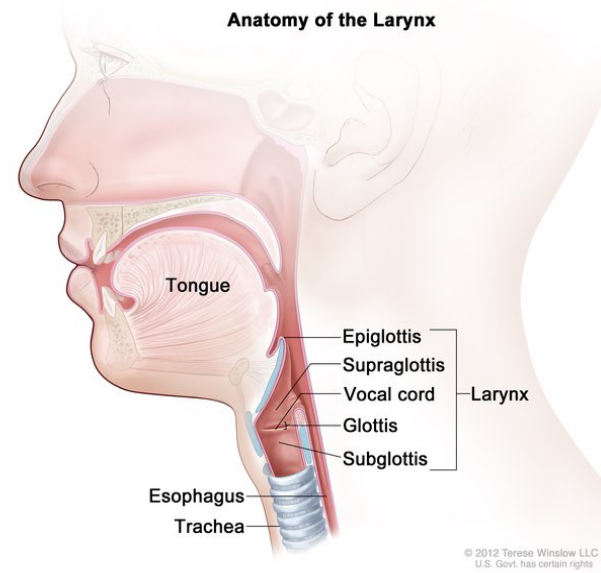
Pyramidal sinuses: Spaces bounded by the posterior pharyngeal wall, thyroid cartilage, and aryepiglottic fold.

The flexion of the epiglottis directs the flow of the bolus to the lateral channels and from there to the preformed sinuses and then to the UES.



Larynx

- Located below the hyoid bone, at vertebral height C3 to C6
- The larynx creates a passage between the pharynx and the trachea.
- While swallowing: The glottis closes.



Larynx during Swallowing

- As the bolus enters the oropharynx, the larynx begins to elevate upward and forward.
- At the same time, the epiglottis tilts down to cover the larynx.



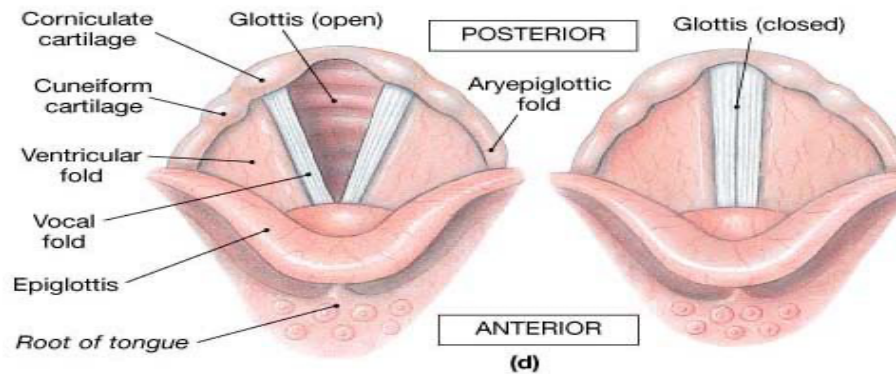
- Laryngeal penetration is thus prevented by a combination of elevation and closure of the larynx and epiglottis tilt.
- Laryngeal movement can be judged by observing the upward and forward movement of the hyoid bone during swallowing.



- Residual bolus not cleared from the pharynx by swallowing, maybe aspirated into the larynx or trachea post-swallow.

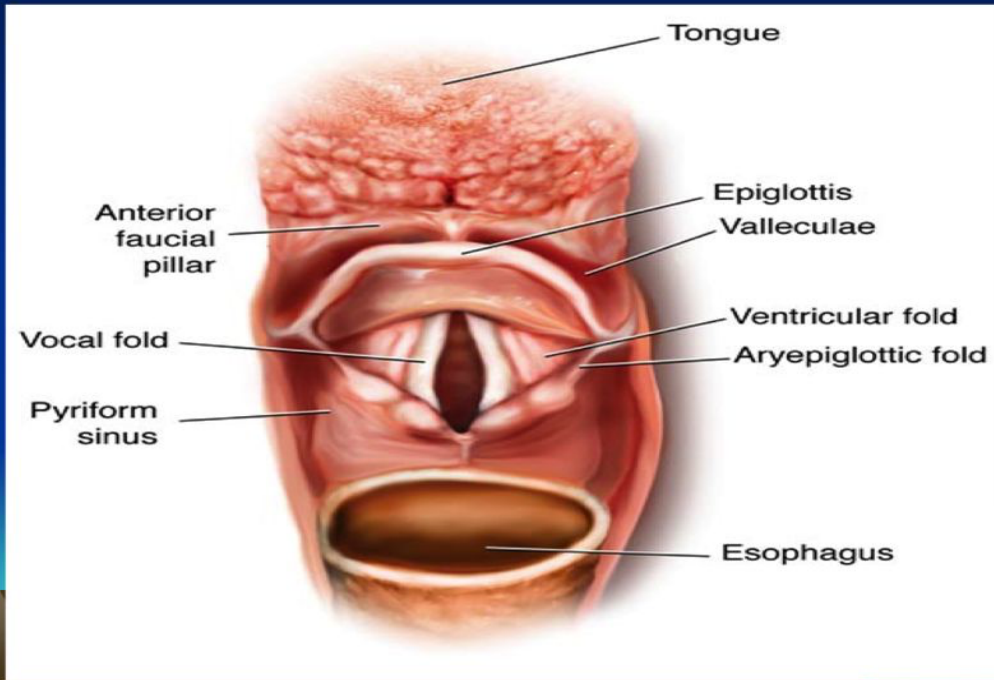
Glottis

- The spacing between the vocal cords. The entrance to the trachea.
- While swallowing: the glottis is closed by the activity of 1- the internal throat muscles that cause the strings to close.
- 2- Mechanical activity: bending the epiglottis



• **FIGURE 23-4** Anatomy of the Larynx. (d) Diagrammatic superior view of the larynx with the glottis open and closed.

- **Paraglottic space:** is a potential space present on either side of glottis. It is bounded by the mucosa covering the lamina of thyroid cartilage laterally, the conus elasticus and quadrangular membranes medially and the anterior reflection of the pyriform fossa mucosa posteriorly .

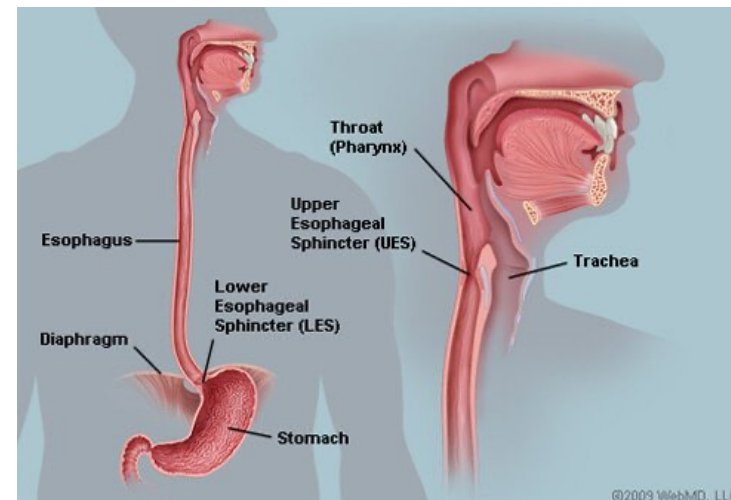


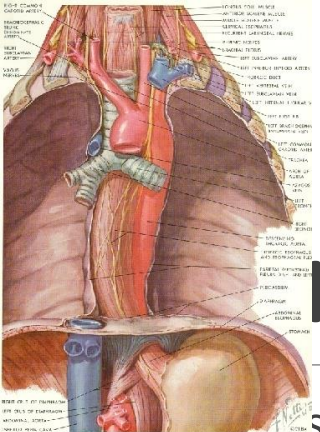
The throat muscles

- **Thyroarytenoid**
- **Transverse arytenoids**
- **Oblique arytenoids**
- **Aryepiglottic muscle**
- **Lateral cricoarytenoid**
- **Posterior cricoarytenoid**
- **Cricothyroid**

Esophagus

- It is a muscular tube connecting the throat (pharynx) with the stomach.
- It is about 18-22 cm on average, and is lined by moist pink tissue called mucosa.
- It runs behind the windpipe (trachea) and heart, and in front of the spine.
- It starts from the lower border of the UES (the UES is part of the pharynx) and continuing down through an opening in the diaphragm called LES.
- UES = Upper Esophageal Sphincter
- LES = Lower Esophageal Sphincter

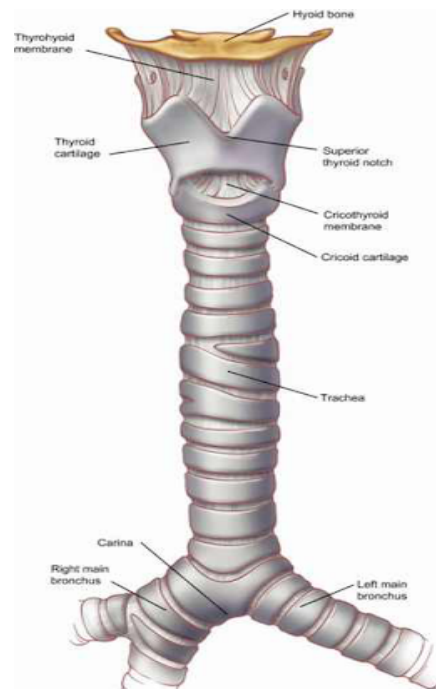
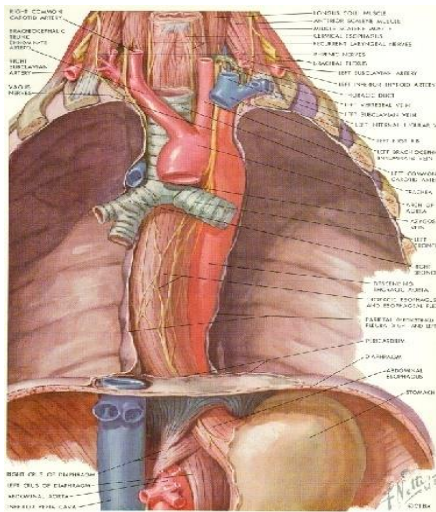




Trachea and lungs

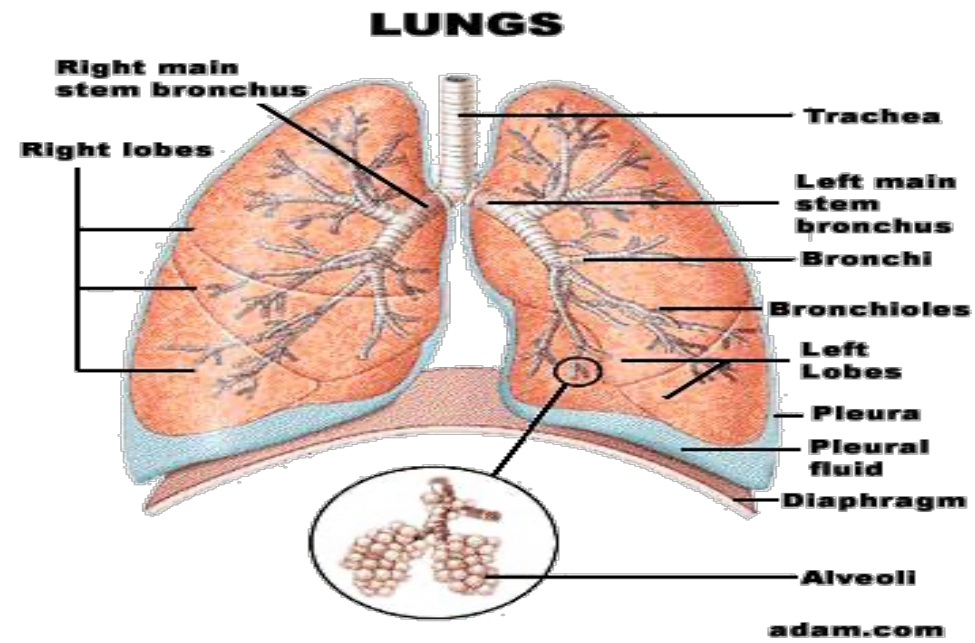
also called the windpipe

- Cartilaginous tube that connects the larynx to the bronchi of the lungs, allowing the passage of air.



Lungs

- Cilia
- COPD (Chronic obstructive pulmonary disease).



The Differences in the structure between babies and adults:

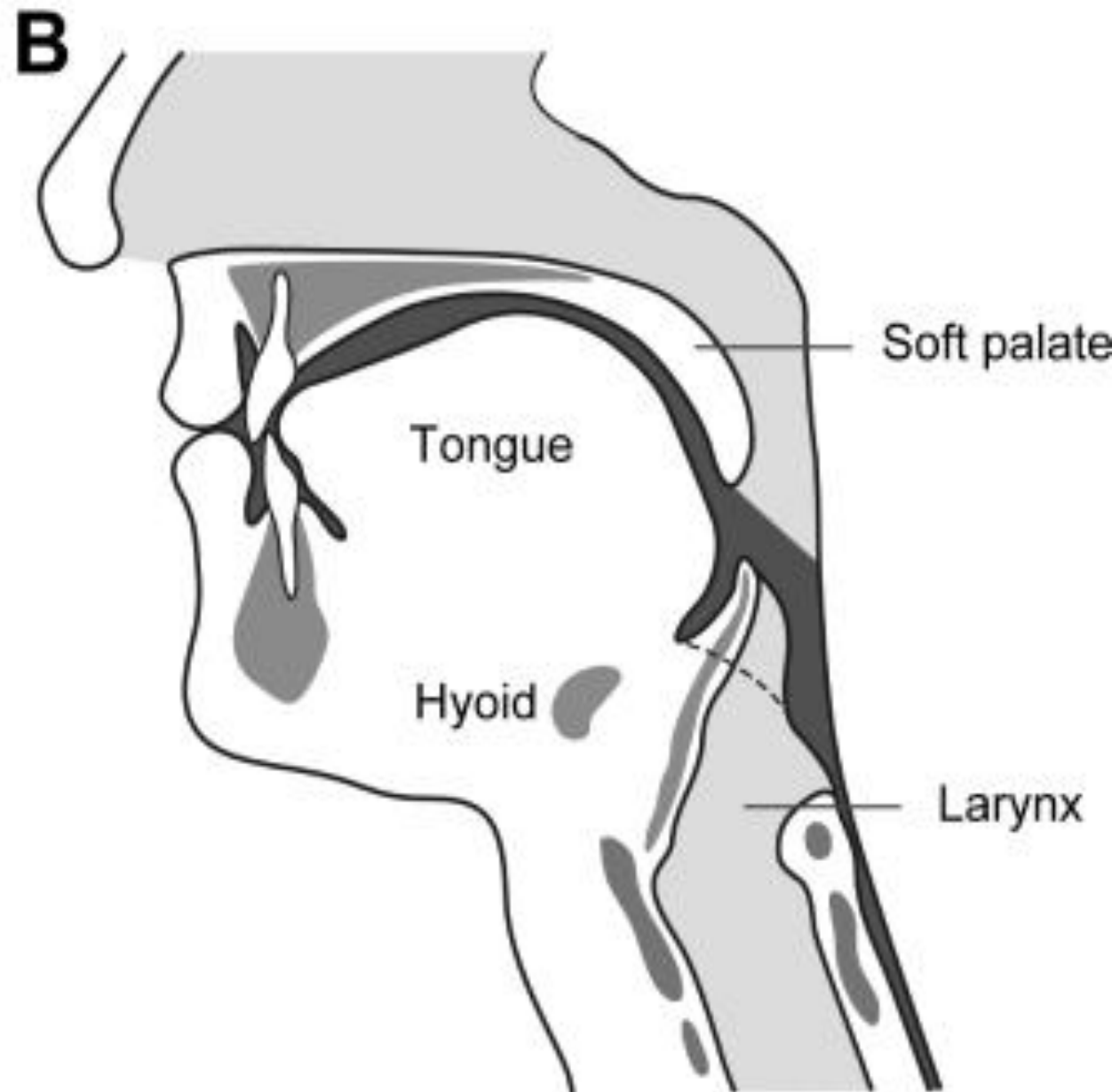
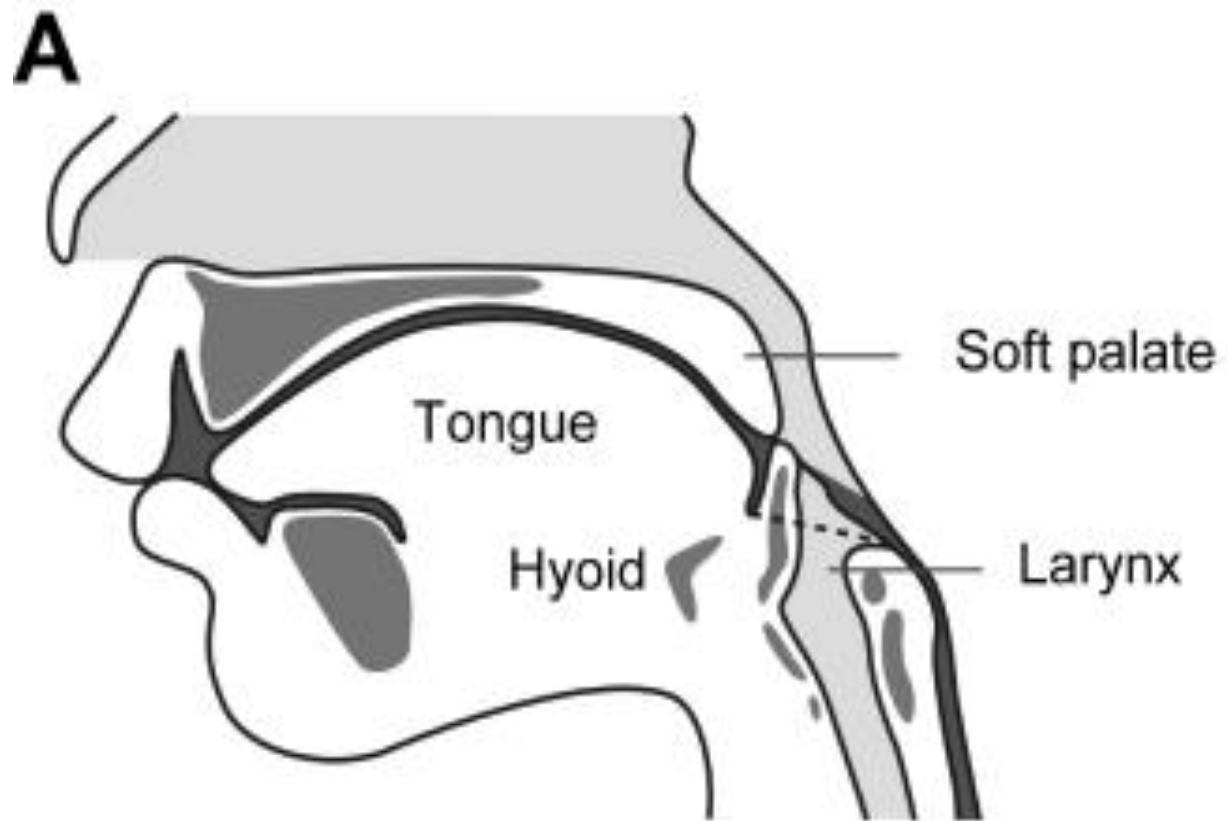
Adults:

- Weaker muscles.
- Slow and weaker chewing.
- Teeth.
- senses.
- Mucous.
- increased swallowing time.
- Reduced throat.
- Slow cleaning from the esophagus.

Babies:

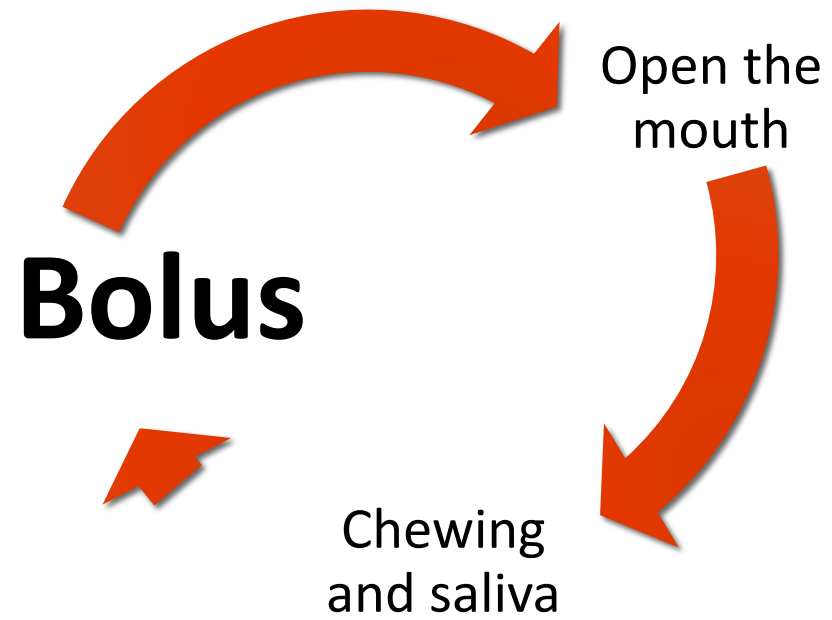
4 months

- Large head, short neck.
- Tongue's size
- The larynx is high.
- The epiglottis is long, stiff and U-shaped.
- Cheeks.
- The base of the tongue.
- More protection.
- The baby's resonance spaces are smaller.



Phases of swallowing:

1. **Oral preparatory Phase.**
2. **Oral Stage:** transfer of material from mouth to oropharynx.
3. **Pharyngeal Stage:** transport of material away from oropharynx, into the upper esophagus.
4. **Esophageal Stage:** transfer of material along esophagus into the gastric cardia.



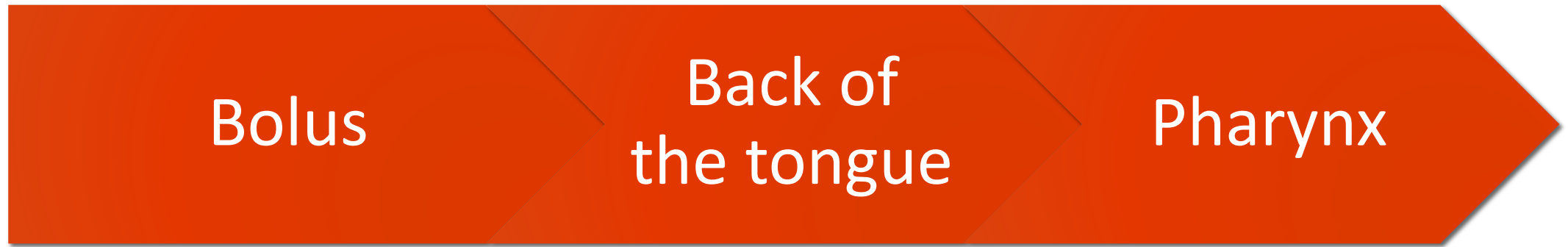Oral preparatory Phase.

- It occurs before the bolus enters the mouth.
- Levels of alertness, hunger motivation or food thoughts affect this stage.

!!!!!!!Time to think!!!!!!!

- How can Alzheimer's disease affect?
- How the inability to look at food (for whatever reason) Can affect the stage?

II: Oral Stage:



- Coordination between muscles

- Saliva

The length of the oral phase varies depending on the bolus.

- For 10 ml of liquid – half a second

- For a solid bolus - up to 20 seconds.

- Swallowing apnea

III: The pharyngeal stage:

Consists of many neuromuscular events synchronized with each other

Transport of material away from oropharynx, to the hypopharynx into the upper esophagus

-
- Three of the four pressure valves operate at this stage, together with the first valve operating at the oral stage: a lip sealing valve, which works together with the tension created in the cheek muscles to increase the pressure in the oral cavity.
 - With the help of all 4 valves together, the oropharyngeal cavity builds a high positive pressure which will direct the bolus and advance it towards the esophagus, where there is a relatively low pressure.

-
- **Velopharyngeal closure valve:** separates between the oropharynx and the nasopharynx , prohibit the air to escape from the open nasal cavity to the oropharynx, by lifting the soft palate and contracting the posterior pharyngeal walls in the nasopharynx area.
 - **Laryngeal valve:** includes closure of the VF, bending of the epiglottis. Together, close the opening to the lungs and therefore raise swallowing pressure.
 - **The cricopharyngeus valve:** a muscle that becomes loose during swallowing and creates negative pressure when opened to pull the bolus down towards the esophagus.

This stage starts with the move of the hyoid forward and up.

The phase ends with the closure of the UES after the tailbone of the bolus has passed through it (towards the esophagus).

Despite the complexity of the stage and the different events that occur, the pharyngeal phase lasts an average of 0.8 seconds.

-
- Transferring the food to the pharynx and from there to the esophagus. The swallowing reflex is activated
 - **6 involuntary actions occurring in one second :**
 - **Tongue** retraction and depression (forcing bolus into upper pharynx), then
 - **Mastication** ceases and **respiration** inhibited
 - Vocal folds close off the trachea
 - **Soft palate (velum)** elevates blocking the nasopharyngeal opening (VP port)
 - **Larynx** is pulled upward and forward
 - Depression of **epiglottis** protecting airway
 - **Cricopharyngeal muscle (pharynx muscle)** relaxes and bolus propelled into esophagus

-
1. Tongue movement
 2. Forcing of tongue root against the soft palate and posterior pharyngeal wall
 3. Velar elevation, preventing REGURGITATION
 4. Narrowing of hypopharynx
 5. Epiglottis dorsal and downward tilting by:
 - larynx
 - Contraction of floor of mouth
 - Elevation and posterior movement of hyoid bone

Triggering pharyngeal swallow

When bolus is propelled posteriorly, sensory receptors in the oropharynx and tongue are stimulated, sending sensory information to cortex and brain stem

Sensory recognition center in the medulla in the nucleus tractus solitarius receives sensory input

Information is sent to nucleus ambiguus

Pharyngeal swallow motor pattern is automatically triggered

If bolus head reaches the lower point of the root of the tongue with no initiation --> delay (Logemann, 1998, p. 30).

IV: Esophageal Stage:

Transfer of food from the esophagus to the stomach:

1. the Upper esophageal muscle (UES), is opened through the Cricopharyngeus muscle.
2. Peristalsis.
3. Time Length 3-20 seconds (depending on texture, bolus and age).
4. Breathing is renewed.
5. UES closes.

Esophageal Swallowing:

- Carrying of bolus from pharynx to stomach
- Done by two mechanisms:
 - **Gravity**
 - **Peristalsis**
- Usually, not the responsibility of the Speech Pathologist
- Consult a Gastroenterologist (GI)

Airway protection

1. False VF
2. Downward displacement of the epiglottis
3. Adduction of the true vocal folds
4. Stop breathing while swallowing
5. Exhale at the end of swallowing
6. Coughing

Normal swallowing

<https://www.youtube.com/watch?v=umnnA50IDIY>

<https://www.youtube.com/watch?v=pNcV6yAfq-g>

Reflexes (gag reflex):

- Sensory cells + motor
- It doesn't present in all people
- Bilateral injury in the brain stem → no excitation of the swallowing reflex.
- Unilateral swallowing → part of the swallowing process is damaged, but not all.

Dysphagia

- Dys ----abnormality. Phagia----eating
- Abnormality in the transfer of a bolus of swallowing from mouth to the stomach
- In all stages
- All stages
- Range from delay to absence of transfer; including misdirection (penetration)
- A symptom of an underlying neurogenic or mechanical (obstructive) disease
- May be **occult** or **overt**

Occult VS. Overt Dysphagia

Occult Dysphagia (Unrecognized)

- no complaint from patient, or
- well compensation from patient for the problem

Overt Dysphagia

- Difficulty chewing
- Difficulty in bolus preparation
- Excessive drooling
- Choking or regurgitation
- Food sticking at any level of the alimentary tract
- Painful swallow

Most significant if associated with aspiration pneumonia, weight loss, compromised nutritional status, or any combo

Definitions:

1) Oral Transit Time (OTT)

- The time taken from the initiation of the tongue movement until the bolus reaches the point where the lower edge of the mandible crosses the tongue base.
- OTT should not be more than 1 to 1.50 seconds. In people over 60, it increases by approximately 0.25 seconds.

2) Pharyngeal Delay Time (PDT)

- When the bolus reaches the point where the lower edge of the mandible crosses the tongue base and ends when laryngeal elevation begins.

3) Pharyngeal Transit Time (PTT)

- The time elapsed from the triggering of the pharyngeal swallow until the bolus passes through the CP Region.

Symptoms:

- Difficulty recognizing food
- Difficulty of food placement in the mouth
- Difficulty controlling food or saliva in the oral cavity - food is scattered throughout the mouth after swallowing, difficulty forming a cohesive bolus.
- Cough before, during or after swallowing
- Cough at the end or immediately after a meal
- Choking
- Recurrent pneumonia
- Rise of fever due to inflammation of the lungs

-
- Wet sound (change in resonance) after swallowing, at the end of the meal or immediately afterwards (the bolus in contact with the vocal cords)
 - Outflow of food from the nose
 - Patient complaints about food that gets stuck in the mouth / "throat"
 - Difficulty chewing
 - Salivation
 - Lack of arousal of the swallowing reflex
 - Weight loss without a definite cause
 - Swallowing pain

-
- Decreased sensitivity (quiet aspiration - passage of the bolus through the vocal cords without a cough response; difficulty in feeling the remnants of the pharynx after swallowing)
 - Fatigue during the
 - Lack of awareness of swallowing problems (Parkinson)

Complications:

- Medical complications:
 - Pneumonia as a result of aspiration
 - Can lead to death
- Malnutrition
 - Difficulty in healing, wounds
 - Decreased immune system function
 - Weakness and tiredness
 - Dehydration
- Quality of life
- Impairment of social ability (difficulty eating in society)
- Depression

Aspiration and penetration

- Aspiration - Food reaches the windpipe
- Penetration - food reaches the part above the vocal cords (glottis)
 - Can occur before / during / after excitation the swallowing reflex.
 - Effective cough
 - Ineffective cough
 - late cough
 - immediate cough
 - Silent Aspiration - No cough

-
- Aspiration is defined as the residual, unswallowed pharyngeal content that is drawn into the larynx and trachea by inspiration after an attempt of a normal swallow
 - Penetration is the spillage of oral contents into the pharynx, larynx, or both without elicitation of swallow

Clinical symptoms of aspiration and penetration:

- Cough or choking before / during / after swallowing
- Wet voice
- Pneumonia
- Increased fever
- Repeated swallow
- Clearing
- Change in facial color
- Change in breathing

Disease or symptom:

- It is important to distinguish between:
 - Illness - disease or condition
 - Stroke, injury to the cervical vertebrae, Parkinson's
 - Symptoms - easier to diagnose (can be seen in the clinical and instrumental examination)
 - Physiology behind the symptom (the cause of the symptom) - more difficult to distinguish (usually requires an instrumental assessment)

-
- It is important to differentiate symptoms from anatomic or neuromuscular dysfunctions.
 - Symptoms determined clinically and radiographically alert the clinician that the patient's swallowing is disordered, and point toward the nature of the dysfunction.
 - The anatomic and/or neuromuscular dysfunctions are the actual disorders leading to the symptoms for which treatment is designed.

For example :

Aspiration is a symptom of a variety of disorders, not disorder itself.

Problems in various stages

Oral preparatory phase and Oral phase

- Structural problems
- Problems with muscle activation
- Problems with excretion of saliva
- Sensory problems

- **Reduced Lip Closure.**

- **Reduced Labial/Facial Muscle Tension/Tone**

- **Reduced Mandibular Movement:**

- The inability to align teeth due to surgical removal of part of the mandible.

- **Reduced Buccal Tension:**

- When material falls into the lateral sulcus.

- **Reduced Tongue Coordination (Can't Hold a bolus).**

- **Reduced Tongue Lateralization:**

- The inability to lateralize or move food with the tongue.

- **Reduced Tongue Elevation:**

- The inability to crush/mash food against the palate as a compensatory technique.

- (Incomplete Tongue-Palate Contact) ➔ Residue on Hard Palate

- **Reduced Tongue Control:**

- When material falls to the floor of the mouth.

- **Reduced Lingual Shaping and Fine Tongue Control:**

- When the tongue fails to elevate one or both sides to form a central groove to contain the food.

- **Tongue Thrust (Abnormal Hold Position)**

- **Tongue Scarring and Scarred tissue can't elevate or move (oral cancer).**

-
- **Repetitive Lingual Rocking (Parkinson's Disease)**
 - **Residue on the Floor of the Mouth during Oral Transit**

Apraxia of Swallow (Searching Tongue Movement)

- Exhibits good range of motion but inability to organize the front to back lingual and bolus movement normally characteristic of a swallow.
- Refraining from giving any commands to swallow can also be helpful, because Apraxia is usually worse when the target activity becomes highly volitional.

Apraxia of Swallow (Reduced Oral Sensation → Delayed Oral Onset of Swallow)

- Severe neurological impairments cause patients to hold bolus in mouth with no lingual movement.
- Increasing the pressure of the spoon on the tongue, using a cold or larger, or stronger tasting bolus, as the bolus is presented, might increase sensory stimulation.

Oral Phase

- Reduction in tongue motility or difficulty in coordination
- Difficulty in moving the bolus from the front of the mouth back
- Bolus residue in the oral cavity after swallowing
- Bolus residue on the floor of the mouth
- bolus residue on the tongue
- bolus residue on the hard palate
- Search movements of the tongue / disorganized contraction movement

Oral Phase

- Leakage from the mouth into the oropharynx is prevented by apposition of the soft palate and the posterior portion of the tongue blade.
- Incompetence of this seal results in premature leakage into the oropharynx before initiation of swallowing, with potential for entry into the open, unprotected larynx.

-
- Defect in the initialization of the tongue movement:
 - Repetitive rocking-rolling movements of the tongue: a symptom specific for Parkinson's disease (in some patients). Repetitive back and forth movements of the front of the tongue while the back of the tongue remains elevated to create a seal between the back of the tongue and the palate. The front of the tongue demonstrates repetition of the movement in an attempt to stimulate the onset of the oral transfer phase.
 - Bolus residue in the oral cavity after swallowing

Pharyngeal stage disorders:

- Regurgitation - the passage of food into the nasal cavity (adding to it coordination in the pharyngeal shrinking)
- Delay in the pharyngeal swallow
- Long transit time
- Difficulty moving the base of the tongue back toward the posterior pharyngeal wall
- The transmit of the bolus to the pharyngeal cavity before excitation of the pharyngeal swallow
- Absence of swallowing reflex
- Weakness in the pharyngeal muscles
- Difficulty moving the hyoid and the larynx forward
- Deficit in the Vocal cords closure
- Pharyngeal peristalsis
- Difficulty opening the UES

- **Unilateral Vallecular Residue:**

It indicates dysfunction of one side of the tongue base or the pharyngeal constrictors.

- **Unilateral Dysfunction of Pharynx:**

Residue in one pyriform sinus due to neurologic or structural damage.

- **Reduced Vocal Fold Adduction:**

May indicate vocal fold paralysis and therefore aspiration occurs.

Disorders in Triggering Pharyngeal Swallow: Transition between Oral and Pharyngeal Stages

Delayed Pharyngeal Swallow

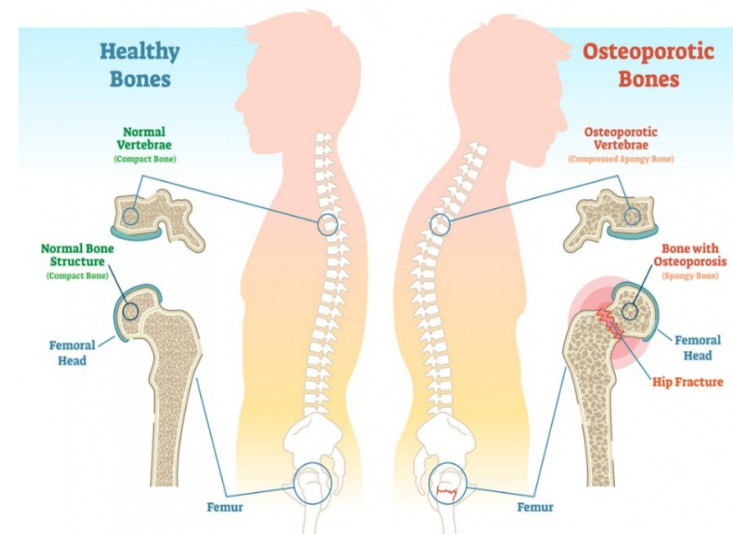
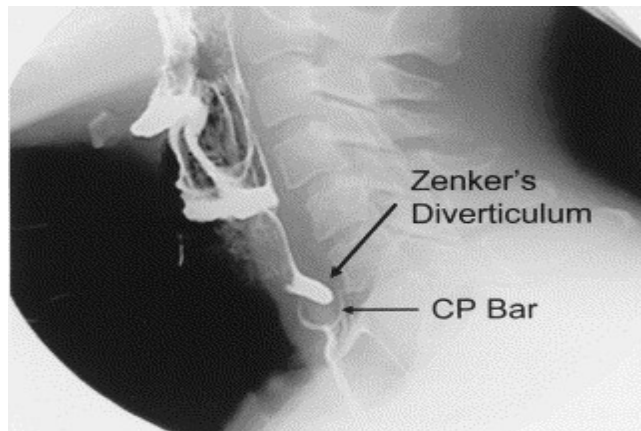
- Increased risk of aspiration, and difficulty in swallowing liquids. During the delay in pharyngeal swallow, the pyriform sinuses fill with food or liquid, as the pharynx and larynx are elevating, and the contents will be at high risk of being dumped into the airway.
- The chin-down posture might be helpful.
- The sphincter is not opening because the swallow center (brainstem: medulla) did not program it to open (i.e. the entire pharyngeal swallow has not been triggered).

Disorders in Triggering Pharyngeal Swallow: Transition between Oral and Pharyngeal Stages

Timing the Pharyngeal Delay

- During the delay, many patients struggle to stimulate a swallow, and move their tongue base forward and backward and lift the larynx up and down. These movements are not the same as those seen during pharyngeal swallow. Any laryngeal movements prior to the actual pharyngeal swallow should be considered part of the delay (elderly).
- A delay of more than 2 seconds during which aspiration occurs is considered abnormal regardless of age in adults.

-
- **Crico-pharyngeal bar (CP bar):** Protruded in the area of the junction between the pharynx and esophagus as a result of fibrosis of the cricopharyngeus (i.e. a structural change).
 - **Zenker's Diverticulum**
 - **Cervical Osteophytes**



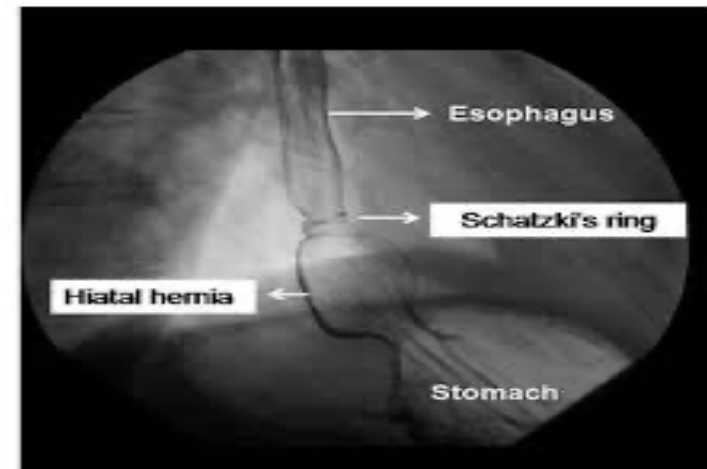
Reflux

- **Gastroesophageal Reflux – GERD (esophageal)**
 - Gastro-esophageal reflux may be manifested by symptoms referred to the pharynx, such as hoarseness, a lump in the throat, or pain in swallowing, and not by the classic symptoms.
 - It is becoming increasingly apparent that a broad spectrum of diseases can result from gastro-esophageal reflux.

- **Laryngopharyngeal Reflux - LRP**

Esophageal stage:

- LES opening dysfunction
- Food residues in the esophagus - a problem with peristalsis
- Schatzki's Ring : circular band of mucosal tissue that can form at the end of the food pipe closest to the stomach. The **ring** of tissue causes the food pipe, or esophagus, to narrow. When a **ring** forms, a person may have no symptoms. Or, they may have difficulty swallowing.



Evaluation of swallowing disorders

- Screening
- Questionnaires and scales
- Bed Side Evaluation
- Radiographic study (instrumental study)

Evaluation

- The main goal is to decide if the patient can continue to eat orally safely, or that s/he needs an alternative way of feeding.
- Anamnesis.
- Patient's observation.
- Voice and speech.
- Oral motor examination.
- Gag reflex stimulation.
- Different textures.

Two questions to be answered:

Two questions to be answered:

1- what type of nutritional management is necessary?

2- should therapy be direct or indirect ?

Suspicious signs of aspiration:

- Cough.
- Gurgling voice.
- Delay or absence of the swallowing reflex.
- Lingual movement.
- Significant difficulty in tongue movements before swallowing – food may split backwards.
- Tiredness' of the patient.
- Fever.

Suspicious signs of aspiration:

- Difficult cognitive problems
- Coughing after aspiration
- Fast eating and in large quantities
- Food residue in mouth as a result of dementia for example
- Tracheostomy

Screening Procedures

- Provide the clinician with some indirect evidence that the patient has a swallowing disorders

- Do not provide information on the physiology of that disorder.

Screening Procedure

- Identify the sign and symptoms of dysphagia
- Performed at the patients bedside or in a home or school environment
- Indicate if the patients needs and in-depth physiological assessment

Screening procedure

- May be limited to chart review and observation of each “orally fed, saliva management “.
- Should be quick, low risk and low cost.
- Its purpose is to identify high risk patients.
- Use check list (in table 5-1 page 137).

Screening procedure

Two characteristics are examined:

- Identify those individuals who are aspiring or have residue (true positives) and who true negative (no aspiration, no residue).
- The procedures should not generate many **false positives** (those who are identified as aspiring but not actually aspiring) or **false negative** (those who are aspiring but are not identified as such).

Screening procedure

- Infants, children and developmentally delayed adults have certain abnormal behaviors observed during eating which entail an in-depth physiologic study:
 - Rejection of food
 - Food selectivity
 - Gagging
 - Open mouth posture

The bedside or clinical examination.

- Designed to provide the clinician with the following data
 - Medical history and medical diagnosis
 - Pt's medical status
 - Pt's oral anatomy
 - Pt's respiratory function and relation to swallow
 - Pt's labial control
 - Pt's lingual control

-
- Palatal function
 - Pharyngeal wall contraction
 - Laryngeal control
 - Pt's general ability to follow directions, monitor and control his behavior
 - Pt's reaction to oral sensory stimulation and symptoms during attempts to swallow

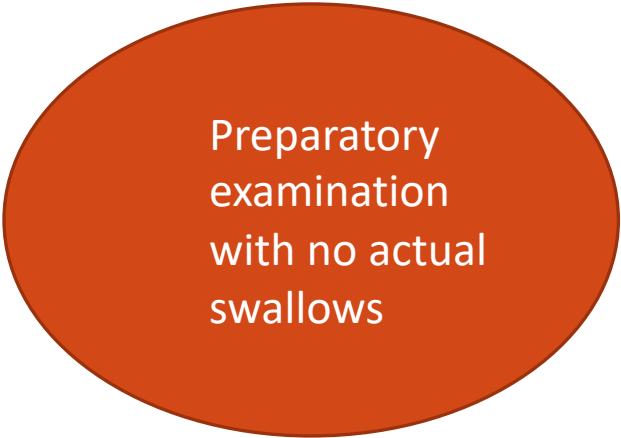
-
- Diagnosis
 - Neurological examination
 - Respiratory status
 - Nutritional status
 - Dysphagia, symptom, history

Major concerns:

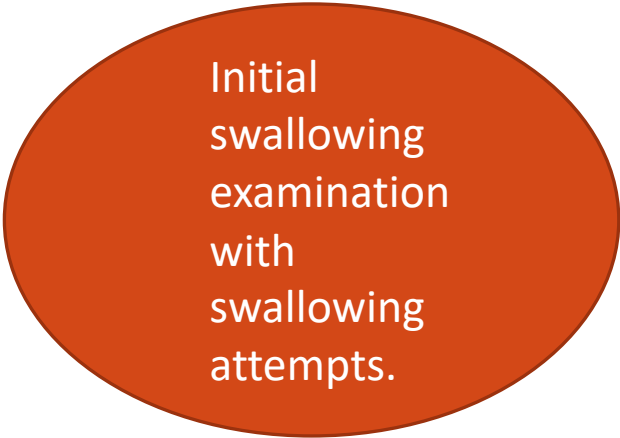
1. Mental Status
2. Nutritional status
3. Respiratory status

The bedside or clinical examination

Divided into two parts:



Preparatory
examination
with no actual
swallows



Initial
swallowing
examination
with
swallowing
attempts.

Preparatory examination

- Collection of information from the patient's charts
- Complete examination of vocal tract control.

Patient chart review

- Examine the patient's medical chart to determine pt's respiratory status (pneumonia, presence of tracheostomy tube)
- History of mechanical ventilation and intubation
- History of swallowing problem, "duration"
- Motivation (pt's ability to follow directions)
- General behavior
- Nutritional status "oral feeding vs nonoral nutrition and type".

Patient chart review

Should also identify:

- Current and past medical problems may cause dysphagia.
- Current past immediate past medication causing dry mouth (xerostomia)
- History of the swallowing disorders “time, nature of onset symptoms”
- Present, type, duration and method of placement of any ventilation (tracheostomy): type, duration of placement, adequacy
- Complication of oral and non-oral nutrition.

Observation upon entering the patient's room

Should be observed:

- Pt's posture
- Present or absence of a tracheostomy tube
- General awareness

Respiratory status

Observation of respiratory rate

- The timing of the patient's saliva swallow in relation to the phases of the respiratory cycle.
- The timing of any coughing in relation to respiratory-swallow coordination.
- The duration of comfortable breathing.
- The patient's rest breathing pattern, oral vs. nasal.

History

- When did the disorder begin ?
- Did it get worse gradually or rapidly?
- How does the problem vary with different consistencies of food?
- What specifically happens when the pt. tries to swallow?

History

The swallowing therapist may have information:

- The localization of the disorder in terms of the oral or pharyngeal stages of swallowing or both.
- The easiest and most difficult types of material for the pt. to swallow.
- The nature of the swallowing disorders.

We have to do:

➤ Anatomical assessment

➤ Functional assessment

❖ Lips

❖ Tongue

❖ Soft palate

❖ PTK

❖ CN

❖ Oral reflexes

❖ Oral sensation

❖ Laryngeal function exam

❖ Volitional cough & swallow

The examination of oral anatomy (anatomical examination)

- Observation of lip configuration, tongue, hard palate, soft palate and uvular
- Any scarring in the oral cavity.
- The dentition status
- Oral secretion (mouth moist or dry)

Functional assessment

1-Oral motor examination

- include evaluation of the range, rate and accuracy of movement of the lip, tongue, soft palate and pharyngeal wall during speech reflex activity and swallowing.

2-Ability to open the mouth voluntarily

- The voluntary mouth opening is difficult and slow(3-5min)→ neurological impairment.
- The pt benefit for bedside assessment with oromotor stimulation rather than immediate radiographic study.
- The radiographic scheduled when the pt is able to open the mouth more easily.
- If a bite reflex is present using gauze roll to prevents pt breaking a tooth .

Functional assessment

3-Identification of optimal oral-sensory stimuli and bolus types

- Some pt's. Produce oral activity in response particular combinations of taste, textual, and temperature
- To present various textures in the pt's mouth
- Use 4X4 pieces of cloth, rolled around a straw
- One end of this rolled materials can be dipped into liquid of various temperature.
- These stimuli (mixed with barium) can then be introduced as one of the boluses during x-ray.

Functional assessment

4-Identification of and compensation for swallowing apraxia

- A pt. with swallowing apraxia usually performs best with bedside evaluation with no verbal directions are given.
- Pt during x-ray exam. Pt. has severe difficulty initiating the oral stage of swallow. **why?**
- If the pt. shows apraxia and no symptoms of any other swallowing disorders → a radiographic study is not needed.

Functional assessment

5- Identification of and compensation for abnormal oral reflexes.

- Some pts exhibit abnormal oral reflexes (hyperactive gag, tongue thrusting or tonic bite).
- These abnormal reflexes are counterproductive to acceptance of food in mouth and production of normal swallowing (can be identified at bedside).
- Identification of the location in mouth where reflexes are triggered important to avoided during x-ray.

Functional assessment

- Labial function.
- Lingual function.
- Chewing function.
- Soft palate function and oral reflexes.
- Oral sensitivity examination.

Labial Function

- Pt spread the lips as widely as possible/I/.
- Pt rounds the lips/u/.
- Rapidly the previous posture /I/,/u/ *10
- Repeat /pa/.
- Observe the pt's labial closure during rest and during saliva swallowing.
- Pt. repeat sentences that include labial sounds.

Lingual function

Anterior tongue examination:

- Extend the tongue out and retract it.
- Move tongue right and left.
- Clear lateral sulcus on each side of the mouth.
- Open the mouth widely with elevate tongue tip.
- Repeat /ta/.
- Repeat a sentence with tip-alveolar stop consonants.

Lingual function

Posterior tongue function:

- Open mouth and say /k/ and hold elevated in this position for seconds.
- Repeat /ka/.
- Repeat sentences contain velar sounds, **such as?**

Chewing function

- Done with gauze for safety.
- Food is not recommended for bedside why?
- Gauze pad rolled and one end dipped into a pleasant tasting liquid then placed in the midline of pt's tongue.
- Pt then is asked to chew the gauze (which is flexible but cannot be lost in the mouth).

Soft palate function

- Sustain /a/ for several seconds.
- Palatal and gag reflexes should be tested.

Oral sensitivity examination

With cotton swab the clinician can make light contact at various points along the tongue, to determine the pt's awareness of light touch.

Management of information collected from oral examination

- The result of labial assessment should identify any facial paralysis and any problem the pt. may have maintaining lip closure when food is placed in the mouth.
- lingual function examination identifies any limitation in the tongue function that may effect ability to propel food posteriorly or hold food.
- Identification impairments of tongue function will help the clinician to select the material that the pt. can best manage

Laryngeal function examination

- Assess voice quality.
- Hoarseness voice, why?
- Assess cough and throat cleaning.

Management information to be collected from the laryngeal examination

- Assess laryngeal function in swallowing disorders
- If laryngeal function appeared to be borderline, the clinician should teach the pt. the supraglottic swallow to increase the pt's airway protection period to initiate any swallowing.

Pulmonary function testing

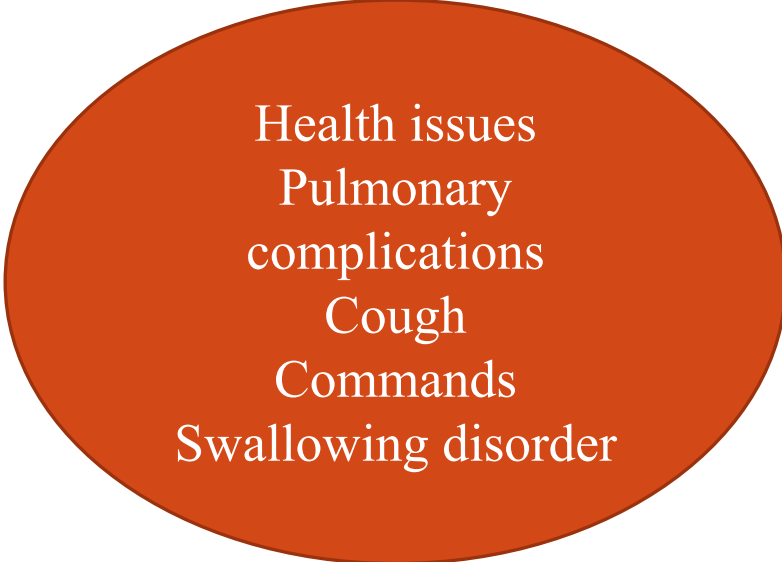
- Pts who are observed to aspirate on a radiographic study have been found at high risk for developing pneumonia in the next 6 months than pts. who exhibit no aspiration.

Information collected from the preparatory examination

1. The posture that may result in the safest swallowing.
2. The best position for food in the mouth.
3. The potentially best food consistency.
4. Some identification of the nature of the pt's swallowing disorders .

Should trial swallows at the bedside be attempted ?

- The therapist must look at all aspects of the pt's function and determine the best course of action in regard to trail swallows.



Health issues
Pulmonary
complications
Cough
Commands
Swallowing disorder



Risk & Benefit

Should trial swallows at the bedside be attempted

If pt. is being orally fed, the clinician should observe feeding to note

- (1) Pt's reaction to food.
- (2) Oral movements in food manipulation and chewing.
- (3) Any coughing, throat clearing, or struggling behaviors or changes in breathing and their frequency relative to swallowing and their occurrence during the meal(beginning, middle or end).

-
- (4) Changes in secretion levels throughout the meal.
 - (5) Duration of meal and total intake.
 - (6) Coordination of breathing and swallowing.

Utensils to be used in the initial swallowing evaluation

The clinician should bring a number of utensils into the pts room for the swallowing evaluation. These include:

- 1) A size 0 or 00 laryngeal mirror.
- 2) A tongue blade for wiping material onto the posterior tongue.
- 3) A cup to give the patient a small measured amount of material.
- 4) A spoon for presenting liquids and paste material.
- 5) A straw to be used as a pipette for placing liquid in the back of the mouth.
- 6) A syringe to squirt small amounts (1 ml) of liquid into the posterior oral cavity.

Observations during bedside trial swallows

-
- ✓ The index should be lightly positioned immediately behind the mandible anteriorly, the middle finger at the hyoid bone, the third finger at the top of the thyroid cartilage, & the fourth finger at the bottom of the thyroid cartilage.
 - ✓ In this way the submandibular, hyoid, laryngeal movement can be assessed during swallowing.

The index finger

- ❖ Assesses initiation of tongue movement.

The middle finger


- ❖ Perceives the hyoid bone movement.

The third, and fourth fingers

- ❖ Define laryngeal movement when the pharyngeal swallow triggers.

Limitation:

if the pharyngeal swallow does not trigger in a normal length of time (less than 1 sec.), the clinician at the bedside cannot assess what is occurring physiologically during the time delay.




The clinician can follow the initial swallow with a swallow preceded by thermal-tactile stimulation to assess the differences in timing as a result of the thermal-stimulation.

Helpful in assessing aspiration:

The pt. is asked to phonate “ah” Immediately after the swallow, for several seconds. **Why?**




The pt. is asked to pant (breath heavily) for several sec., so that material residing in the pharyngeal recesses (valleculae or pyriform sinuses) is shaken loose to fall into the esophagus.



After panting the pt. should be asked to vocalize again. **Why?**



The pt. should turn the head to each side & ask him/her to vocalize with the head turned to each side. This head rotation results in forming pressure on each pyriform sinus & may squeeze any residual material from the pyriform sinus into the pharynx causing voice to become gurgly.



If the voice is clear—then ask him/her to lift the chin up & hold it there for a few seconds, then vocalize again. This posture will cause the tongue base to push on the valleculae & result in clearing material from the valleculae which may then cause a gurgly voice.

If the pt. coughs during any part of this sequence, or if gurgling vocal quality is heard, aspiration can be suspected.

Types and Amounts of Materials Used

✓ **Why do we begin with liquids???**

- ❖ Ensures that material will not block the airway, if aspirated.
- ❖ Pneumonia is less likely from aspiration of liquids than from aspiration of thicker foods.
- ❖ Lungs are able to clear liquids from tracheobronchial tree by a cough.

➤ **Water Swallow Test**

❖ 3 oz Water Swallow Test

❖ Give patient 150ml water to drink uninterrupted from a cup

❖ Observe for 1 minute after the swallow • Coughing

❖ Wet/Hoarse Vocal Quality

➤ **Eat – 10**

➤ **The Dysphagia Outcome and Severity Scale - DOSS**

➤ **Dysphagia Handicapped Index**

Choice of a certain technique depends on the patient's age, language cognition, and medical diagnosis

1- Imaging Procedures

2- Non-imaging Procedures

Imaging and non-imaging tests and more

- Assist in diagnosis mainly in situations where it exists Aspiration and we do not know exactly why.
- Identify silent Aspirations
 1. Video Fluoroscopy (VF)
 2. FEES - Fiberoptic endoscopic evaluation of swallowing
 3. US - Ultra Sound
 4. Manometry
 5. Cervical Auscultation - Listen to swallowing with Stethoscope
 6. EMG - Only for research purposes

IMAGING PROCEDURES

Ultrasound: examines

- Tongue function
- Oral transit time
- Motion of the hyoid bone

Disadvantage: inability to visualize the pharynx, because of the mix of tissue (cartilage, bone and muscle)

US

- Use the ultrasound device that is put under the chin - below the floor of the mouth muscles.
- See the movement of the hyoid during swallowing.
- You can see how many attempts the patient has to make, till s/he can swallow.

Advantages

- Non-invasive
- No radiation
- Appearance of soft tissues
- Dynamic testing
- Good for checking the function of the tongue
- Can be used with different textures
- Measures the time of the oral phase
- Good for use with children
- Enables biofeedback

Disadvantage

Very partial

Scintigraphy

- Nuclear medicine test.
- The patient swallows radioactive materials
- Swallows are imaged and recorded using a gamma camera examines.
- Esophagus for existence of GERD.

- Disadvantage: radioactive material!! Oral and pharyngeal stages are not imaged

Video-endoscopy (FEES)

- Flexible fiberoptic examination of swallowing.
- The main goal is to identify structural problems and cancer.
- It is done by entering a tube with a camera from the nose to above the vocal cords, and records the moment of swallowing
- Pharyngeal stage
- oral cavity and pharynx from above
- Larynx pre-post swallowing (Blue Die)

Advantages:

- No radiation: safety + a long test can be performed + repeat tests can be performed
 - Detects structural problems
 - Allows to look at the vocal cords
 - Available and mobile test
 - No need to add barium
 - Allows you to view the larynx, pharynx and palate and evaluate integrity and function
- Allows the determination of the impact of various compensation techniques
- Can be used as a tool for bio-feedback

Disadvantages:

- Invasive
- The closure of the epiglottis obstructs the observation of the swallowing moment
- Inability to visualize the oral and the esophageal Stages
- The swallow trigger
- Swallow physiology
- If Rigid scope is used, it will interfere with normal swallow, but good for testing swallow/breath maneuvers

Disadvantages:

- It is not possible to watch many biomechanical events:

The oral preparation phase and the oral transfer phase cannot be evaluated: creating a uniform bolus, transferring it from the front of the mouth to the back.

The movement of the hyoid during swallowing cannot be assessed - the esophageal stage (passage through the UES) cannot be assessed - the integrity of the tongue movement backwards towards the wall cannot be assessed

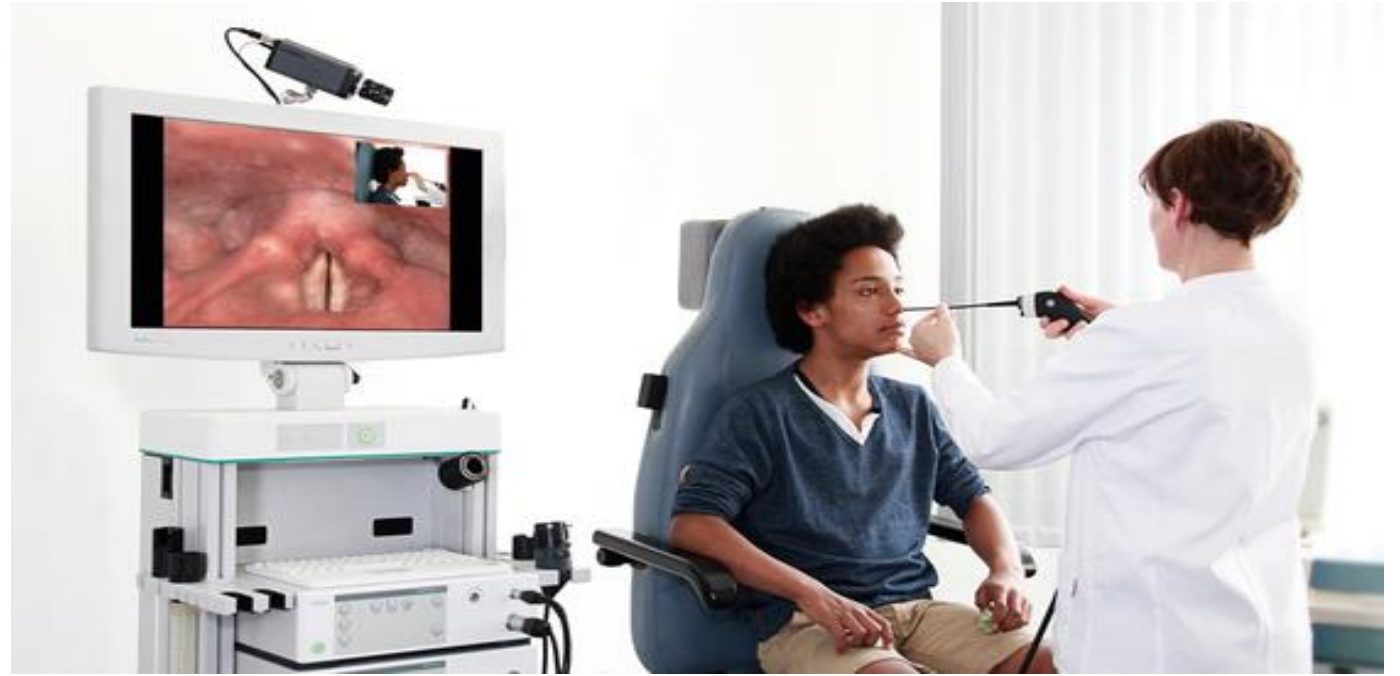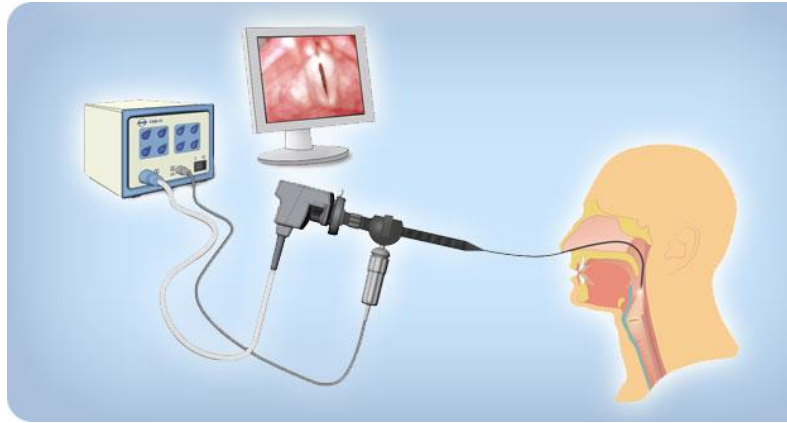
The pharynx at the time of swallowing

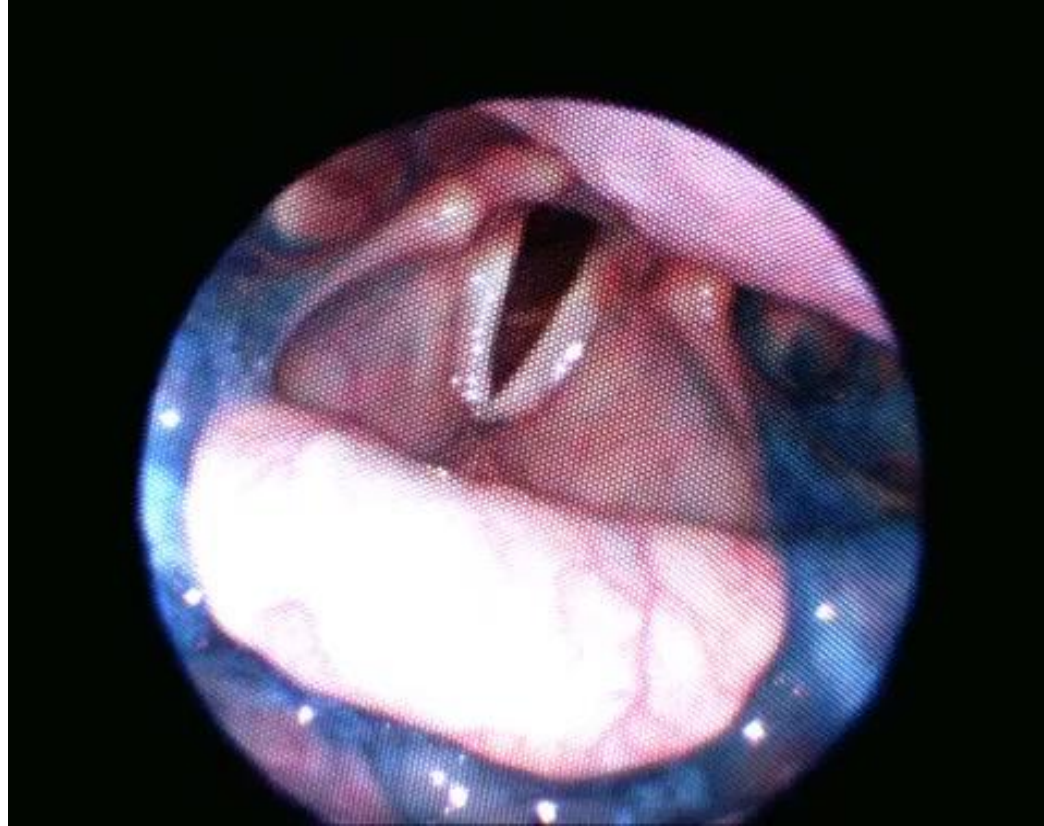Disadvantages:

Pathophysiology cannot always be assessed: for example, the cause of pharyngeal bolus accumulation before swallowing (delay in stimulus reflex? Difficulty in motor control during bolus preparation?)

May miss aspiration while swallowing - The movement of the pharynx and larynx during swallowing can not be assessed

The depth of aspiration penetration and the effectiveness of the aspiration reaction cannot be assessed

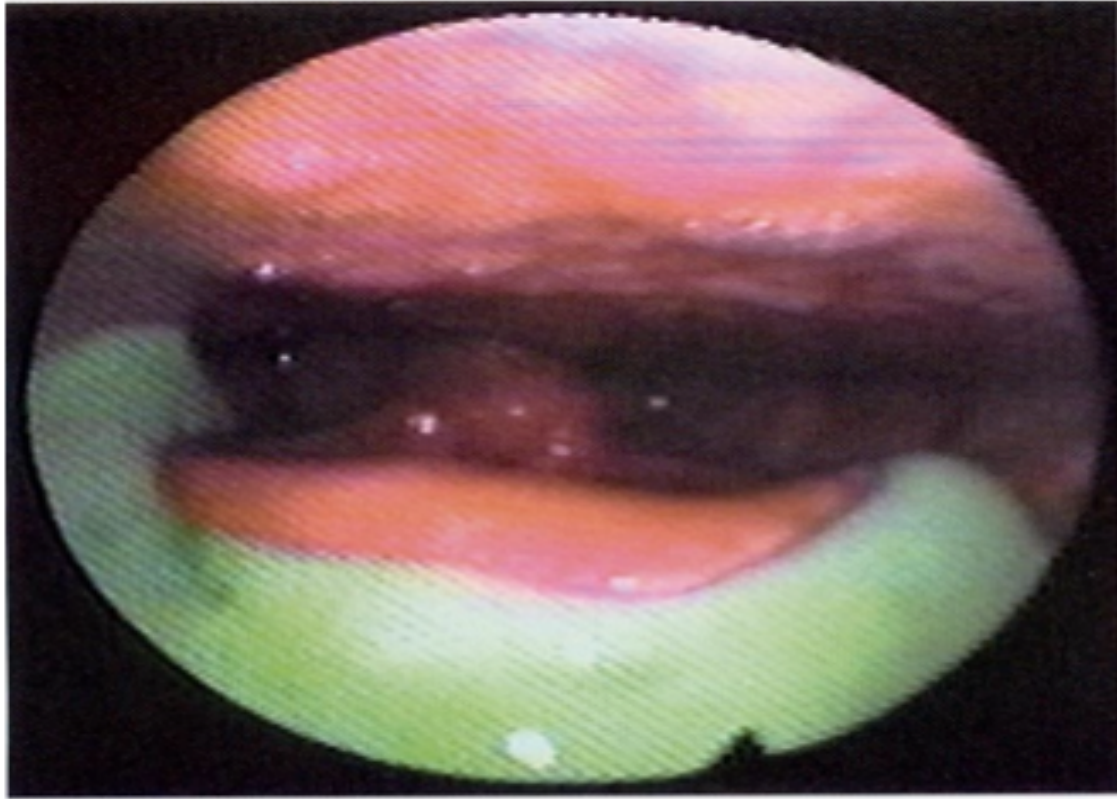




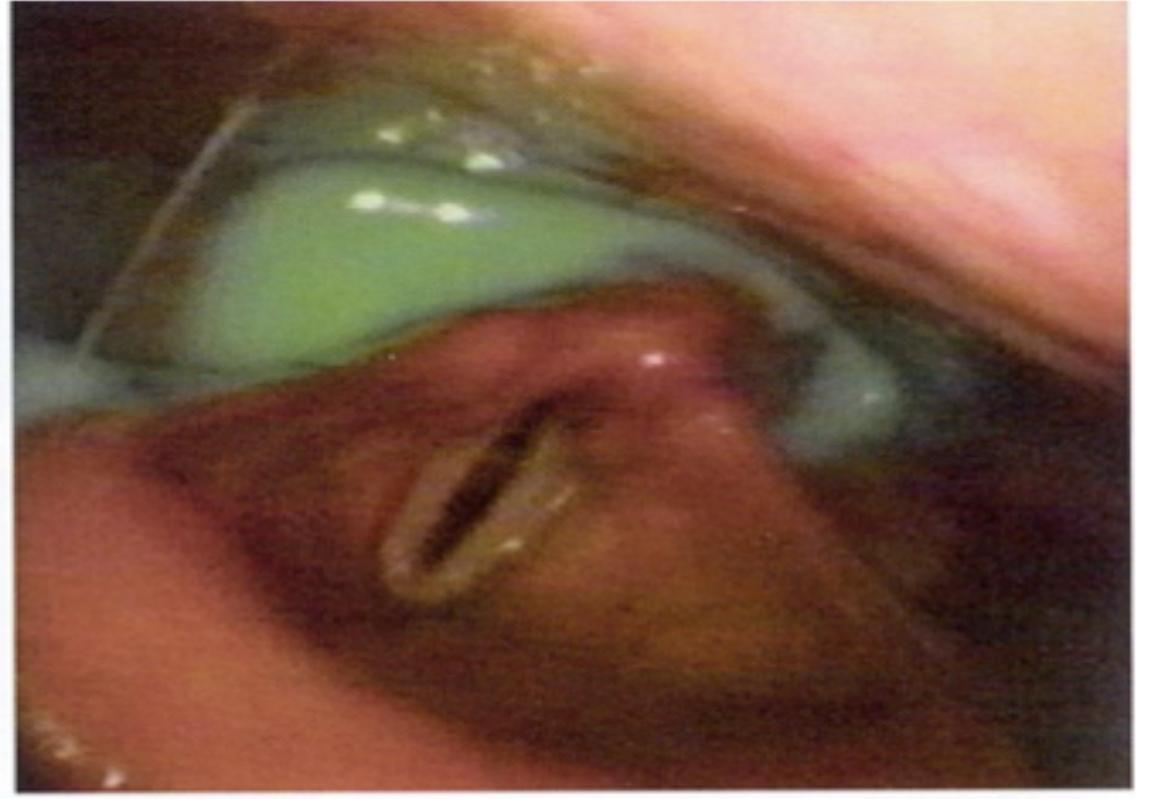
❖ spillage - Bolus falls over.

❖ Residue – Bolus is left in the hypopharynx after the swallow.

❖ Penetration – Bolus enters the laryngeal vestibule, over the rim of the larynx, above the true V.C.



COLOR PLATE 6-12. Two examples of spillage. **A:** On the left, liquid has spilled to the valleculae and is starting to de-



scend the lateral channels; **B:** On the right, liquid is resting in the pyriforms. See Figure 6-12, p. 117.

Video-fluoroscope (VF)

- The most common test
- Dynamic testing of the whole swallowing process
- Performance - Easy with a doctor who is knowledgeable about swallowing
- It is performed by a speech pathologist with a specialized swallowing doctor
- It is best to perform after a clinical diagnosis of the speech pathologist
- It takes 3-4 minutes
- Anterior or lateral view
- Fluids and solid
- High frequency of suspected aspiration

VF + Cinefluoroscopy:

- Radiographic recording of anatomical structures in motion.
- Examines:
 - ✓ The transfer of bolus through the oral cavity
 - ✓ Pharynx
 - ✓ Esophagus

Video-fluoroscopy:

Involves less radiation exposure

- Ability for frame to frame analysis
- More information on bolus transit time
- Detection of motility problems
- Detection of the amount and etiology of aspiration.
- Examines:
 - 1- oral activity during chewing and the oral stage of swallowing**
 - 2- triggering the pharyngeal swallow in relation to the position of the bolus**
 - 3- motor aspects of the pharyngeal swallow; movements of larynx, hyoid, tongue base pharyngeal wall, and cricopharyngeal movements**

-
- Swallow physiology is detected and recorded
 - For further examination in slow motion

Advantages

- Non invasive
- When / How / How many Aspirations occur
- Allows locating aspiration and penetration before, during and after ingestion
- Examines the motility of all the organs that are involved in the swallowing process
- Allows to test compensation strategies

Disadvantages:

- Exposure to radiation : limiting the time of the test, so the test only "samples" the swallowing function (difficulty in demonstrating the effect of fatigue)
- Requires cooperation
- Not suitable for checking the activity of the vocal cords
- Not suitable for diagnosis of structural pathologies
- No measurement of pressures generated during swallowing
- Salivation cannot be assessed
- Location: It is not possible to check patients confined to bed
- Consumes swallowing barium (changes in viscosity, allergies)

Who Does What?

- SLPs usually assess and modify the oral and the pharyngeal stage
- MDs diagnose and treat the esophageal stage
- SLPs, in cooperation with radiologists conduct a **Modified Barium Study (MBS)**:
 - ✓ Mixing Barium Sulphate (contrast material) with the three food consistencies (liquids, puree food, & solid food): 1,2,5, and 10 ml swallows

https://www.youtube.com/watch?v=xu_YYOAlZEw



What Can SLPs Do?

1. Postural techniques

(e.g. chin tuck, head rotated to the affected side, etc.)

2. Improving Oral Sensory Awareness (sour bolus, larger bolus, thermal-tactile stimulation)

3. Swallow Maneuvers : Mendelsohn Maneuver (increasing lx closure duration), effortful swallow, etc.

4. Food Consistency (Diet Changes): using puree foods for reduced laryngeal closure.

Referral to FEES is preferred over referral For VFSS under the following conditions:

- Demonstration of the larynx for signs of trauma, evaluation of the function of the larynx after surgery in the head-neck area, intubation
- Need to assess fatigue during a meal
- Need for a "conservative" test due to significant concern for aspiration of barium.
- Need for re-examination to evaluate change or to evaluate the effectiveness of different swallowing techniques
- Need to evaluate a large number of textures or need to evaluate a large number of techniques (which will take a long time) or need to use FEES as bio-feedback
- Very severe dysphagia with lack of cough reflex or very poor ability to tolerate any possible aspiration (poor pulmonary ability, poor general condition, poor immune status ..)
- Suspicion of difficulty in saliva management
- When the patient can not be sent to VFSS (limited mobility, can not sit, can not undergo radiation).

Referral to VFSS is preferred over referral to FEES under the following conditions:

- Unclear symptoms, need for a comprehensive assessment
- Demonstration of submucosal anatomy (osteophytes)
- Assessment of the preparatory, oral, base of the tongue to the wall of the posterior pharynx
- Evaluation of the UES - narrowing, lack of opening.

-
- The results of the clinical examination and the instrumental examination should support complaints.
 - Is the behavior observed in the VFSS or FEES test consistent with the other findings (clinical swallowing test, medical history, interview with the patient)?
 - If there is no match between the complaints and the findings, there is an indication to refer for further tests: for example:
 - FEES or VFSS –
 - There may be esophageal dysphagia (send to ent or gastro and then according to their recommendation - perform a barium swallow test that reviews the esophagus)
 - Neurologist

NON-IMAGING PROCEDURES

- Provide NO pictures
- Parameters such as pressure or electrical energy generated at specific locations

Electromyography (EMG):

- Placing two electrodes on the muscle in question to measure electrical activity

(it was found that type of bolus affects muscle activity duration)

- Two types:

1- Surface electrode EMG (placed on the skin: thyroid-roof of the mouth → laryngeal elevation)

2- Hooked-wire electrode EMGE (needles in muscles, e.g. superior pharyngeal constrictor activity)

-
- Surface EMG serves as a biofeedback mechanism:
 - ✓ The patient can monitor the timing and amount of laryngeal elevation during swallowing and Swallow Maneuvers (Mandelson, Effortful swallow etc..).
 - Hooked-wire EMG:
 - To study the pharyngeal wall activity during swallowing
 - ✓ Compare electrical activity of some muscles during speech and swallowing.

Electroglottography (EGG):

- Tracks laryngeal impedance (VF movement)
- Laryngeal elevation
- Biofeedback for patients

Cervical Auscultation:

- Listening to and recording sounds of swallowing
- The “Click-Clunk” Approach
- Using a microphone, we can listen to the:
 - ✓ **Click** of opening the Eustachian tube (initiating the swallow)
 - ✓ **Clunk** of the esophagus opening (end of pharyngeal swallow)

Cervical Auscultation:

- And the Sounds of Respiration
- Listening to respiration stoppage indicating the initiation of swallow
- Sounds of secretions pre-post swallow can be used as a screening procedure.

Pharyngeal Manometry:

- Placing pressure sensors (gauges) with a fast frequency response to detect the pharyngeal pressure changes
- Three sensors are attached to a 3mm nasal tube and placed:
 - ✓ Tongue base
 - ✓ UES
 - ✓ Cervical esophagus
- Usually conducted concurrent to videofluoroscopy

It allows:

- 1- Measurement of intrabolus pressure examination of the timing of pharyngeal contractile wave
- 2- Indirect examination of the relaxation of the cricopharyngeal sphincter (indicated by the drop in pressure of the sensor)

Disadvantages:

- Invasive
- Training required

Esophageal Manometry:

- Checks pressure differentials in the esophagus
- Performed by a gastroenterologist
- A tube is inserted from the nose into the esophagus and infuses water to the esophagus
- The instrument performs a measurement using a tube located in the esophagus
- Dangerous for patients with aspirations

What to Choose?

The appropriate instrumental procedure, based on the information needed for each patient.

The swallowing examination of a patient with tracheostomy

Tracheostomy tubes, Intubation, and mechanical ventilation

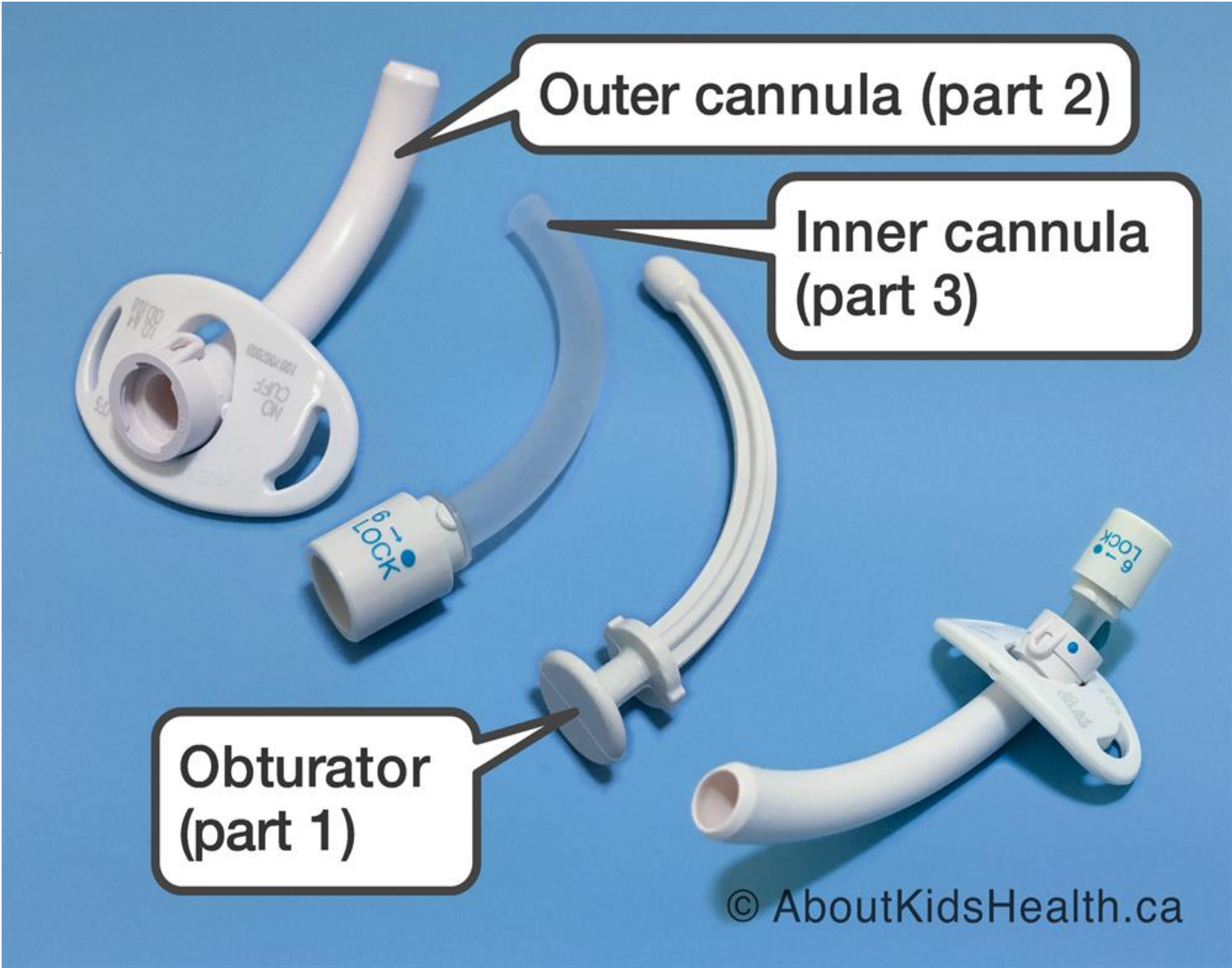
Tracheostomy tubes are normally placed in cases of

- Upper airway obstruction at or above the level of the true vocal folds
- Potential upper airway obstruction (edema, surgeries)
- Provision of respiratory care

Tracheostomy tube

General have three parts:

- Outer cannula (stay in place to hold tracheostomy suture open).
- Inner cannula (remains in the tube except for cleaning)
- Obturator (provide a smooth, rounded tip for initial insertion of the tracheostomy)



Outer cannula (part 2)

Inner cannula (part 3)

Obturator (part 1)

© AboutKidsHealth.ca

Tracheostomy tube

Two important variations in tracheostomy tubes

- Cuffed or uncuffed “respiration”
- Fenestrated or unfenestrated (speech)

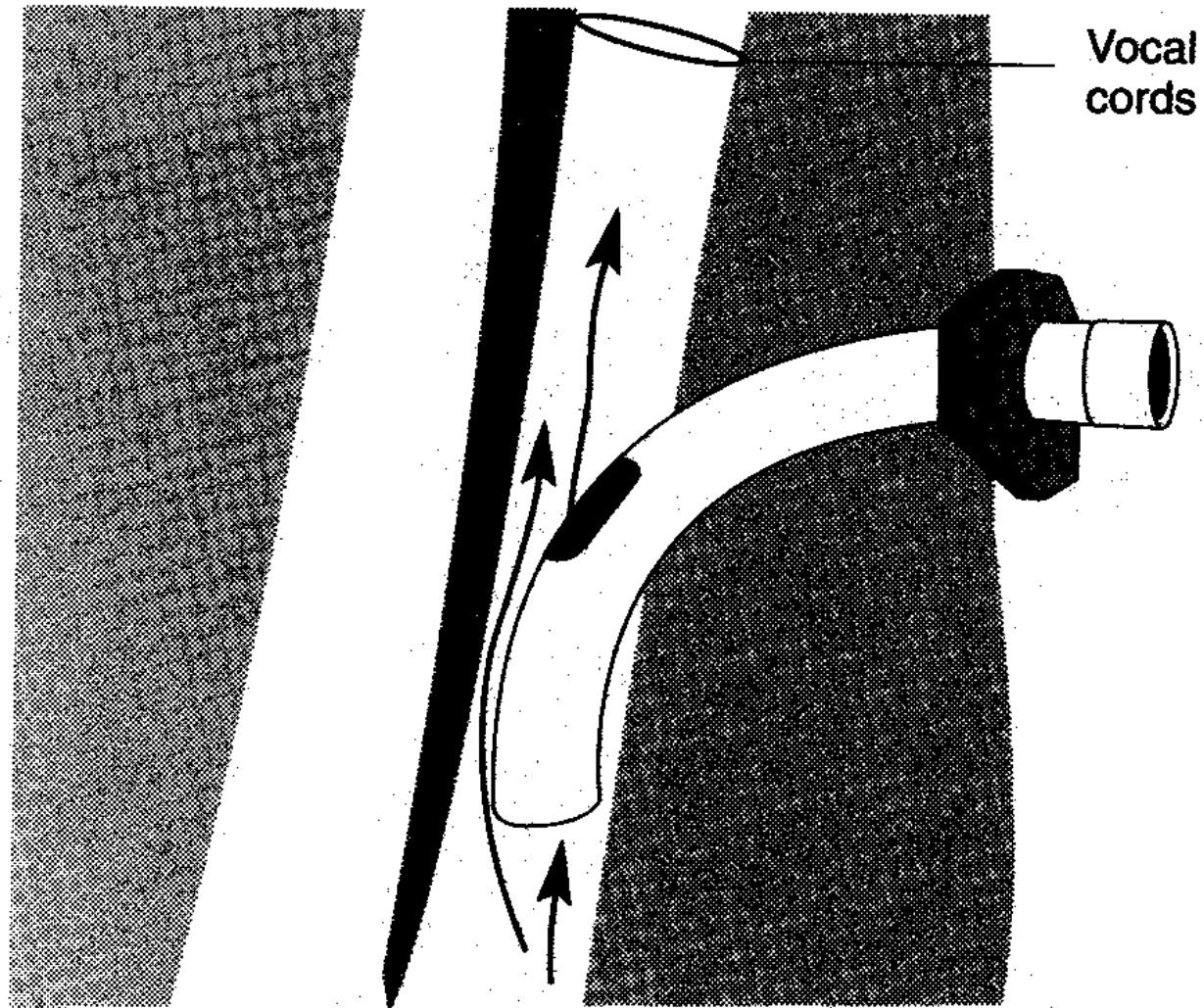


Figure 3-13. A fenestrated tracheostomy tube in situ. Airflow passes through the single fenestration.

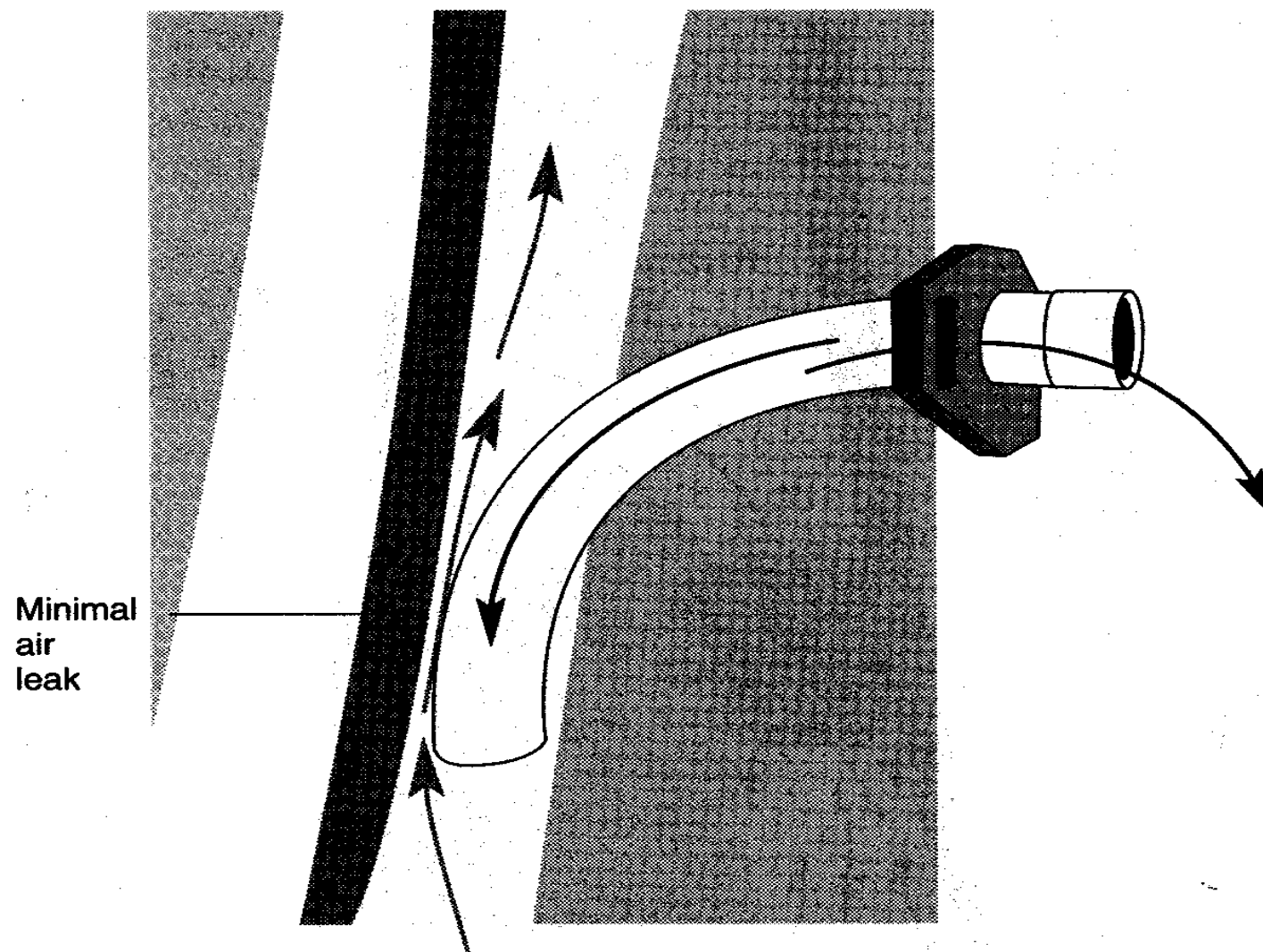


Figure 3–25. Redirection of airflow following placement of a tracheostomy tube.

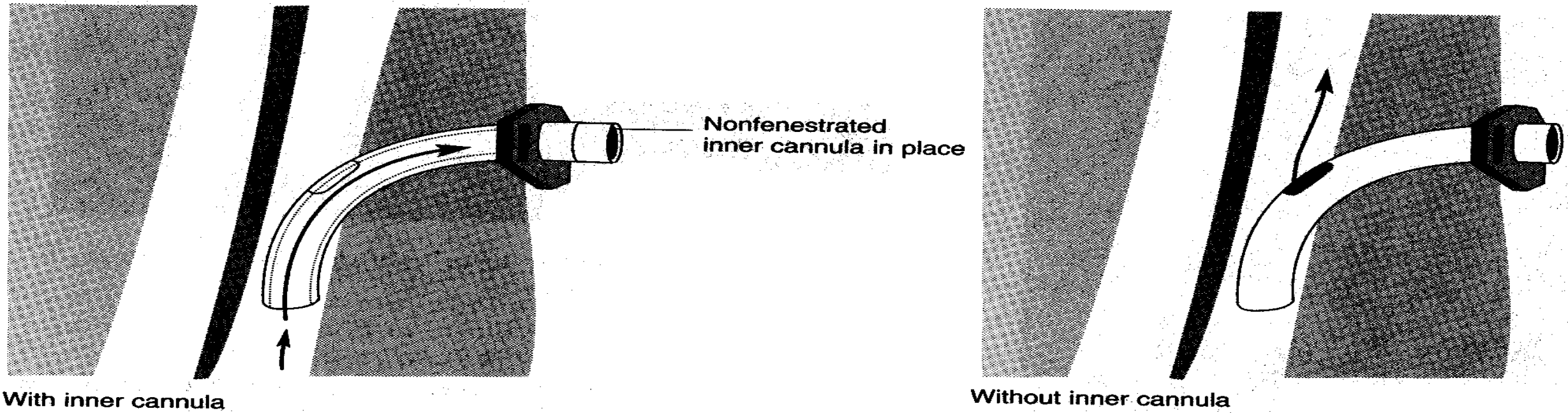


Figure 3–14. The fenestrated tracheostomy tube. Placement of a nonfenestrated inner cannula blocks the fenestration.

Deflated cuff: space between trachea and cuff is open → air can pass

Inflated cuff: no material above the cuff can pass below (pts who aspirate their saliva, need respiratory training → suctioning necessary)

If cuff inflated too long → tracheal irritation

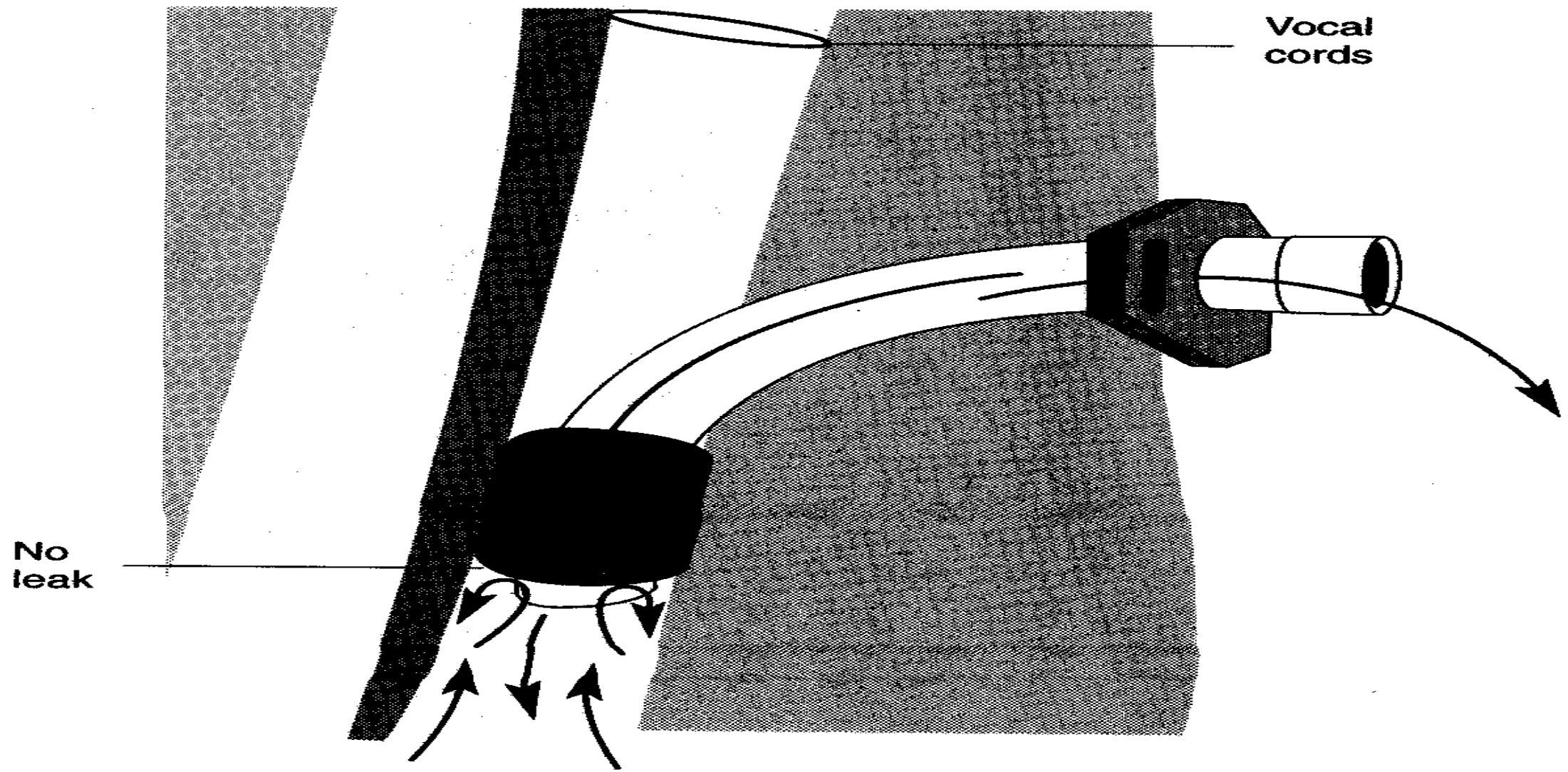


Figure 3–26. Function of the inflated cuff in stopping airflow to the upper airway.

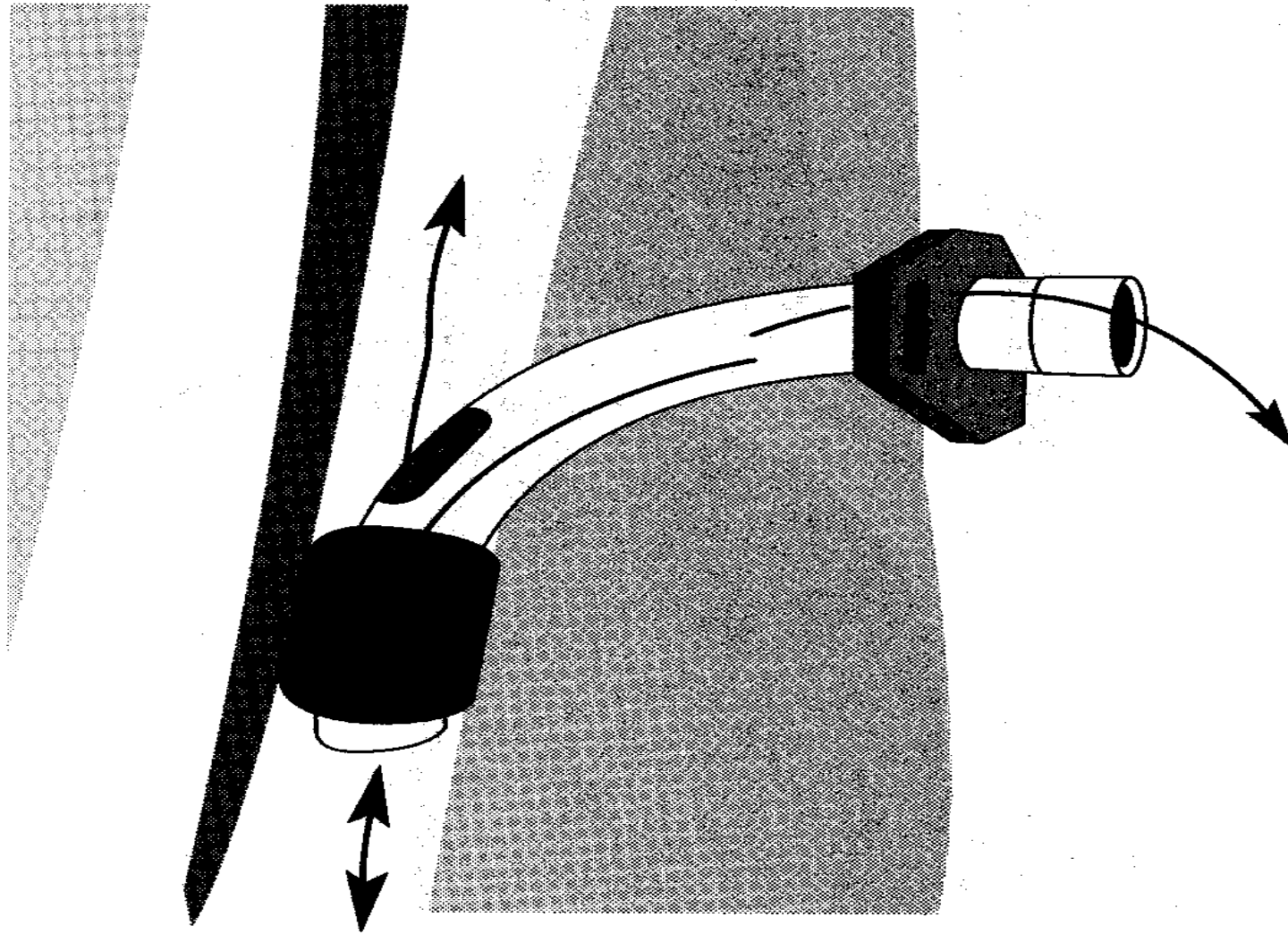


Figure 5–4. Airflow moving through the fenestration of a cuffed fenestrated tracheostomy tube.



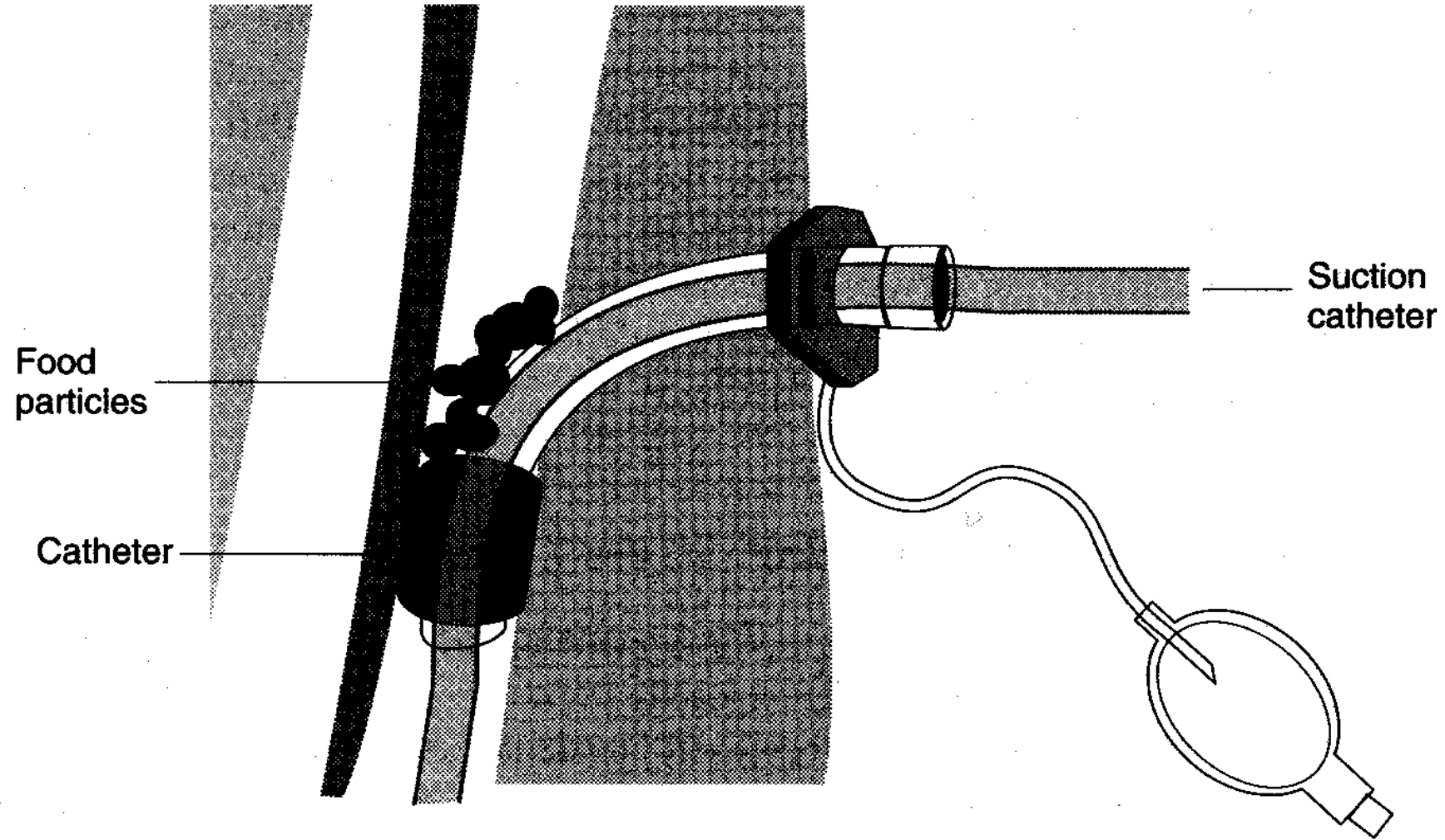


Figure 7-9. Food particles pooled on top of an inflated tracheostomy tube cuff.

Management of the tracheostomized pt. During swallowing assessment treatment

Should examine the tracheostomy tube to determine:

- Presence of a cuff
- Status of the cuff (inflated, or deflated)
- Size of the tube
- Presence of fenestration
- The period

Length of time it has been in place:

- More than 6 months
 - Scar tissue formed restrict laryngeal elevation.
 - Reduced airflow
 - Reduced sensory stimulation
 - Reduced vf closure for swallowing and vocalization.

Management of the tracheostomized pt. During swallowing assessment treatment

- A recent study has found that the tube occlusion digitally doesn't negatively effect swallowing and may result in improvements in laryngeal elevation.
- Use of valve may helpful in place of light digital occlusion if pt's respiratory status is stable and tolerate the valve comfortably, and it opens during breathing and closes during exhalatory pressure to increase sufficiently for speech.

Management of the tracheostomy tube:

It is generally best to deflate the tracheostomy cuff prior to attempting any swallows.



An inflated cuff may irritate the trachea as the larynx elevates during swallowing, or it may restrict laryngeal elevation.

-
- Its important to check with the pt's physician & obtain his advisability of deflating the cuff, as well as the pt's tolerance for possible aspiration.

****it is extra important to:**

1. Suction the pt well both orally & via the tracheostomy to assure a clear oral cavity and airway prior to beginning therapy.
2. Suction the pt well immediately after the cuff is deflated so that any secretion sitting above the cuff will be cleared away as they drain around the tube and into the trachea.

During each swallow the pt should gently occlude his or her tracheostomy tube with the gloved finger or gauze pad to establish as near-normal tracheal pressure during swallowing as possible.

-
- One of the advantages in initiating swallowing therapy with a tracheostomy tube in place is that: The swallowing therapist can observe aspiration by examining any expectoration through the tube.
 - Several authors have reported specific but not infrequent occurring problems related to the presence of tracheostomy tubes during swallowing therapy.

Some of these problems are:

- Restriction or limited upward laryngeal movement to protect the airway ,causing the formation of scar tissue, thus increasing the chances of aspiration.
- Compression of the esophagus by the tube pushing posteriorly on the common wall between the trachea and the esophagus
- The change in intratracheal pressure because of the presence of the tube.

Speech valves



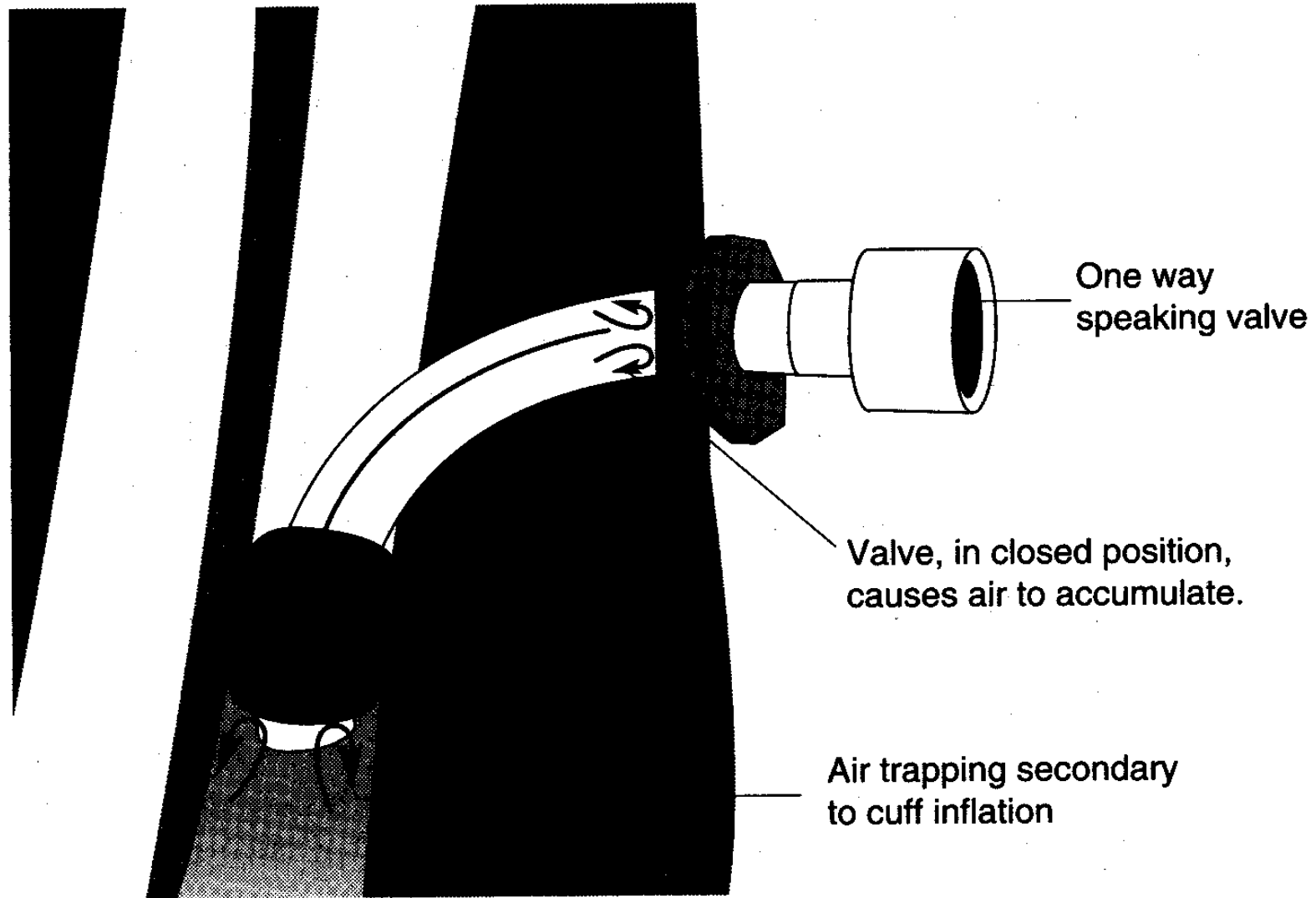


Figure 5-10. Speaking valve use in the presence of an inflated cuff.

Ventilator-dependent patients

Pt. With Ventilator → their swallowing worsened

Swallowing and respiration are reciprocal , **why?**



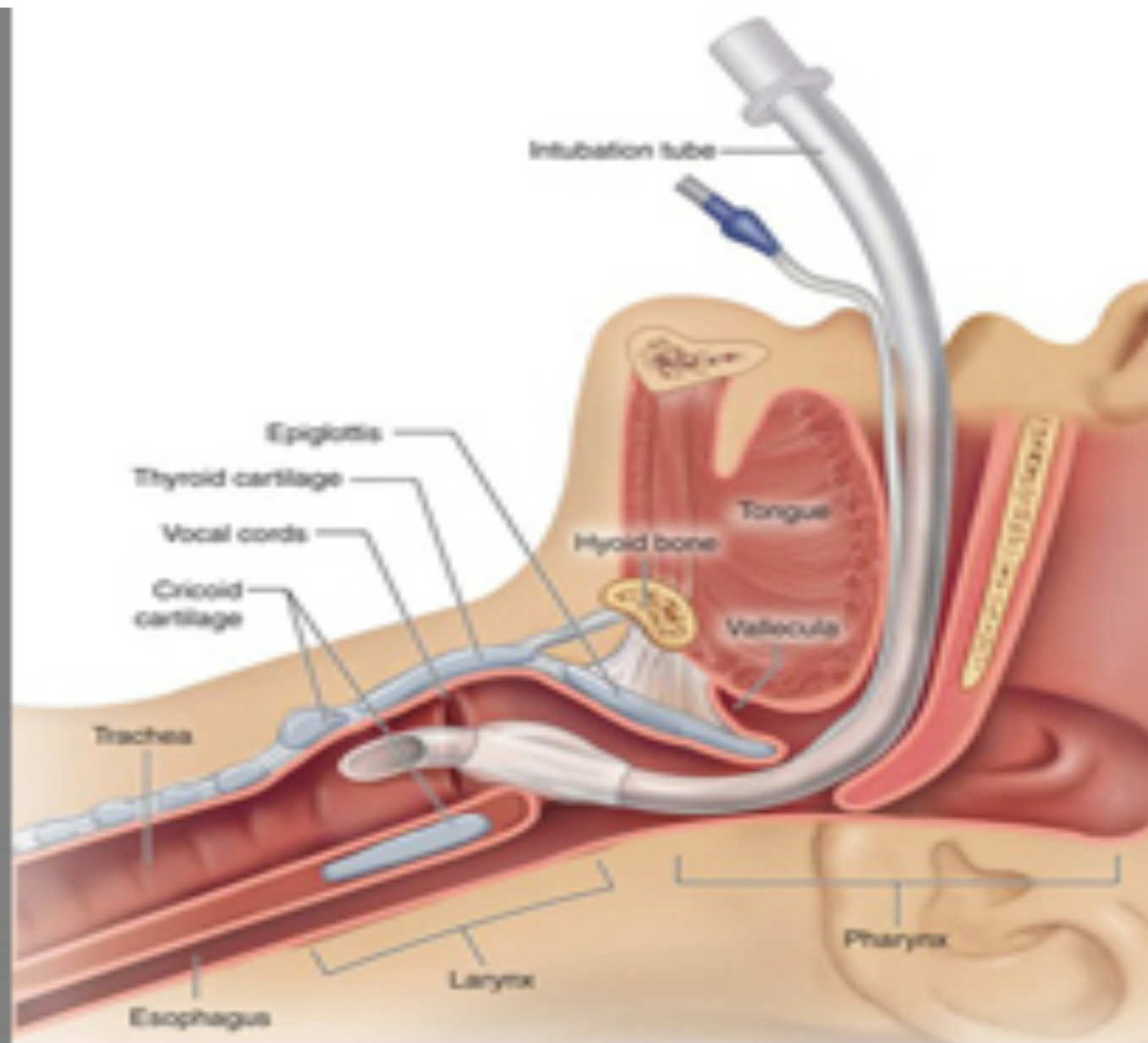
Because the ventilator controls respiratory cycle, the pt's can't lengthen the exhalation to allow for the swallow.

<https://www.youtube.com/watch?v=UCYBGRj4Teo>

Intubation

- Placing a tube through the mouth or nose through the pharynx to the lower trachea for more stable airway.
- Laryngeal tissue damage if the tube place for days or weeks which affected laryngeal closure during swallowing may result in redness, edema, nodule or polyp.

No swallowing therapy done until intubation is removed (what do you think??)



Decision on potentially Best Posture (cont.)

- Poor tongue control.
- Difficulty maneuvering the bolus in the mouth.
- Bolus trickling over the base of the tongue & into the pharynx before the voluntary swallow is initiated .



Tilt the head downward and then throw the head backward.

Decision on potentially Best Posture

- If the pt. has had a hemilaryngectomy.
- Any reason for a delay in triggering of the pharyngeal swallow.



Tilt the head downward so that the vallecular space is widened, the airway entrance is narrowed, & the epiglottis is positioned more posteriorly.

Inadequate laryngeal closure



Forward tilting of the head may result in greater protection of the airway by the overhanging epiglottis

Decision on potentially Best Posture

Unilateral pharyngeal paralysis



Turn the pt.'s head toward the affected side to close the pyriform sinus on that side, directing the material down the more functional side.

Decision on potentially Best Posture

Lingual hemiparesis or reduction in oral function on one side.



Tilting the head toward the stronger side may result in directing the material down that side.

Selection of Optimal Food position in the mouth

Food > side of best function & best sensitivity

Liquid > posteriorly in the oral cavity
(straw/syringe)

Selection of possible best food consistency

Selection of food depends on:

- Info. collected in the history.
- Data on oral control.
- Info. on pharyngeal & laryngeal control.

➤ **Pts with:**

1. Poor oral control

- ✓ Thickened liquid first, then moving toward materials of thin consistencies.

2. Delayed pharyngeal swallow or reduced closure of laryngeal entrance

- ✓ Materials of thicker consistency as applesauce or mashed potatoes.

3. Reduced tongue base or pharyngeal wall contraction, reduced laryngeal elevation, reduced esophageal sphincter opening

- ✓ liquids

Combination of disorders, make selection of consistencies more difficult.

Selection of optimum swallowing instruction

- The sequence of swallowing instruction should be based on information collected in the preparatory examination
- Posture or sequence of postures should be carefully noted, as should the need for voluntary protection of the airway during the swallow.

An Example :

A pt. with slightly reduced tongue control & reduced laryngeal control may need to begin by tilting his or her head downward while putting food in the mouth, then tip his or her head backward when going to swallow, hold the breath during the swallow to voluntarily protect the airway.

Order of Interventions Introduced

- The rationale for this sequencing of interventions is based on:
 - ✓ The muscles effort required by pts
 - ✓ The ease of application
 - ✓ Learning of the various procedures.

In order:

1. Postural techniques.
2. Increase oral sensation.
3. Swallowing maneuvers.
4. Diet (food consistency).

Postural techniques

- Postural techniques are easily used by a wide range of pts
- Reduced cognition , children, and pts with some degree of restricted physical mobility.
- effectively eliminate aspiration on liquids and other foods in a wide range of pt's.

Postural Techniques: See table 5.2 p.181.

Techniques To improve Oral Sensory Awareness

Used in:

- ❖ Pts with swallow apraxia.
 - ❖ Delayed onset of the oral swallow.
 - ❖ Delayed triggering of the pharyngeal swallow.
- Allowing the clinician / cooperation.

Sensory techniques include:

- ❑ Increasing downward pressure of the spoon against the tongue in presenting food in the mouth.
- ❑ Presentation of a sour bolus.
- ❑ Presentation of a cold bolus.
- ❑ Presentation of a bolus requiring chewing.

Techniques To improve Oral Sensory Awareness

❑ Thermal tactile stimulation:

- It was designed to heighten oral awareness, and provide an alerting sensory stimulus to the cortex & brainstem, when the pt initiates the oral stage of swallow, the pharyngeal swallow will trigger more rapidly.

➤ <https://www.youtube.com/watch?v=ukfdL7FNxJo>

Techniques To improve Oral Sensory Awareness

- This technique has been demonstrated to facilitate faster triggering of the pharyngeal swallow after the stimulation, and reducing the delay for several swallows thereafter.
- **Measures of the effectiveness of these procedures to increase oral sensory input include:**
 1. Duration of time from command to swallow until initiation of the oral stage of swallow.
 2. Oral transit time.
 3. Pharyngeal delay time.

Swallow Maneuvers

1) The supraglottic swallow:

- Designed to close the airway at the level of the true VFs before, and during the swallow.
- <https://www.youtube.com/watch?v=Ga5ijAKn9SI>

2) The super-supraglottic swallow:

- Designed to close the airway entrance before, and during the swallow.
- <https://www.youtube.com/watch?v=C2HIepSWG84>

3. **The effortful swallow:**

- Designed to increase tongue base posterior motion during the pharyngeal swallow & thus improve bolus clearance from the valleculae
- <https://www.youtube.com/watch?v=wKmJdCe7aKs>

4) **Mendelson maneuver:**

- Designed to increase the laryngeal elevation .Also it improve the overall coordination of the swallow
- Improve the overall coordination of the swallow.
- https://www.youtube.com/watch?v=NHZ5g8roe_A

Swallow Maneuvers

These requires:

- ✓ Careful direction following ability, and are not feasible in pts who have cognitive or significant language impairment.
- ✓ Increased muscular effort, and are not appropriate in pts who fatigue easily.

Food Consistency(Diet)Changes

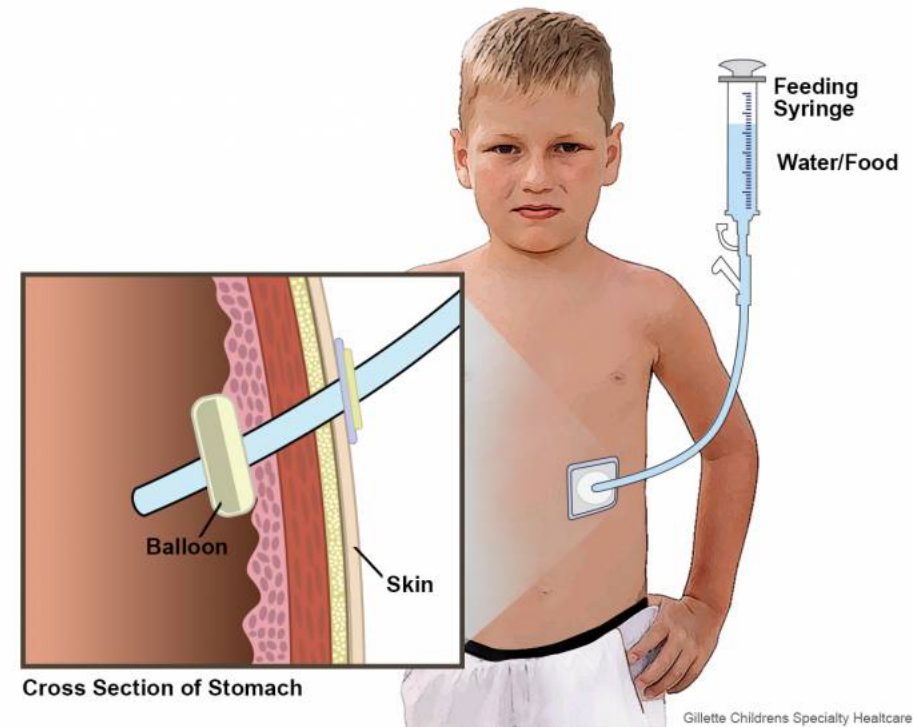
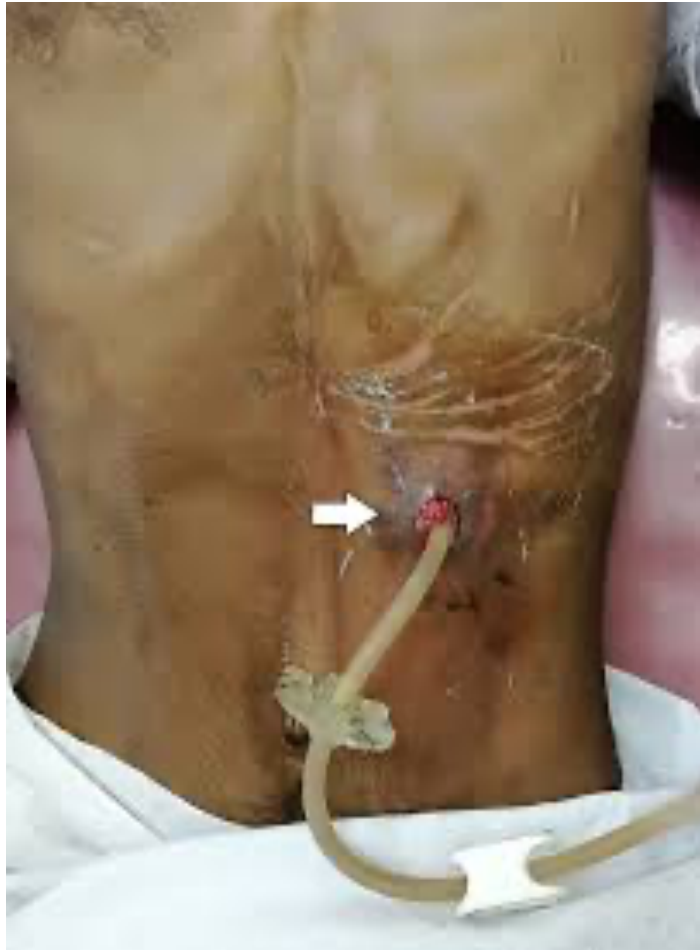- Elimination of certain food consistencies from the diet should be the last strategy examined.
- This should be done only if other therapy strategies are not feasible, as in a pt with a movement disorder whose posture changes continuously, who cannot follow directions, and use swallow maneuvers, for whom oral sensory procedures are inappropriate.
- In some cases, introduction of therapy procedures into the diagnostic procedure immediately enable the pt. to begin eating.

Oral Versus Non-oral Feeding

- There are no guidelines the clinician can use to make the decision whether the pt. should continue to be fed orally, or on a nasogastric tube or given some type of gastrostomy.
- When it takes a long time to eat a particular food consistency (more than 10 secs.), most pt's will not continue eating that consistency of food or may not eat a sufficient amount of food.
- **Time** taken to swallow a bolus is an important element in nutritional management.

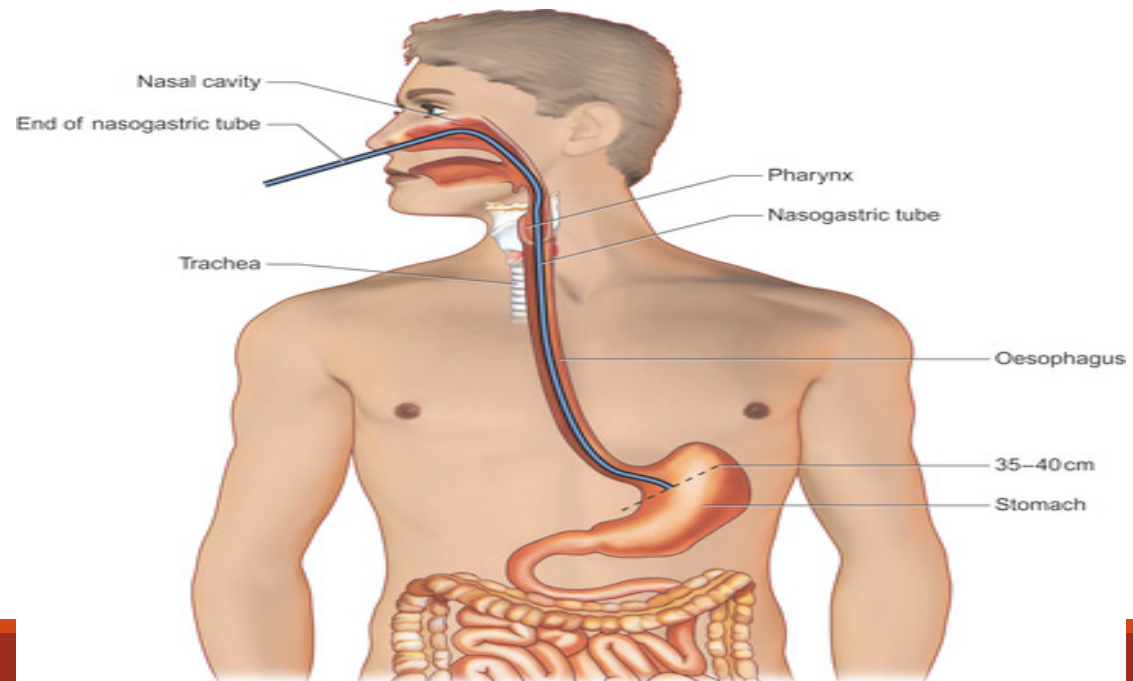
-
- Radiographic studies indicate that if the pt. takes more than 10 secs. for oral and pharyngeal transit time combined to swallow every bolus without being aspirated, the pt may feed by mouth but will need a Non-oral feeding to supplement oral feedings and to provide adequate nutrition and hydration.
 - Gastrostomy may be used if the pt. progress in therapy is slow (if it takes more than 3-4 weeks).
 - It is better not to leave a nasogastric tube for a long period of time (for more than 3-4 weeks). / Pt may be taught to manage the nasogastric tube.

Gastrostomy (through the abdomen into the stomach)



Nasogastric tube

Through the nares to pass through the posterior oropharynx, down the esophagus, and into the stomach.



Factors Used To Determine The Type Of Non-oral Feeding:

1. The pt's. gastrointestinal history.
 2. The cost of feeding and insurance coverage.
 3. The patient's behavior.
 4. The patient's preference.
 5. The patient's medical diagnosis.
- ❖ ***If the pt's swallowing function is borderline (approx. 10 secs. for oral & pharyngeal transit times), the dietitian may provide the patient with diet supplements for the content of the food eaten orally.***

-
- If pts. **Aspirates** more than 10% of each bolus and are aware of that aspiration, the food consistency will be eliminated from their diet. If pts are unable to swallow any food consistency with less than 10% aspiration, he/she will stop eating because of the discomfort of frequent coughing.
 - Pts who are unaware of having swallowing disorders, or do not cough when aspirating, will persevere in attempting to feed by mouth despite aspiration of excessive amounts.
 - Swallowing therapist should inform the pt's managing physician about the gross percentage of each bolus consistency that is aspirated despite of all therapy attempts (posture change....etc...)
 - ❖ ***Patient who is aspirated more than 10% of every bolus, regardless of consistency of food, should not be feeding orally.***

Compensatory Treatment Procedures (CTPs)

- CTPs are introduced first in the diagnostic procedure.
- CTPs control the flow of food and eliminate the patient's symptoms, such as aspiration, but do not necessarily change the physiology of the patient's swallow.
- These procedures involve less muscle effort and do not fatigue the patient as quickly as some swallow exercises.
- they are under the control of the caregiver and/or the clinician.

Compensatory Treatment Procedures include:

1. Postural changes, which potentially change the dimensions of the pharynx and the direction of food flow without increasing the patients work or effort.
2. Increasing sensory input.
3. Modifying volume and speed of food presentation.
4. Changing food consistency or viscosity.
5. Introducing intraoral prosthetic.

Postural techniques:

- First the swallowing therapist must correctly diagnose the physiologic or anatomic disorder in the patient's deglutition then identify the posture that will facilitate swallowing.
- Some patients are unable to use postural strategy because of head stabilization devices or other physical constraints.
- During radiographic procedures, the clinician cannot introduce all of the postures to assess their individual effects.
- Postural technique redirect food flow and change pharyngeal dimensions in systematic ways.
- Table 6.1 / page 198.

Postural techniques:

Lying Down: it is used when there is reduced pharyngeal contraction or reduced laryngeal elevation, resulting residue in the pharynx that is aspirated after swallow.

- Gravity
- liquids ----- straw
- Pt's with reflux.
- pt should cough to clear any residue.

Techniques To Improve Oral Sensory Awareness

It is used with patients with swallow apraxia, tactile agnosia for food, delayed onset of the oral swallow, reduced oral sensation, or delayed triggering of the pharyngeal swallow.

Sensory enhancement techniques include:

1. Increasing downward pressure of the spoon against the tongue when presenting food in the mouth.
2. Presenting a sour bolus (50:50 lemon juice+ barium)
3. Presenting a cold bolus.
4. Presenting a bolus requiring a chewing.
5. Presenting a larger volume bolus.
6. Thermal-tactile stimulation

7. An exaggerated suck-swallow:

- ✓ facilitates triggering of the pharyngeal swallow.
- ✓ Increased tongue-jaw sucking movements with lips closed.
- ✓ This is also helpful to the patients with poor saliva control.

Modifying Volume and Speed of Food Presentation

- Taking smaller boluses at slower rate may eliminate any risk of aspiration in patients.
- In patients with a delay in pharyngeal triggering, a larger bolus may facilitate in triggering.
- In patients with a weakened pharyngeal swallow that requires 2 or 3 swallows per bolus.
- Too much food + Too rapid = severe collection of food in the pharynx and aspiration.

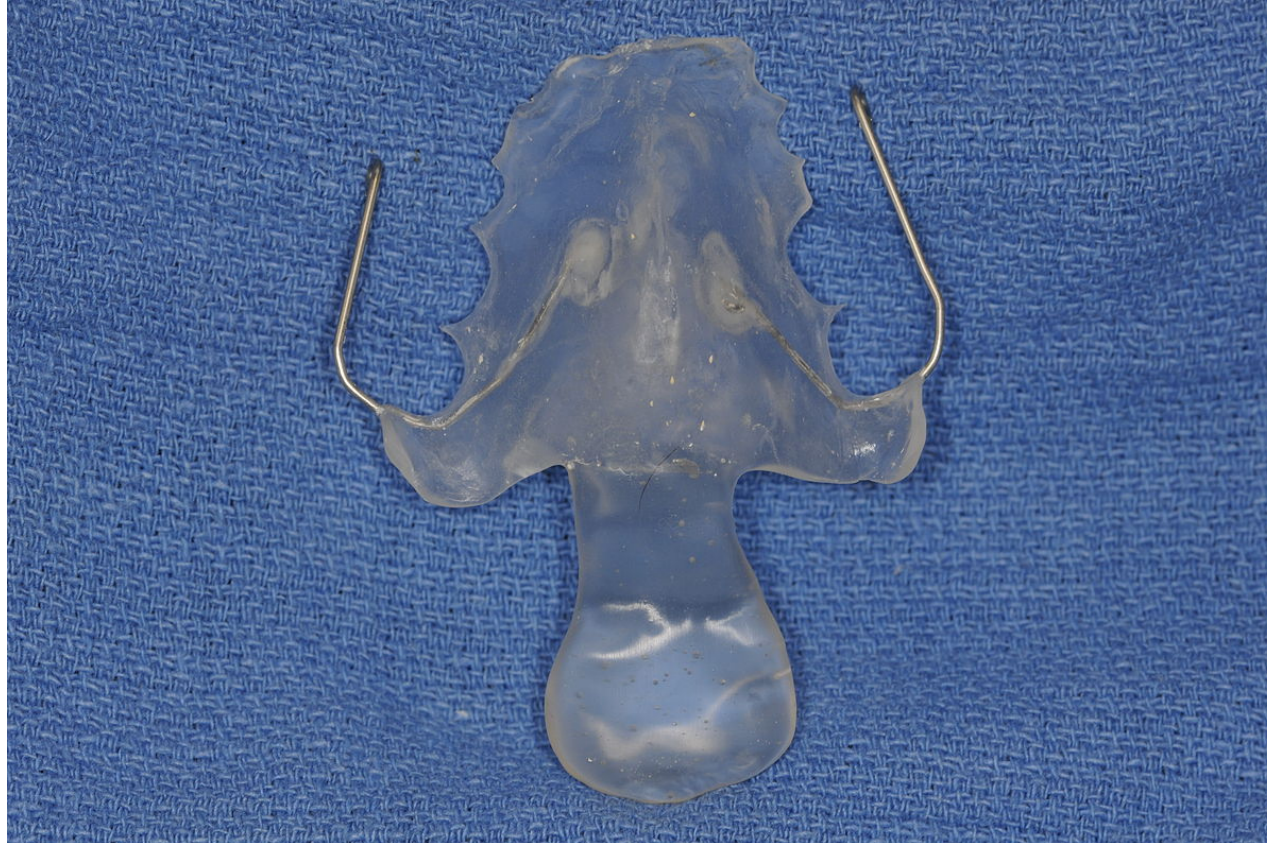Food Consistency (Diet) Changes

- Eliminating food consistencies from the diet should be done only if other compensatory or therapy strategies are not feasible.
- Swallowing therapists must work with facility dietitians to define specific foods prepared that fit into each category.
- (Table 6.2/ p 203).

Intraoral Prosthetic

- An important compensatory procedure to improve swallowing in oral cancer pts with significant loss of oral tongue tissue (25% or more) or tongue movement, neurologic pts with hypoglossal paralysis, and pts with velopharyngeal deficits.
- Without prosthesis, the patient has a larger oral cavity and a very small tongue that is incapable of controlling food in the mouth for chewing or swallowing.

Palatal lift prosthesis



Therapy Procedures by Category

- Therapy procedures are designed to change swallow physiology in contrast to compensatory strategies, which are designed to eliminate symptoms.
- To improve range of motion of oral or pharyngeal structure.
- To improve sensory input prior to the swallow.
- To take voluntary control over the timing or coordination of selected oropharyngeal movements during swallow.

Direct vs Indirect therapy

Indirect therapy :

- Involves exercise programs or swallow of saliva, but no food or liquids is given.
- It is used in patients who aspirate on all food viscosities and volumes. (they are unsafe for any oral intake), for example?
- Swallow maneuvers can be practiced with saliva only.

Direct vs Indirect therapy

Direct therapy:

- Involves presenting food or liquid to the patient, and asking him to swallow it while following specified instructions.
- Exercises involve positioning the head or body in a particular way so aspiration is eliminated.
- The patient should be given written instructions describing the appropriate steps to follow.
- Patient should be given samples to practice dry swallow before proceeding to swallows food or liquids. Small amounts of food provided for practice should be given.
- cough

Types of Therapy Techniques

➤ Oral control and oral and pharyngeal and range of motion exercise.

1. Range-of-motion exercises.

✓ Improving the extent of movement of the lips, jaws, oral tongue, tongue base, larynx and VF.

✓ Bolus control and chewing exercises can be used to improve fine motor control of the tongue.

2. Oral motor control exercises. (tongue control during swallowing):

✓ Lateralization of the tongue during chewing.

✓ Elevating of the tongue to the hard palate.

✓ Cupping of the tongue around the bolus to hold it in a cohesive manner with the sides of the tongue sealed .

❖ *The exercises should be written down for the pt or caregiver & completed without the therapist presence.*

Types of Therapy Techniques

3. Range-of-motion tongue exercise:

- ✓ Increasing the range of the tongue motion, including tongue elevation and lateralization, should improve the oral transit.

3. Resistance Exercises:

- ✓ Pushing the tongue against a tongue blade, popsicle, sucker.

3. Bolus control Exercises:

- ✓ Improving lingual control of the bolus without asking the patient to swallow.

Types of Therapy Techniques

➤ Exercises to Improve Gross Manipulation of Material.

- Pt is given something large to manipulate in the mouth, such as a rolled (4×4) gauze pad.
- Pt grasp it between the tongue and palate, move it from side to side, backward and forward. Then back to the middle of the mouth and back to the teeth on one side. (tongue manipulates food during chewing).

Types of Therapy Techniques

➤ Exercises To Hold A Cohesive Bolus:

- After doing exercise to Improve Gross Manipulation of Material, the patient places the bolus (paste-consistency, approx. one third teaspoon) moving it around the mouth without loosing the material or letting it spread out around the mouth. Patient cup the tongue around the bolus.
- Then liquid

Types of Therapy Techniques

➤ **Bolus Propulsion Exercise:**

- Using 4 long, narrow roll gauze soaked in cranberry or orange juice. With the clinician holding the front of the gauze (so it can't be swallowed), the patient is asked to push upward and backward against the gauze with the tongue, squeezing liquid out of it and pushing the liquid backward at the same time.

Range Of Motion Exercises For Pharyngeal Structures

- 1. Airway Entrance.** The patient should be seated and told to hold breath and to bear down for a second, then to let go. Pt may do this by pushing down or pulling up on the chair with both hands for several seconds. Patient with blood pressure should not do this exercise (bearing down increase blood pressure).
- 2. Vocal Fold Adduction.** (Pt with poor vocal fold adduction).
 - Bear down against a chair with only one hand and to produce a clear voice (repeated exercise 5 times). Each time the patient repeat “ah” 5 times with hard glottal attack. This increases muscle activity in the larynx and is basic to good laryngeal closure during swallowing.

Range Of Motion Exercises For Pharyngeal Structures

- Another exercise is to ask the patient to practice, supraglottic swallow (take a breath ,hold it, then cough as strong as possible).

3. Tongue Base Exercise.

- Pull tongue straight in the mouth as far as possible.
- Pull back and pretend to gargle as hard as possible and then release.
- Pretend to yawn, which pulls the tongue base back.

Range Of Motion Exercises For Pharyngeal Structures

4. Laryngeal Elevation Exercise - the falsetto exercise.

- Pt is asked to slide up the pitch scale as high as possible to a high squeaky voice. When reaching the top scale, the patient holds the high note for several seconds with as much effort as possible.
- During the production of the falsetto the larynx elevates almost as much as it does during swallow.

Sensory Motor Integration Procedures.

Swallow Maneuvers

Therapy and Management For specific Swallowing disorders

Disorders affecting the oral preparatory phase

- The patient must be able to manipulate food in mouth while maintaining complete closure of the lips, and controlling the bolus, so nothing spills into pharynx.
- The clinician should be sure that the patients maintain comfortable nasal breathing from the time that food is placed in the mouth until pharyngeal swallow is completed.

-
- Reduced labial closure.
 - Reduced range of tongue movement laterally during mastication.
 - Reduced buccal tension , buccal scarring (facial exercises).
 - Reduced tongue movement to form the bolus.
 - Reduced ability to hold the bolus in normal position.
 - Reduced oral sensitivity.

Disorders affecting the oral phase of the swallow:

- Reduced tongue elevation.
- Reduced anterior-posterior tongue movement.
- Disorganized patterns of anterior-posterior tongue movement.
- Reduced tongue strength.
- Swallowing Apraxia.
- Delayed or Absent triggering of the pharyngeal swallow.

Disorders Affecting the Pharyngeal Stage of the Shallow:

Compensatory Techniques Include:

1. Alternating liquid and semisolid or solid swallows, so the liquid washes the material of thicker consistency through the pharynx.
2. Limiting the diet to liquids or thin paste material requiring less pressure to clear the pharynx.
3. Following each swallow of food or liquid with several repetitive dry swallows.

Reduced Laryngeal Elevation:

- Mandelsohn maneuver.
- Supraglottic swallow.
- Falsetto exercise.
- Light pressure upward on the thyroid cartilage.

Reduced Laryngeal Closure at the Airway Entrance:

Super-supra glottic swallow.

Reduced Laryngeal Closure at the V.F:

- Supraglottic swallow.

Reduced Laryngeal Closure at the V.F:

- Head rotation and chin-down are the best way to best airway closure.

Disorders Affecting the Esophageal Phase of the Swallow:

This disorders handled with medication or surgery and diagnosed radiographic by swallowing therapist and radiologist.

Other Issues in Swallowing Therapy:

- **Combining postures and swallow maneuvers :**
 - ✓ Some patients need the both techniques to attain a safe and efficient swallow . Such as patient with poor tongue base.
 - ✓ Chin down posture and effortful swallow
 - ✓ The posture and maneuver should be examined separately during the modified barium swallow and the combination of the two assessed.

Biofeedback as an Assist to Swallowing Therapy

Some of the instrumental procedures:

1. Surface Electromyography :

- ✓ Amount of effort utilized in attempts at lip closure.
- ✓ Under the chin- Degree of muscle effort used during the effortful swallow maneuver or mandelsohn maneuver.
- ✓ Electrical activity Laryngeal elevators during the maneuver.

2. Ultrasound :

- ✓ Patient observe tongue motion over time while practicing the upward and backward movement of the tongue to propel the bolus through the oral cavity.

Biofeedback as an Assist to Swallowing Therapy

3. Video Endoscopy:

- ✓ Closure of the true vocal folds before a swallow attempt.
- ✓ If patient has difficulty in attaining vocal fold or air way entrance closure he could observe the movement during various breath hold maneuvers.

4. Video Fluoroscopy:

- ✓ Understand the goals of the therapy.

When To Begin Swallowing Therapy:

- Medically stable (dysphagic) → Videofluoroscopy → Therapy plan.
- Patient seen daily in the hospital and weekly.
- ✓ Surgically treated head and neck cancer, as soon as healing has progressed enough to allow them to try swallow (7 to 14 days post surgery with no healing complications).
- ✓ Undergoing radiation therapy (the time there is complain) .
- ✓ A stroke patient when they are awake or alert (2 or 3 days).
- Outpatient → videofluoroscopy + intensive therapy.

-
- Pt's who receive therapy months or years after the onset of their problem are still capable of achieving oral intake.
 - Therapy is usually daily for inpatients and weekly for outpatients.
 - Tracheostomy tubes and non-oral feeding tubes are left in place during swallowing assessment and therapy.

Maintenance Program

- Maintenance programs are the applications of therapy strategies in a continuous way which assist patients to maintain their function for a period of time.
- Programs are needed in patients who are unable to monitor their own performance. For example whom?
- Maintain compensatory strategies.
- Patients who are unable to monitor their own performance such as patients with cognitive deficits.
- Maintain compensatory function as long as possible.

Incorporating Swallowing Therapy into Eating

- First goal with a dysphagic patient should be; to identify the safest way for the patient to eat, and the most efficient, and quickest way for the him/her to swallow.
- This means using compensatory strategies in the beginning.
 - ✓ Not working remain non-oral with swallowing therapy.
 - ✓ Compensatory strategies work but swallowing therapy may take place in order not to use the compensatory strategies forever.
 - ✓ Pt can't use therapy compensatory strategy but the clinician believes swallowing therapy is appropriate, then therapy should take place

Once the patient has the ability to eat safely, nevertheless under what circumstances then the task monitoring is turned over to a caregiver as a maintenance task.

Group Therapy

- Group therapy may be appropriate if several patients are in the facility, at the same time who are working on the same therapy procedures. so patients may be brought together to reinforce each others use of particular procedures .

Cultural Difference in Dysphagia's Management

- Meals are a social events where a great deal of communication takes place, **How?**

Meals Management:

- Meal times should be as pleasant as possible by given the easiest food for swallow and the best taste.
- **Therapist also should:**
 - ✓ Warn the family to not encourage patient to talk after swallowing because of the increased risk of aspiration.
 - ✓ Providing patient with food that can be swallowed easily (include the pt at the mealtime).

Medication to Improve Swallowing Disorders

- Use of atropine to reduce drooling .

Surgical Interventions:

- Surgical interventions to improve oropharyngeal swallowing should not be until the therapy has had at least a 6 months trial.
- Oropharyngeal surgical is a sensitive and may create more damage through scar tissues.

Issues in the Management of Dysphagia in Various Settings

1. Acute Care Hospital :

- ✓ The pressure is on the speech-Language pathologist or swallowing therapist to identify dysphagic patients, define their swallow physiology, and outline a treatment plan as quickly as possible.

.

2. Schools :

- ✓ If there is any question about a child aspirating during feeding experiences in school, it's suggested that the caregiver in the school refrain from further oral feeding of the child until the diagnostic studies are completed.
- ✓ If parents insist that the child should be fed orally, it's suggested that the school offer the parent's the opportunity to come and feed the child.

Nursing home setting:

- Assessment methods.
- Feeding staff should follow the directions of the swallowing therapist in terms of the type of food to be fed to the patient, the timing and length of feedings, the way in which food is placed in the mouth , and the observations to be made with each patient prior to placing another food serving into the patient's mouth.

Nursing home setting:

- The feeding staff should also pay attention to the patient's behavior and reaction to the placement of food in the mouth .
- Any changes in the patient's respiratory rate , voice quality or general alertness throughout a meal should be noted.
- The feeding staff should report to swallowing therapist any changes in the patient's function during a meal and discontinue feeding until the swallowing therapist has assessed the situation.

Home:

- In home care, the family can be engaged in providing the appropriate feeding after or by the swallowing therapist and can continue home practice with the patient between the swallowing therapist's visits.
- It is critical that the swallowing therapist provide the patient and the family with tools needed to practice exercises correctly.

Etiology

1. Neurological disorders:

- ✓ Dysphagia may be the predominant symptom in a number of neuromuscular diseases. A focal stroke in the brainstem may produce acute Dysphagia. Other neurological diseases such as MS may involve the pharynx and result in Dysphagia. In addition, some medications prescribed for the treatment of neuromuscular disorders can depress the swallowing reflex.
- Difficulty swallowing caused by a neurologic disorder
 - By impairing motor and sensory functions of oral and pharyngeal phases of swallowing
 - Esophageal relatively spared
 - Oral/pharyngeal dysphagia may result from structural problems including tumors
- Material may
 - Be delayed or retained along the way
 - Go out of bounds into the nasopharynx or larynx
 - Result in morbidity or mortality from neurogenic dysphagia

✓ ALS

✓ MS

✓ CVA

2. Autoimmune diseases.

3. Muscular diseases :

✓ Muscle weakness

✓ Polio

4. Cognitive disorders :

- Due to limited ability to recognize, understand, and communicate their difficulty eating
- Dementia

5. Oncological diseases

6. psychological problems.

7. Lack of saliva

8. Elderly

Clinical Features

3 modes of presentation:

1. Overt Neurogenic Dysphagia with an identified neurologic disorder with obvious symptoms or complications of dysphagia
2. Overt Neurogenic Dysphagia without having an established neurologic diagnosis
 - Physicians think esophagus; therefore don't think neurologic
3. Patients with or without a clear neurologic diagnosis with substantial oral/pharyngeal dysfunction that is "silent" due to:
 1. **Compensatory processes**; voluntary and involuntary
 2. **Reduced laryngeal cough reflex**
 3. **Cognitive impairment**

MECHANICAL DISORDERS OF SWALLOWING

- Difficulty swallowing secondary to a combination of deglutitory muscle loss and loss of the motor and sensory innervations to those muscles
- Problem in the structures needed to complete the act of swallowing
 - Some shared deglutitory problems with neurologic (e.g., difficulty masticating, oral and pharyngeal pooling, lengthened swallowing transit time, difficulty channeling food into esophagus, aspiration)

CAUSES OF MECHANICAL DYSPHAGIA

1. Acute Inflammations

- Due to nonspecific secondary reactions to injury of the oropharyngeal tissue
 - injury due to fungal, bacterial, or viral agents, chemical irritants, or traumatic insults
- Early recognition and treatment are very important
 - Most can be controlled within a short period of time
- Should be ruled out in patients
 - whose mental state or competence interferes with the ability to communicate oral pain
 - Who evidence unexplainable dysphagia or sudden refusal to eat

ACUTE INFLAMMATIONS

Herpes Simplex

Ludwig's Angina – submandibular space infection

Lingual Tonsillitis

Epiglottitis

Acute Pharyngitis

Lateral Pharyngeal Space Infections

Fungal Inflammation

CAUSES OF MECHANICAL DYSPHAGIA

2. TRAUMA: due to

- Major traumatic tissue losses (e.g., gun-shot wounds)
- Fairly benign injuries in the oral cavity
 - Do NOT create significant swallowing complaints except when superimposed on other mechanism of dysphagia
 - e.g., trauma from toothbrush; mucosal irritation from ill-fitting dentures (reddened or whitish change in mucosa at point of contact)
 - Biting side of lip or cheek due to lost sensation may create some swallowing discomfort

CAUSES OF MECHANICAL DYSPHAGIA

3.MACROGLOSSIA

- Abnormally large tongue
- interfere with the propulsive action of the bolus
- Causes: lymphatic obstruction, surgery or irradiation, hypothyroidism, children with down syndrome

•

CAUSES OF MECHANICAL DYSPHAGIA

4. CARCINOMA

- Largest group of patients with mechanical dysphagia
- Due to oral, pharyngeal, laryngeal, or esophageal structures removed or rearranged, or reconstructed (or combination)

Surgical Resection Impairments

1. Oropharyngeal Lesions

- Include anterior tongue resections, as well as resections of soft palate, tonsils, base of tongue, and superior and lateral larynx
- May experience:
 - Nasal regurgitation
 - Decreased bolus transit, aspiration
 - Loss of bolus control
- May include for example:
 - Glossectomy

Surgical Resection Impairments

2. Partial Laryngectomy

- Hemilaryngectomy and supraglottic laryngectomy
- **Hemilaryngectomy:** unilateral resection of the VF, Sometimes, with preservation of the epiglottis.
- **Supraglottic Laryngectomy:** The front of the voice box is made of cartilage and is sometimes called the Adam's apple. The removal the top part of the voice box (larynx), near the vocal cords. Resection of both vestibular and aryepiglottic folds (the epiglottis, false vocal cords, and superior half of the thyroid cartilage).
- **3. Laryngectomy**
- including the vocal folds, hyoid bone, epiglottis, thyroid and cricoid cartilage and a few tracheal cartilage rings.

4. Tracheoesophageal Puncture

- Allows patient to shunt air ,acting as vibrator to produce voice (a valve is placed in puncture).
- May be permanent or temporarily.

Swallowing Disorders Caused by Neurologic Impairments

Conditions that occur suddenly, the pt. is suspected to recover such as head trauma, stroke, spinal cord injury

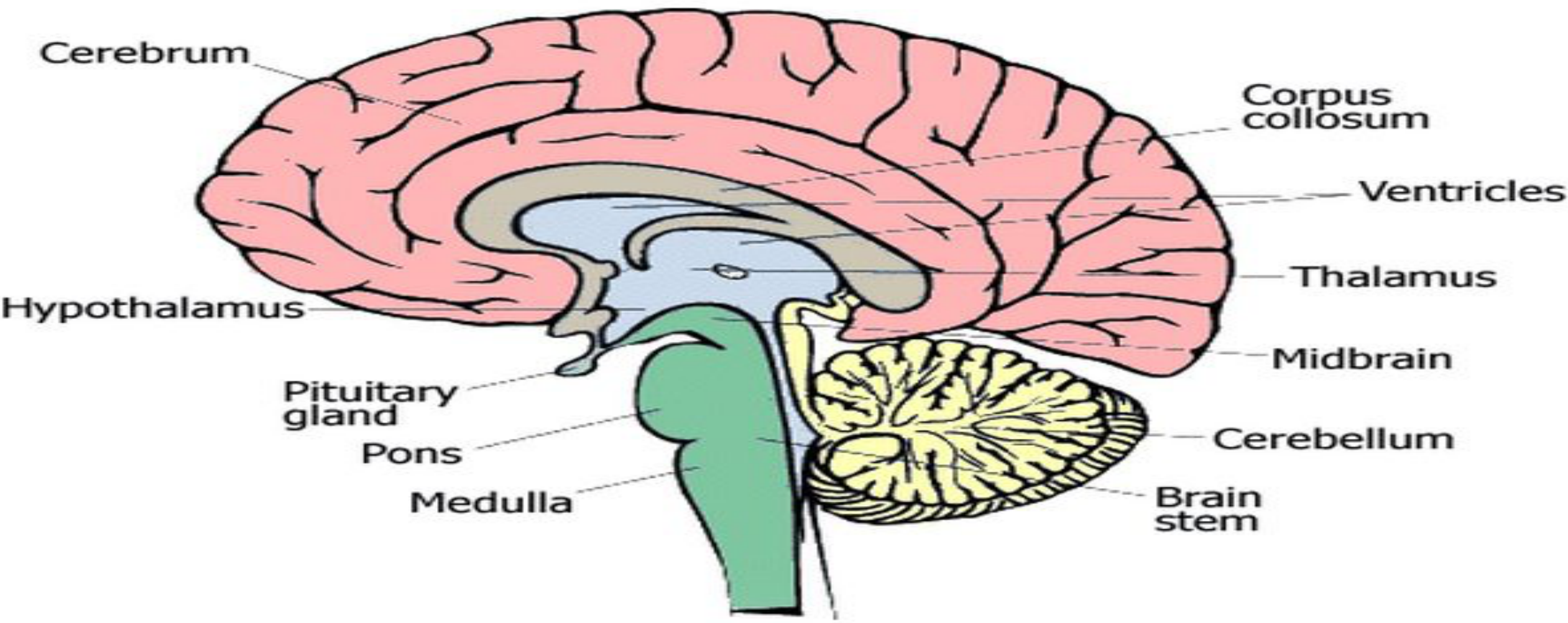
**Conditions that are degenerative
In nature that will have gradual deterioration in swallowing over time.**

Swallowing problems have been reported on patients who have suffered unilateral or bilateral brainstem, cortical, and subcortical strokes.

Swallow disorders by Site of lesion

Lower Brainstem (the Medulla)

- Results in significant oropharyngeal swallow impairment because of the location of the major swallow centers Within the medulla .



Cerebrum

Corpus collosum

Ventricles

Thalamus

Hypothalamus

Midbrain

Pituitary gland

Cerebellum

Pons

Brain stem

Medulla

Patients with medullary lesions exhibit:

- Near-normal oral control with significantly impaired triggering of the pharyngeal swallow.
- Absent pharyngeal swallow in the first week post stroke.
- Pharyngeal swallow begins to appear (usually in the second week post stroke) , but there is a significant delay in triggering the pharyngeal swallow (often 10 to 15 seconds or more)
- Thermal - tactile stimulation can be helpful .

-
- The more medical complications present the longer the swallow recovery period.
 - Some patients will not recover swallowing for 4 to 6 months post-stroke.
 - **These patients benefit from :-**
 - Thermal -tactile stimulation .
 - Head rotation to the side of the pharyngeal weakness.
 - Mendelsohn maneuver .
 - Range- of - motion exercises for laryngeal elevation .

Effect of high brainstem (pontine) stroke

- Hypertonicity appear in the pharynx .

Symptoms:

- Delay in triggering of the pharyngeal swallow or an absent pharyngeal swallow.
- Unilateral paresis/paralysis pharyngeal wall .
- Reduced laryngeal elevation with a severe cricopharyngeal dysfunction

- **Therapy:**

- These patients often do not respond typically to head rotation .
- Thermal -tactile stimulation may be helpful but may also increase oropharyngeal muscle tone.
- Massage to reduce muscle tone in the buccal musculature and in the neck, may be helpful prior to initiating swallowing therapy in each session.
- Recovery in these patients can be quite slow and difficult.

Effects of subcortical stroke

- May affect motor and sensory pathways to and from the cortex.
- Subcortical stroke usually result in mild delays (3 to 5 seconds) in oral transit time, And in triggering the pharyngeal swallow .
- A small number of these patients exhibit aspiration before and after the swallow.
- Recovery of full oral intake may take 3 to 6 weeks post-stroke if no medical complications are present.

Therapy:

- Swallowing therapy directed at improving the triggering of the pharyngeal swallow.
- Improving the range of motion of the larynx and tongue base is usually beneficial.

Effects of stroke in the cerebral cortex

- Stroke within **the anterior left hemisphere** of the cerebral cortex can result in apraxia of swallow.
- Mild to severe .
- Oral apraxia.
- Exhibit mild oral transit delays (3 to 5 seconds) and mild delays in triggering the pharyngeal swallow (2 to 3 seconds) .

- **Swallow apraxia therapy :**

- Sensory enhancement procedures such as :

-

- ✓ Increase bolus taste .

- ✓ Increasing pressure of the spoon on the tongue.

- ✓ Thermal -tactile stimulation .

Right hemisphere:

- Usually exhibits mild oral transit delays (2 to 3 seconds) and longer pharyngeal delays (3 to 5 seconds).

Therapy:

- Chin-down posture.
- Thermal - tactile stimulation for the pharyngeal delay .
- Supraglottic or super-Supraglottic swallow, to protect the airway .
- Motion exercises to improve laryngeal elevation

*Patients suffering right cortical strokes may be later in returning to oral intake than patients who have suffered left cortical strokes.

Why?

Effect of multiple strokes

- Exhibit more significant swallowing abnormalities.
- Oral function may be slower with many repetitive tongue movement and oral transit times of over 5 seconds .
- Delay in triggering the pharyngeal swallow is also usually more severe , taking over 5 seconds .
- Reduced laryngeal elevation.
- Reduced closure of the laryngeal entryway.
- Affected attention

Recovery of swallow post stroke

- In the non-complicated stroke patients, recovery was steady , and rapid with over 95% of the stroke subjects by 9 weeks post-ictus.
- Recovery is most rapid in the first 3 weeks post-stroke we should evaluate the patient's swallow function in the first week, and reevaluate at 3 to 4 weeks post-stroke.

Treatment / management strategies

- Postural changes.
- Changes in sensory input prior to attempts to swallow .
- Volume taste active exercises.

Swallowing problems following head trauma

- The swallowing problems of patients who have suffered head trauma can be quite complex because of the various types of neurologic injuries.
- The longer the coma, the more severe the swallowing problem.

-
- **Patient with head injuries exhibit a variety of oral and pharyngeal disorders, including :**
 - ✓ Reduced lip closure .
 - ✓ Reduced range of tongue motion with poor bolus control .
 - ✓ Abnormal oral reflexes (bite reflex) .
 - ✓ Delay in triggering the pharyngeal swallow .
 - ✓ Absent pharyngeal swallow.

-
- ✓ Reduced laryngeal elevation .
 - ✓ Reduced closure of the airway entrance
 - ✓ Reduced tongue base motion .
 - ✓ Reduced airway closure .
 - ✓ Reduced cricopharyngeal opening .
 - ✓ Pharyngeal wall paresis.
 - ✓ Reduced velopharyngeal closure.
 - ✓ Aspiration may be lead to pneumonia (if it lasts more than year) .
 - ✓ Reduced sensation.

-
- The recovery of swallowing after head injury has not been well documented .
 - Counseling of the patient with head injury and his family about different strategies may be necessary .
 - **Patients with head injuries and cognitive difficult need compensatory strategies such as :**
 - ✓ Postural change
 - ✓ Enhanced sensory input
 - **Patient with a head injury has:**
 - ✓ Cognitive difficulties which makes the understanding of some swallow therapy procedure, such as swallow maneuvers difficult .

• **Some techniques can be taught to the family to increase the frequency of therapy such as:**

- ✓ Motion exercises.
- ✓ Thermal tactile stimulation .
- ✓ Changing diet.

*Patients with too severe dysphagia may remain on non-oral feeding on limited oral intake, and they should be reassessed every 6 months to 1 year .

Swallowing Problems After Cervical Spinal Cord Injury

- **Problems are usually pharyngeal in nature and may include :**
 - ✓ Delay in triggering the pharyngeal swallow .
 - ✓ Reduced laryngeal elevation.
 - ✓ Reduced tongue base motion .
 - ✓ Pharyngeal wall dysfunction .

Damage which occurs at cervical vertebrae 4, 5 or 6 causes :

- Poor laryngeal movement .
- Reduced cricopharyngeal opening.

Damage which occurs at cervical vertebrae 1 or 2 causes :

- No sensory awareness .

*If the patient with a cervical spinal cord Injury complains of any swallowing disorder, this requires an in depth physiologic assessment (usually a radio-graphic study).

*Postural changes are usually not possible.

***Sensory enhancement therapies and swallow maneuvers are often most helpful .**

Cervical Bracing



Swallowing Problems Associated with Cerebral Palsy

- Children may exhibit inappropriate oral reflexive behaviors include:
 - ✓ Inability to hold material in a cohesive bolus .
 - ✓ Disorganized lingual movements .
 - ✓ Particles of food spread throughout the oral cavity .
 - ✓ Particles may fall into the pharynx and then into the open airway.
 - ✓ Delay in triggering the Pharyngeal swallow .

-
- Less information is available on the occurrence of swallowing disturbances in the pharyngeal and esophageal stages of swallowing.
 - Cricopharyngeal dysfunction or abnormal opening of the UES is rarely a problem in these individuals

Management strategies may include :

- Oromotor therapy .
- Thermal - tactile stimulation.
- Diet change (thickened liquids and purees).

*The swallowing therapist should define the optimal therapy and eating strategies, and teach them to the caregivers.

**Swallowing problems
associated with
Degenerative disease**

-
- May begin early or later in the disease process.
 - May worsen over the course of the disease.

-
- It is important that the pt's swallowing be regularly evaluated so that:

1- Progressively worsening function can be compensated for as much as possible.

2- The patient is put at minimal risk of serious aspiration and pulmonary problems.

3- An optimal nutrition and hydration status is maintained by initiation of appropriate non-oral feeding methods when needed.

Alzheimer's disease (p.330-331)

ALS (Amyotrophic
Lateral Sclerosis) (p.332-
333)

Parkinson's disease (p.334-336)

Post-polio Syndrome (p.336)

MS (Multiple Sclerosis) (p.336-337)

Myasthenia Gravis (p.337-338)

Muscular dystrophy (p.338-339)

Dystonia(p.339)

Chronic Obstructive Pulmonary Disease (p.341)

Medical Treatment for Swallowing Disorders

Different techniques:

1. Surgical reduction of Osteophytes
- 2. Procedures to Improve of the airway closure at the Vocal folds**
- 3. Laryngeal Suspension for Reduced Laryngeal Elevation**
4. Cricopharyngeal Myotomy
5. Botulinum Toxin Injection

Procedures to Improve of the airway closure at the Vocal folds

- Injection of a substance into the vocal folds in order to improve closure at the VF and to protects the airways.
- The mass is added to the damaged or the reconstructed VF, why?
 - ✓ Improve contact with the other.
 - ✓ Movable.
 - ✓ More normal VF.

To whom we use this procedures ?


- ✓ Pts. Whose laryngeal adduction for airway protection is not sufficiently improved with exercise.
- ✓ Head and neck surgical patients, especially pts. With partial laryngectomy whose the remaining tissue in the larynx are insufficient to adduct and protect the airway.
- ✓ Neurological pts. With inadequate VF closure, such as, Parkinson disease and ALS.

- **Limitation:**

- ✓ Denseness of tissue → place

Laryngeal Suspension for Reduced Laryngeal Elevation

If the larynx does not lift and move forward adequately.



Laryngeal suspension is attempted surgically

- **To whom pts.:**

- ✓ Head and neck cancer pts.

- ✓ Rarely in neurologic pts.

https://www.youtube.com/watch?v=F_yornGArUQ&feature=emb_logo

Techniques for Non-oral Feeding

-
- **There are different types of non-oral tubes.**
 - **GERD.**
 - **Temporarily.**

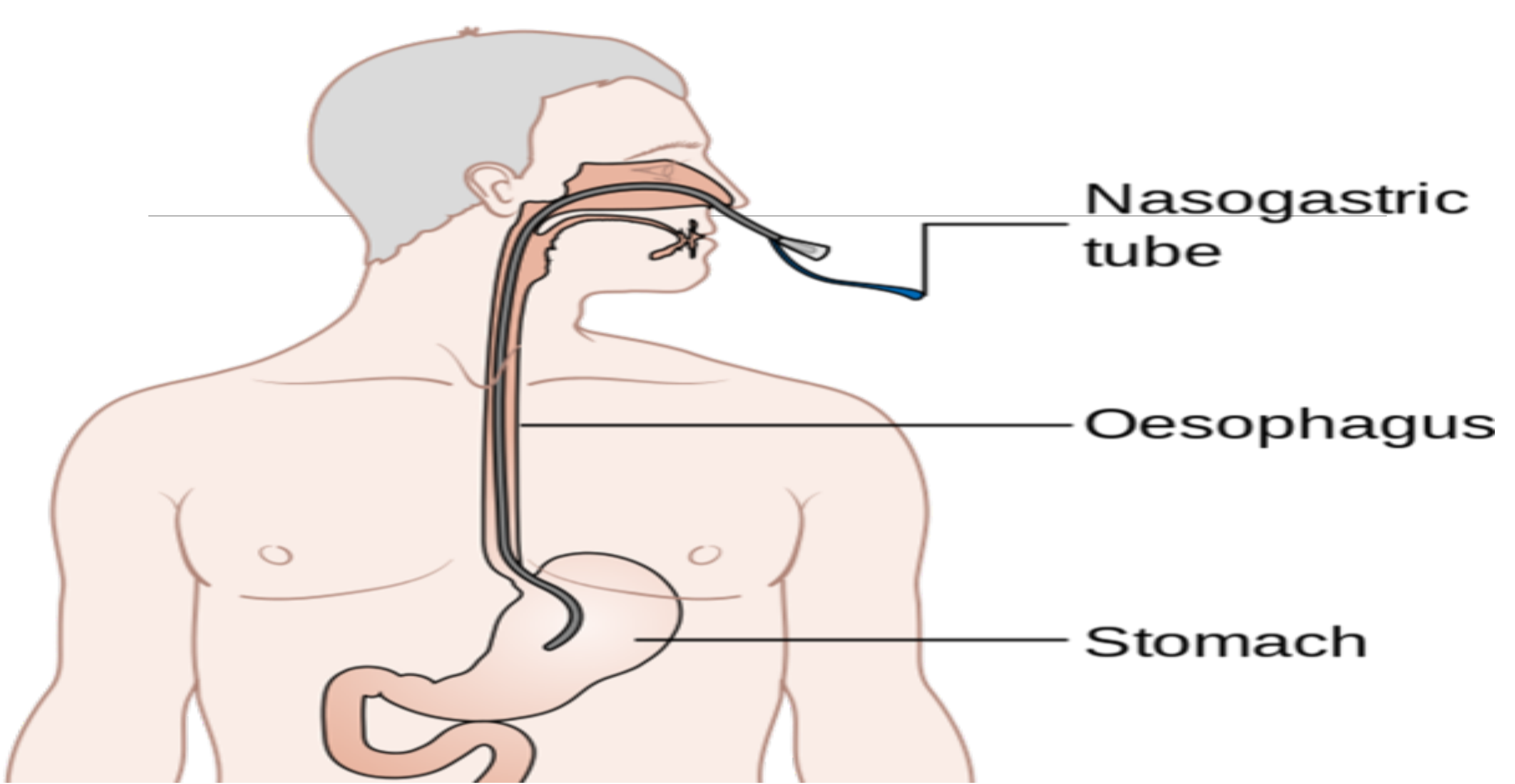
1- Nasogastric Feeding

- A tube placed through the nose, pharynx, and esophagus into the stomach.
- Narrow tube → minimal irritation
- Food is passed through the tube into the stomach.
- The number of feedings per day and the amount of food given per feeding vary.
- Water for cleaning.
- Upright position 1 hour after a meal, **why?**

-
- Temporarily → replaced with other after 3 to 4 months (some pts. may have it for 5 or 6 month).
 - The patients and their family may be taught to place the nasogastric tube for each meal and to remove it after feeding.

Limitations:

- ✓ GERD**
- ✓ Irritation**
- ✓ Prepared liquid diets → expensive**



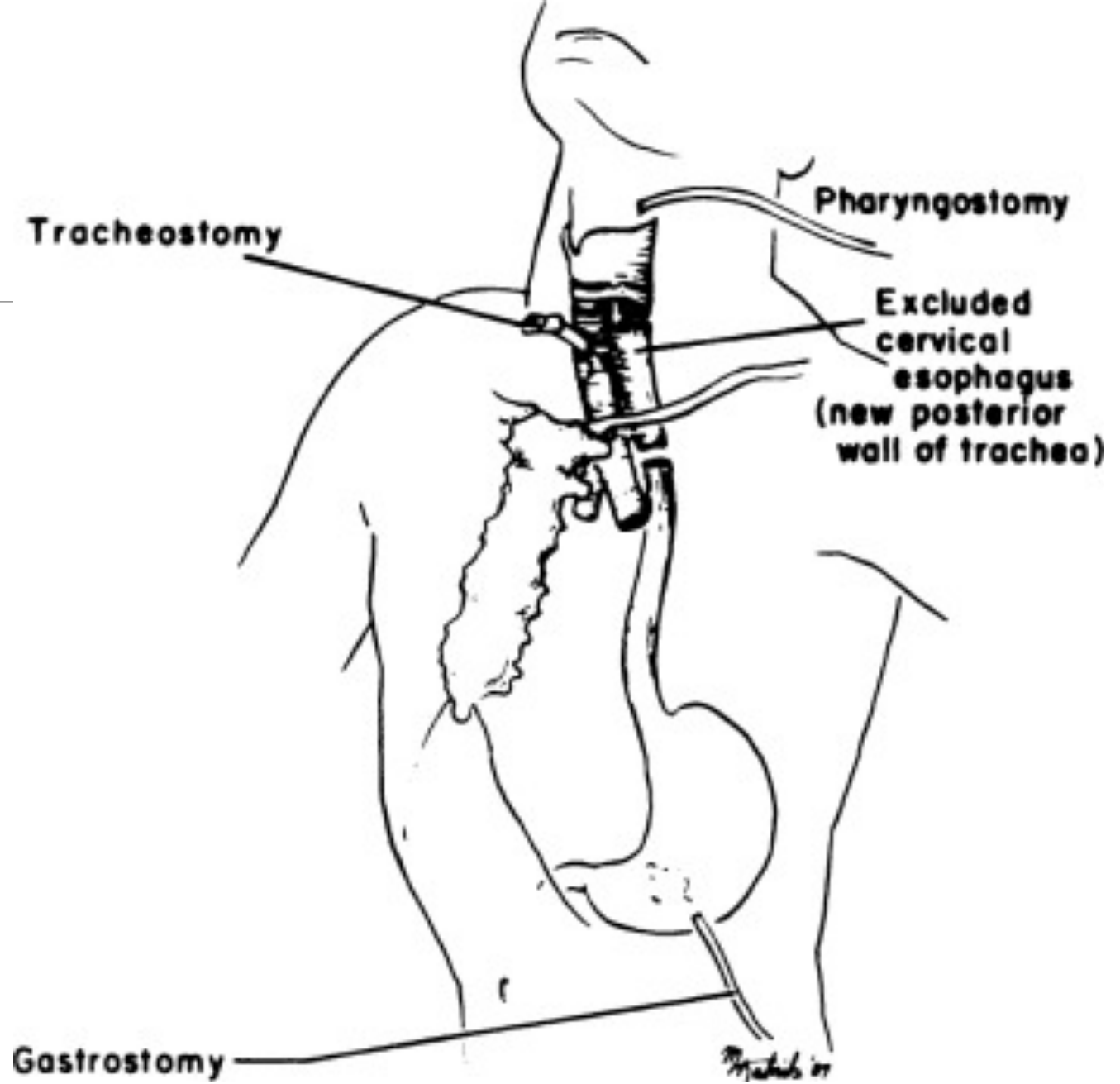
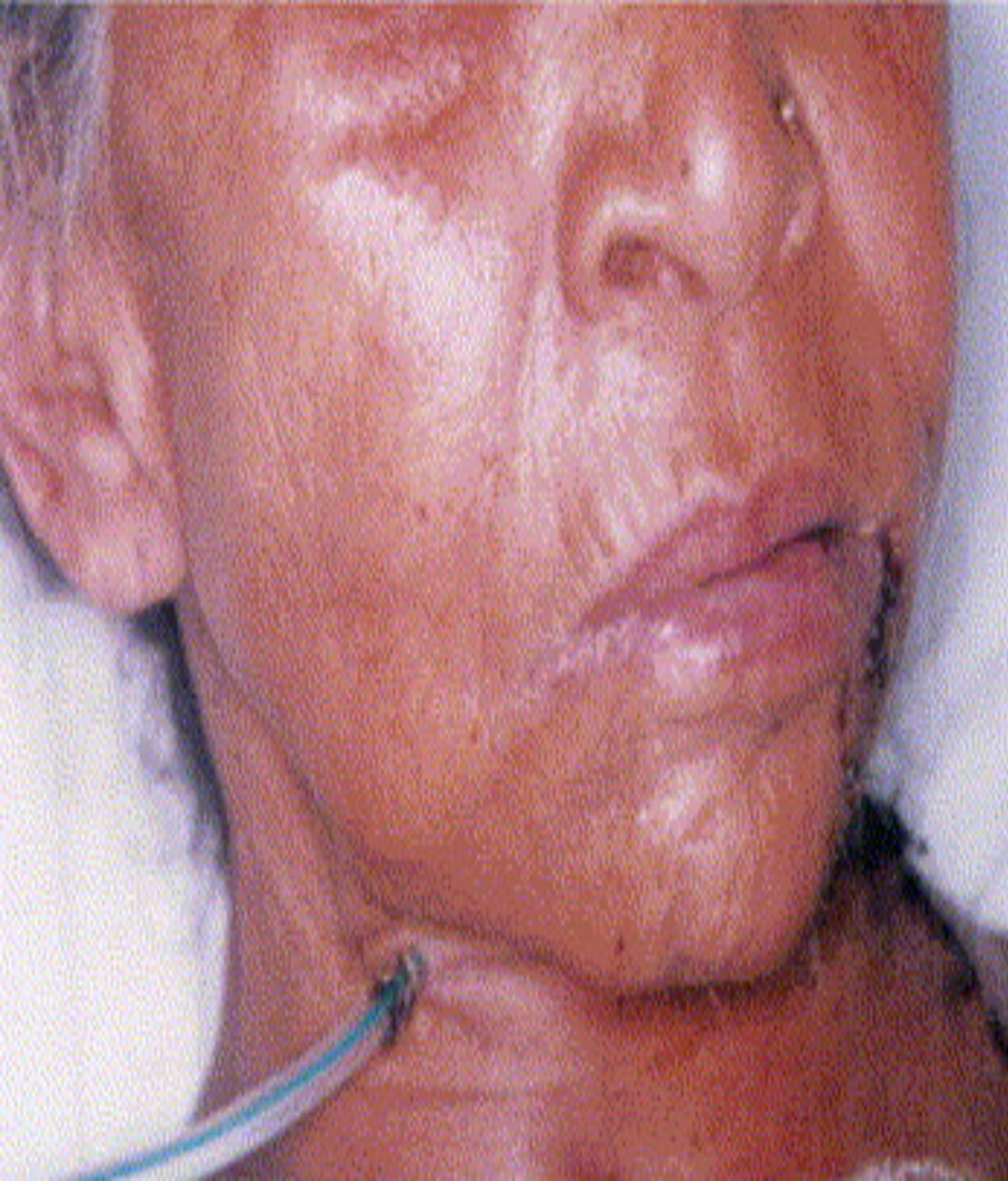Nasogastric tube

Oesophagus

Stomach

2- Pharyngostomy

- Hole from the skin into the pharynx → esophagus → stomach.
- Elimination of the tube through the nose (advantage over the nasogastric tube).
 - ✓ Irritating.
 - ✓ Less acceptable socially.
- **Disadvantage:**
 - ✓ Creating a hole.
 - ✓ Pharyngeal scarring.
- **Patients:**
 - ✓ Some head and neck cancer patients.



3- Esophagostomy

- From the skin into the esophagus → stomach
- Advantages and Disadvantages.

4- Gastrostomy

- General surgical procedure with general anesthetic or under local anesthetic.
- External opening in the abdomen leading into the stomach.
- Long term solution to a severe swallowing disorders.
- **Advantage:**
 - ✓ Removes the risk of nasal and pharyngeal irritation.
- **Disadvantage:**
 - ✓ The stoma can leak.
 - ✓ Become infected.
 - ✓ Uncomfortable.

Criteria for implementation the Non-oral feeding procedure

1. Aspirating more than 10% of all food consistencies.
 2. Longer than 10 seconds to swallow a single bolus.
 3. If the swallowing disorder is anticipated to be:
 - ✓ Short term (1 month or less) → nasogastric tube
 - ✓ More than one month → gastrostomy (unless the pt. can use the nasogastric tube appropriately)
- ❖ Sometimes PEG is used as short term dysphagic patients.

Multidisciplinary Management of Dysphagia

- Etiologies

- Complexity of management of the dysphagic patients.

- Neurologist
- Otolaryngologist
- Pulmonologist

- Pediatrician
- Physiatrist
- Gerontologist
- Maxillofacial prosthodontist
- Dentist
- Pharmacist
- OT
- PT
- Dietitian
- Physician
- Nursing staff
- Feeding staff

Models of communication

- 1- weekly face to face meetings
- 2- telephone conversations
- 3- Electronic mail

Efficacy of multidisciplinary team

Staff Education

Swallowing Disorders After Treatment For Oral And Oropharyngeal Cancer


Two treatment modalities


1- Surgical resection

2- Radiotherapy with or without chemotherapy

3- Combination

Each treatment may affect swallowing

-
- Smaller tumors
 - Larger tumors
- 

-
- Simple resection
 - Composite resection
 - Rehabilitation and construction
- 

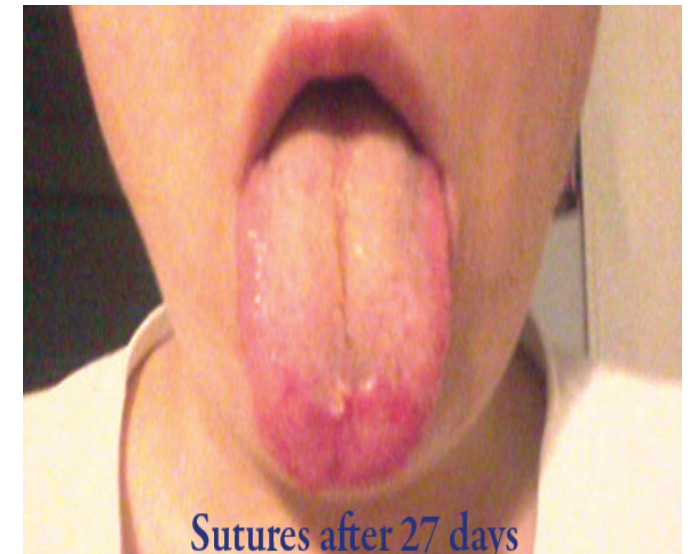
Pretreatment Dental assessment

- Dental evaluations

Typical Tumor Locations and Resections in the Oral Cavity

1. Floor of the mouth
2. Alveolar ridge
3. Tongue
4. Tonsils
5. Base of the tongue
6. Hard and soft palate

Small resection → the remaining soft tissues are pulled together and sutured
Bigger resection → tissue from another part of the body



Rehabilitation

- Salivary flow
 - Speech
 - Swallowing
- 
- problems

- Reduced Salivary flow
- Sensory loss
- Range of motion of the tongue
- Jaw motion

Advanced oral cancer

- Surgery → swallowing therapy → radiation
- Radiation 4-6 weeks postoperatively for 6 weeks
- At almost 4 weeks from the radiation → worsening of swallowing and speech
- The patient is depressed → may withdraw from rehabilitation
- Important to continue regular swallowing intervention

Oropharyngeal Cancer

- Cancer in the oropharyngeal region often affects the base of tongue and the pharyngeal wall
- Early intervention
- Suture lines have healed in order to enable exercise (10-14 days post surgery)

Optimal Schedule for Rehabilitation

1. Treatment selection as the first line of Rehabilitation
2. Pretreatment counseling
3. Schedule for posttreatment intervention

Treatment selection as the first line of Rehabilitation

- Different effects on speech and swallowing
- Treatment planning
- Rehabilitation specialists (SLP, maxillofacial prosthodontist, and social worker)

Pretreatment counseling

- Counseling prior to treatment
- SLP pre operative counseling:
 - Swallowing screening if not VF
- Dental consultation
- Psychosocial assessment
- Reduce the pt's and the family fears

Schedule for posttreatment intervention

- **Surgery**
 - Counseling 2-3 days postoperatively
 - Aggressive exercises 7-14 days based on the lesion and the nature of surgery
 - MBS
 - Dental status
 - Psychosocial counseling
 - Physical therapy if needed
 - Plan and therapy

-
- Postoperative radiotherapy or radio and chemo in combination
 - Rehab intervention throught the period of radiation
 - If there are sideeffects try to continue excercises to preserve range of motion and flexibility of tongue,lips,jaw,larynx, and pharynx.

Swallowing Disorders Related to Specific Surgical Resections and Reconstruction Techniques

- The most important information for the SLP to know:
 - 1) The exact nature of the resection that was necessary to totally remove the tumor
 - 2) The exact nature of the reconstruction of the oral cavity
- < 50% of their tongue resected in the surgery, the nature of the reconstruction is the major determinant of the pattern of function.
- > 50% of their tongue resected in the surgery, the extent of resection and the nature of the reconstruction determine the functional abilities of the patient.

Swallowing Disorders After Radiotherapy to the Oral Cavity and Oropharynx

- Reduced saliva flow
 - Xerostomia (reduced speed of tongue movement-> delay in oral transit time and a change in pattern of tongue movement contributing to a delay in triggering the pharyngeal swallow)
 - Edema
 - Mucositis
-
- Medications are partially effective

Therapy:

1. Super-supraglottic swallow
2. Mendelsohn Maneuver

General Principles of Swallowing Therapy with Treated Oral Cancer Patients

- The SLP must counsel the patient prior treatment to discuss swallowing problems.
- It is impossible to know the exact effect that will be present after treatment
- The patient is responsible for his rehabilitation
- In the surgical treated patients, swallowing therapy including oromotor exercises are necessary to build muscle control for swallowing, begins when the surgeon indicates that the patient starts to heal
- Swallowing therapy is usually begun when the patient has a nasogastric tube or other non oral feeding in place to maintain nutrition.
- Team work