



Diseases of the middle ear



Diseases of the middle ear


❖ Otitis media

Definition: Inflammation of the *middle ear cleft* ((**not** middle ear cavity)).



Classification

1. Acute: less than 3 weeks (or one month roughly)
 - a. Nonsuppurative → There is No pus
 - b. Suppurative → There is pus & indicates tympanic membrane perforation.
2. Subacute: 3 weeks to 3 months (or up to 90 days)
 - a. Nonsuppurative
 - b. Suppurative



3. Chronic: More than 3 months (or more than 90 days).

a. Nonsuppurative

(AKA: Secretory OM / Serous OM/ Exudative OM/ OM with effusion (OME) / Blue ear)

** In adults, unilateral secretory OM is nasopharyngeal carcinoma until proven otherwise.



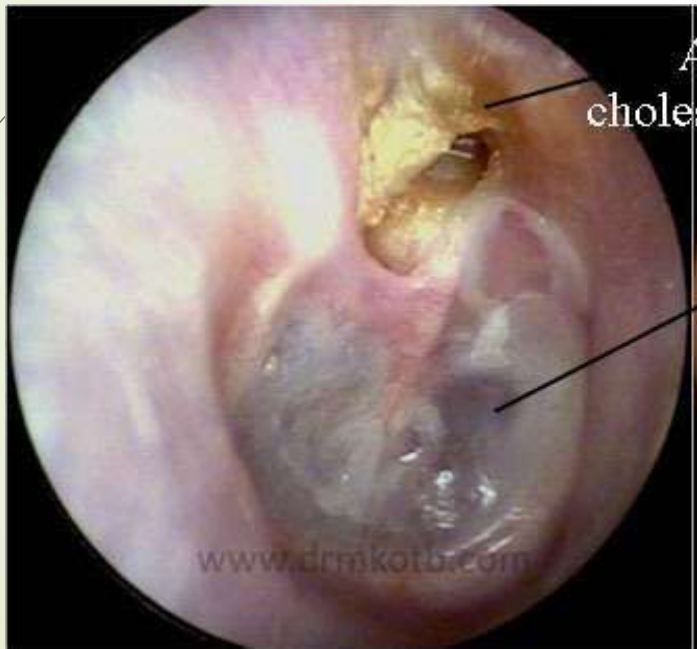b. Suppurative:

Type 1 (Safe type): Tubotympanic type, there is central perforation & is **not** associated with cholesteatoma.

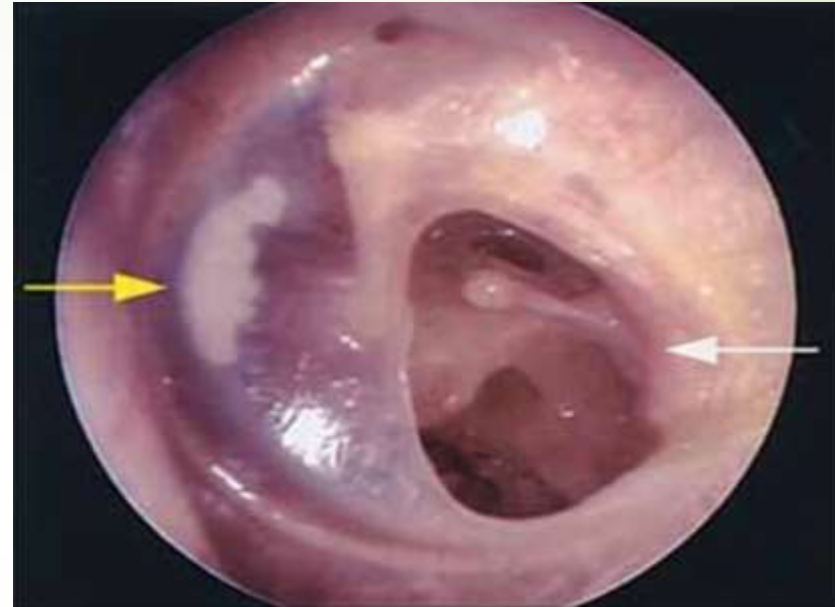
Type 2 (Unsafe type): atticoantral type, there is marginal or peripheral perforation & is associated with cholesteatoma.



atticoantral type



Tubotympanic type






Epidemiology:

- Account for almost 1/3 of the office visit to pediatricians
- Peak incidence 6-24 month of life
- More common in boys and in low socioeconomic persons
- Incidence increased in children with: cleft palate



Risks factors:

1. Young age
 2. Bottle feeding
 3. Pacifier
 4. Day care attendance
 5. smoking
 6. Craniofacial anomalies
 7. Genetics tendency
 8. Allergic disease
 9. Immunodeficiency
- 




Pathophysiology

- Acute otitis media usually arises as a complication of a preceding viral upper respiratory infection (URI).
- The secretions and inflammation cause a relative obstruction of the eustachian tubes (→ ***eustachian tube dysfunction***).
- Normally, the middle ear mucosa absorbs air in the middle ear. If this air is not replaced because of obstruction of the eustachian tube, a negative pressure is generated, which pulls interstitial fluid into the tube and creates a serous effusion.
- This effusion of the middle ear provides a fertile media for microbial growth. If growth is rapid, a middle ear infection develops.



Microbiology

- 80% bacterial
 - 20% viral
- 



Diagnosis

- **Acute OM:**
- • Hx: preceding URTI, fever, otalgia, hearing loss, otorrhea .
- • In neonate: irritability, tugging at ear, poor feeding, vomiting and diarrhea.
- • Exam: otoscopy, is the gold standard. Shows loss of all normal marks on tympanic membrane, change colour, bulging of membrane, normal or hypomobile. Decreased mobility is the most important sign → tympanometry .



Chronic OM with effusion: otoscopy shows:

1. Bulging tympanic membrane.
2. Retraction of tympanic membrane (prominent handle of malleus).
3. Tympanic membrane mobility loss.
4. Air fluid level behind the tympanic membrane.
5. Air bubbles behind the tympanic membrane.
6. Bluish ear drum.



Treatment

Acute OM

- Antibiotics
- paracetamol and ibuprofen for fever

Recurrent AOM

- Chemoprophylaxis antibiotics
- *Myringotomy and tube insertion*
- Adenoidectomy



OME (OM with effusion)

- MEE > 3 moths or associated hearing loss, vertigo, frequency, ME pathology, discomfort
- Antibiotics
- Antibiotics + steroid
- Myringotomy & +/- adenoidectomy



Complications:


- Intratemporal: hearing loss (CHL, SNHL or mixed), TM perforation, cholesteatoma, mastoiditis, labyrinthitis, adhesive OM, facial paralysis.
- Intracranial: meningitis, extradural abscess, subdural empyema, brain abscess, lateral sinus thrombosis.

The most common complication is mastoiditis.

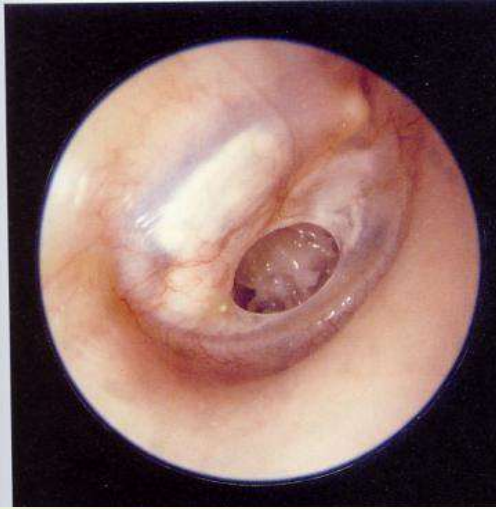The most common cause of hearing loss is otitis media.



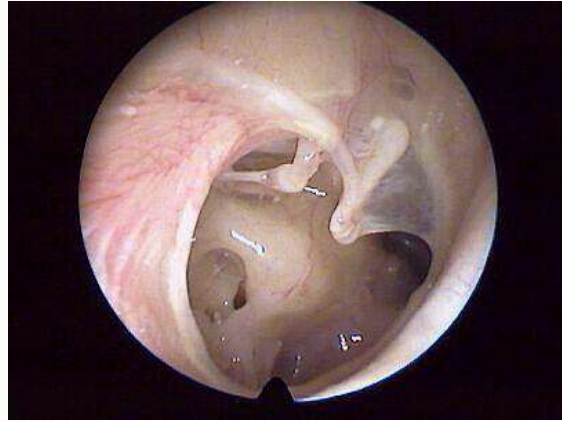
TM perforation

- Pathogenesis
 - 1. Recurrent acute OM: brings to chronic changes in middle ear and tympanic mucosa, leading to perforation.
 - 2. Traumatic perforation.
- 

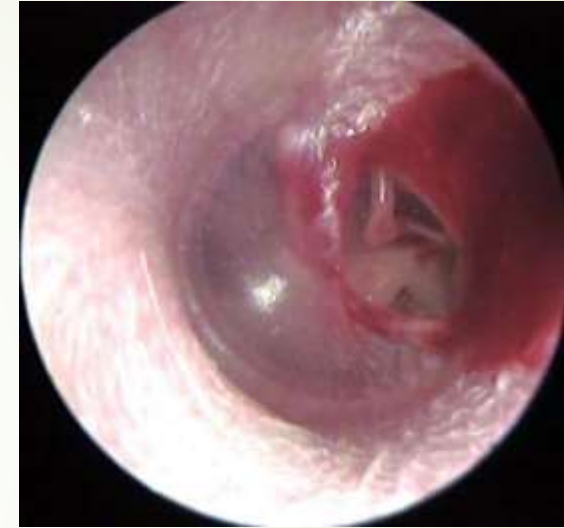Chronic OM
(subtotal
perforation)



Total perforation



Traumatic
perforation





Symptoms:

1. Hearing loss (conductive). Perforated lose 20% of its hearing capacity.
2. Recurrent otorrhea.
3. Occasionally pain



Treatment:

1. **Ear protection from water.**
2. Nasal decongestant to prevent Eustachian tube dysfunction.
3. Antibiotic for 7 days is controversial.
4. Wait for **3 months** to close spontaneously (90% of heals spontaneously).
5. If not closed after 3 months, do **tympanoplasty**



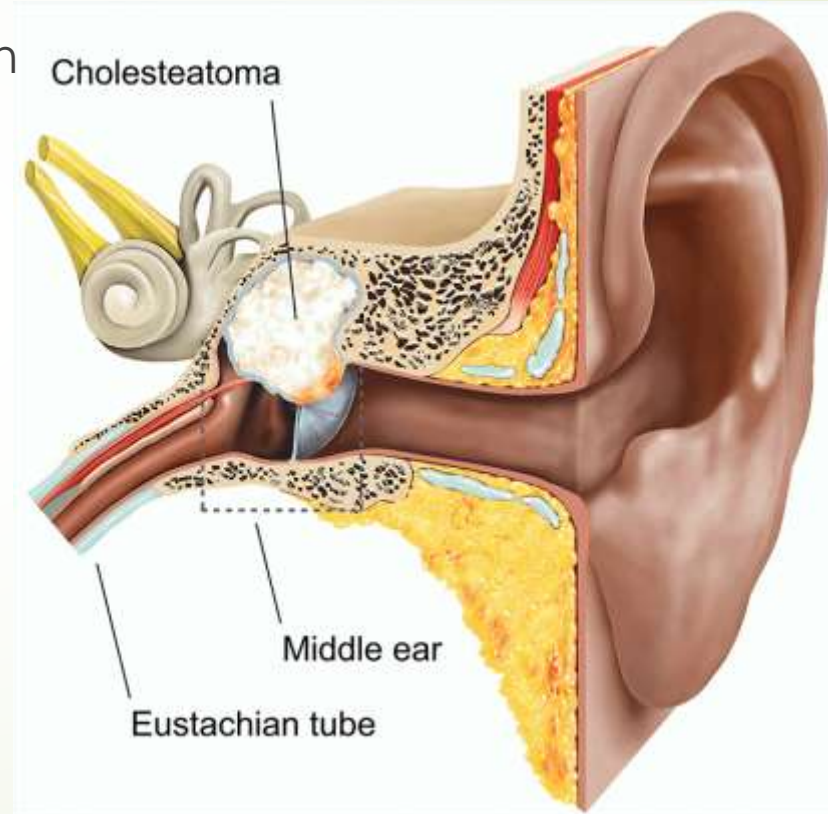
Prognosis:

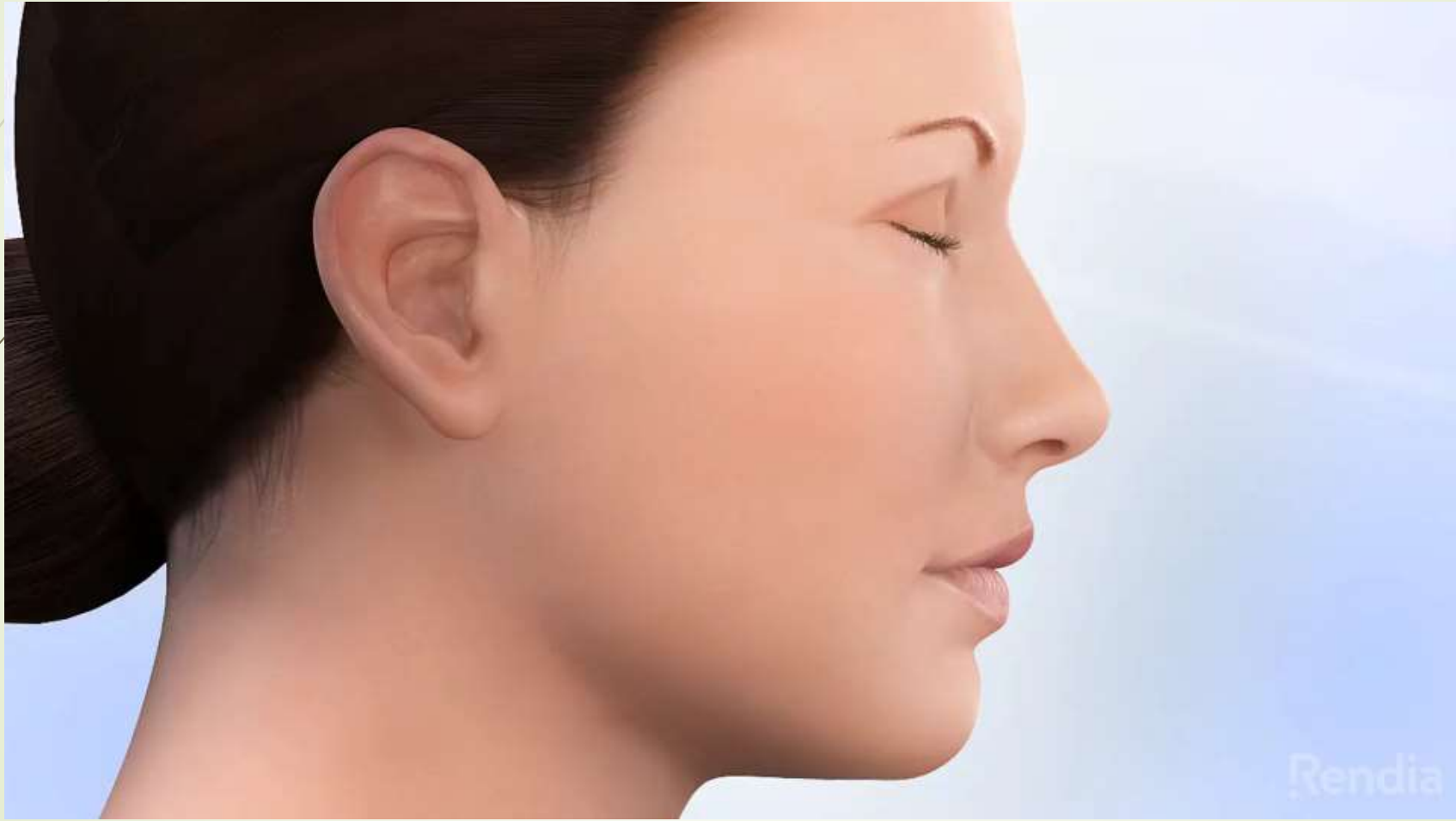
- ✓ Central perforation has **better** prognosis than peripheral perforation.
- ✓ Perforation of pars flaccid has worse prognosis than pars tensa, although not affecting hearing initially.

Cholesteatoma

Definition:

Chronic O.M. with accumulation of keratin and debris in middle ear and mastoid.

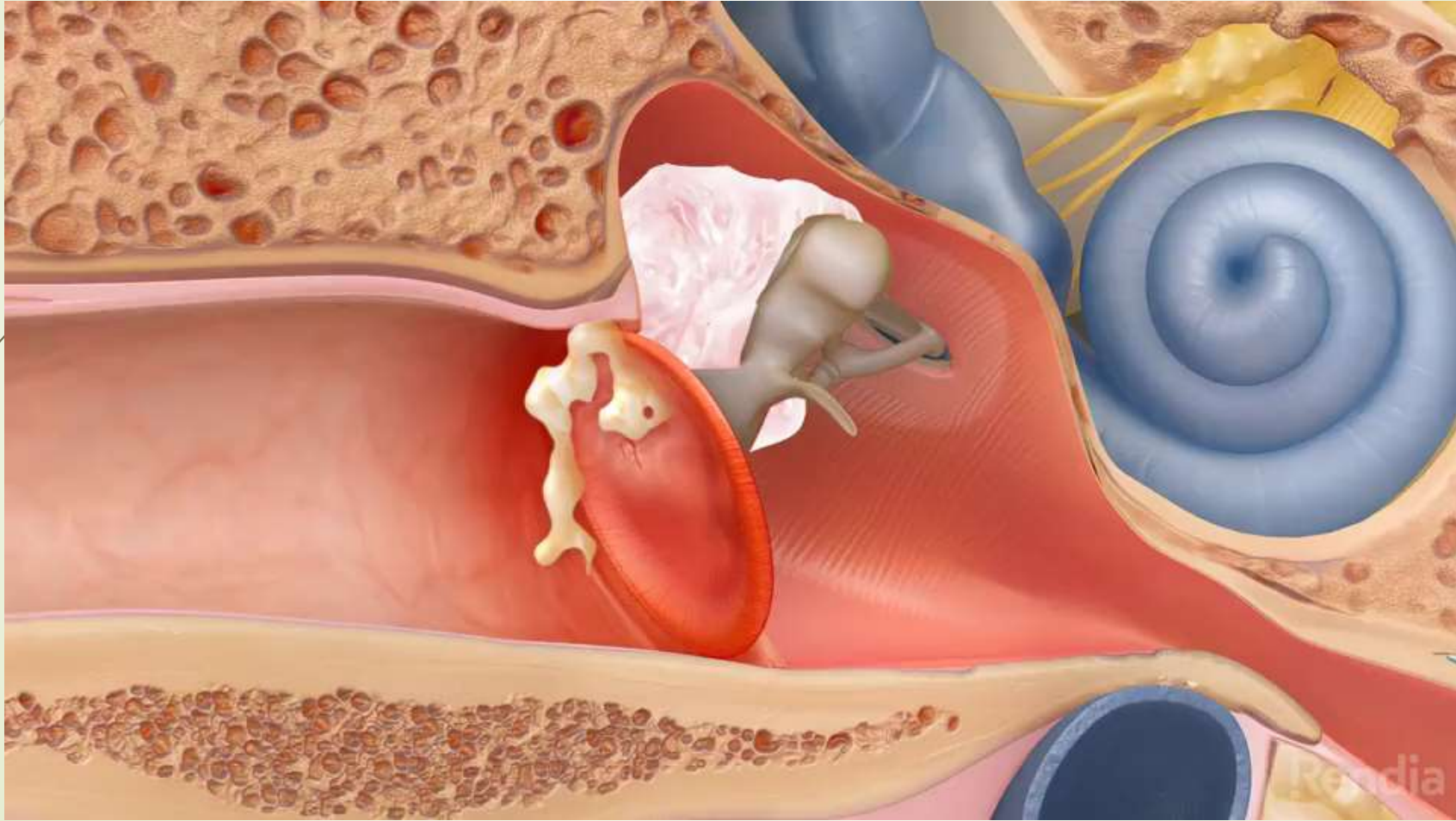







Pathogenesis


- Collection of keratin where it is normally not found (epidermis in a wrong place).
- { In the middle ear, normally there is No skin, there is only mucosa lined with Pseudostratified squamous ciliated mucosa (respiratory mucosa)}.
- Cholesteatoma is dangerous, due to enzymatic activity in the cholesteatoma which causes destruction to the bone leading to facial palsy, & may eventually reach the brain causing brain abscess.
- Therefore, it needs aggressive treatment !



- 
- There are two types:
 - 1. Congenital : Remnant of the neural tube (ectoderm) in the middle ear due to neural tube defect.
 - 2. Acquired : 3 theories:
 - a. *Primary*: Retraction pocket theory: In any middle ear pathology, there is Eustachian tube dysfunction, resulting in a *negative middle ear pressure* causing the tympanic membrane to be pulled medially mostly at the pars flaccid (retraction).
 - b. *Secondary*: Migration theory: where there is marginal perforation in the tympanic membrane allowing the skin to enter to the middle ear (migrate).
 - c. Metaplasia of the respiratory mucosa to keratinized squamous epithelium.
 - ** a & b are more common than c.



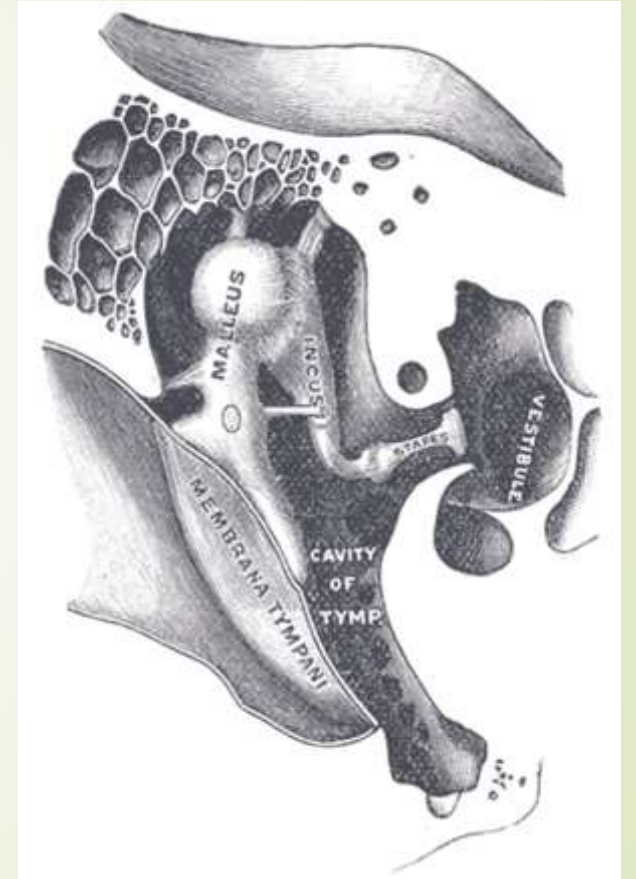
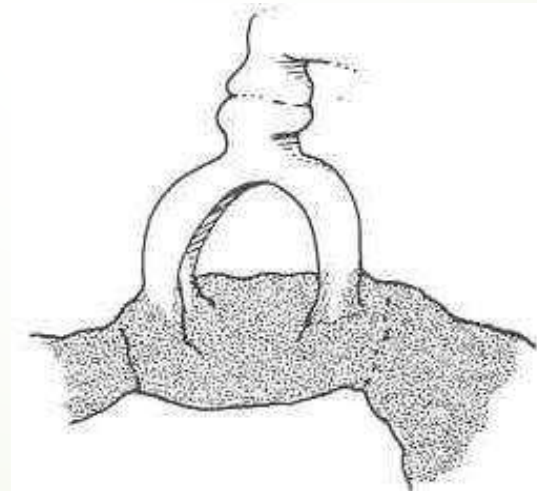
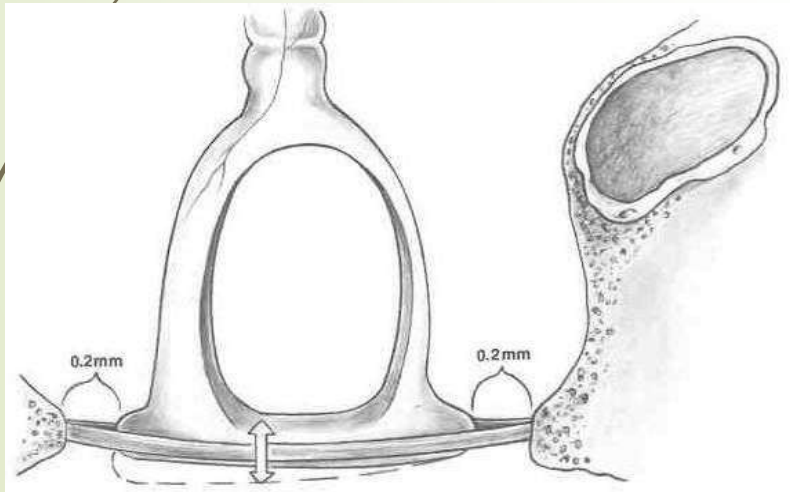
Complications:

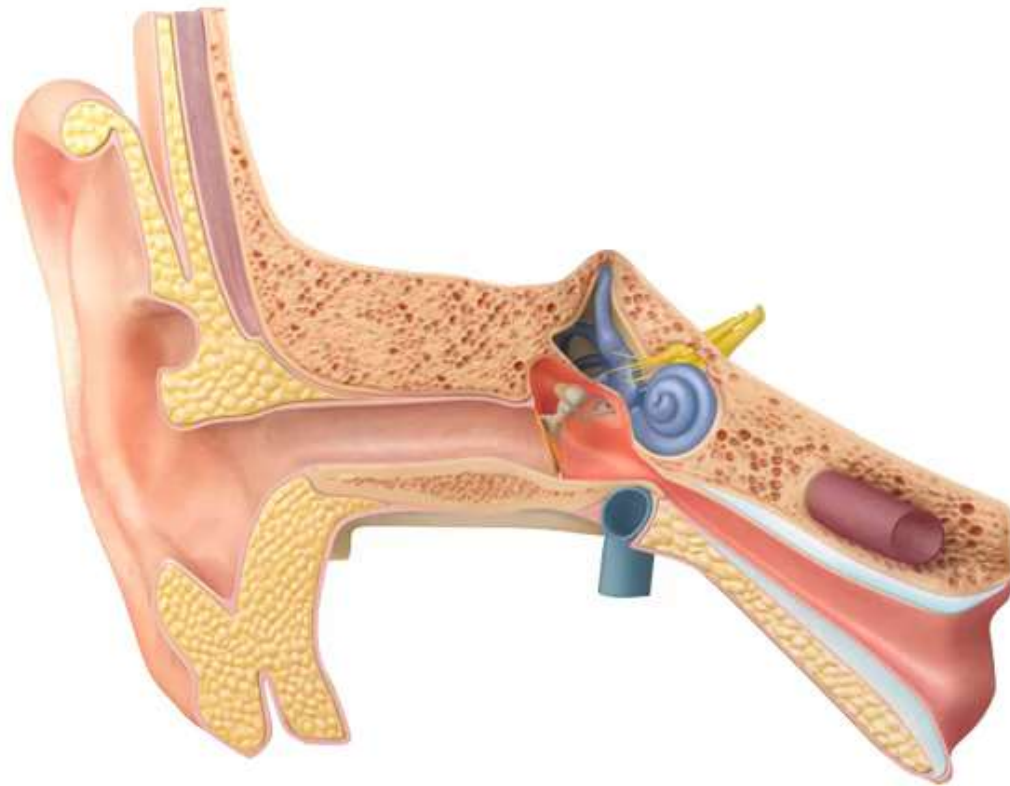
- ▶ Slowly destructs ossicles, invades middle ear and mastoid structures, invades CNS, inner ear, facial canal.
 - ▶ Treatment:
Mastoidectomy
- 

Otosclerosis

► Definition:

Sclerosis of the joints between the ossicles







Pathogenesis:

- Osteolysis followed by new osteogenesis.
Most frequent between stapes footplate and oval window.
- Male: Female → 1:2
- Undergoes progression during pregnancy, suggesting hormonal factor as etiology.
- 50% hereditary, 50% sporadic.




Symptoms

- **Tinnitus**
- **Vertigo and Dizziness**
- **Aural Fullness**
- **Otalgia (ear pain).**
- **Hyperacusis (an abnormal sensitivity to sound).**
- **Usually starts in one ear and then moves to the other. This loss may appear very gradually.**
- **Note:** a patient's audiogram who was diagnosed with otosclerosis always has a notch on 2000 Hz (cahart notch).

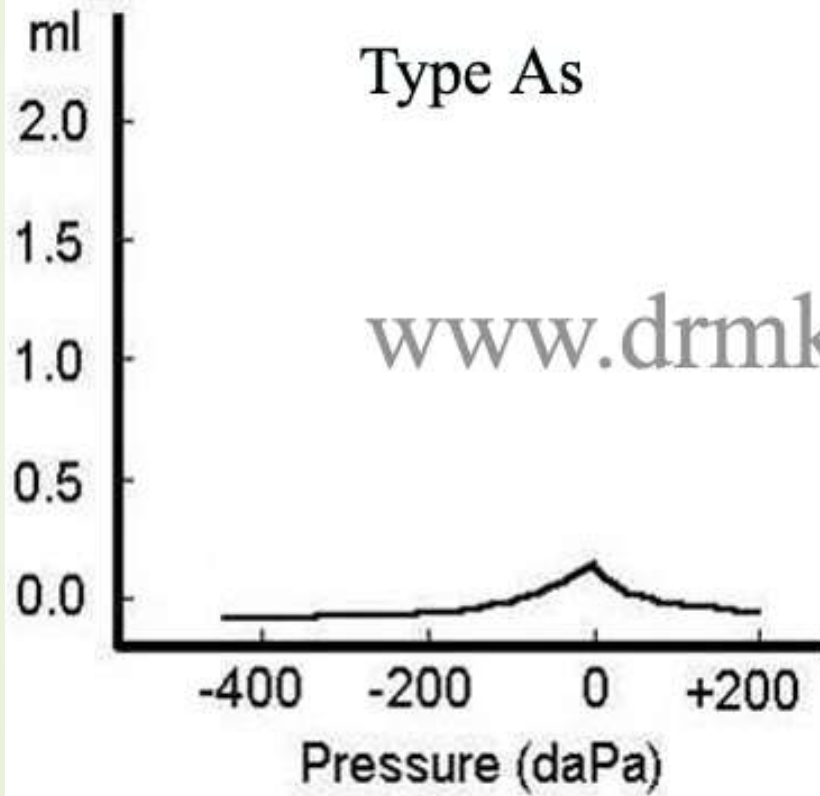


Diagnosis

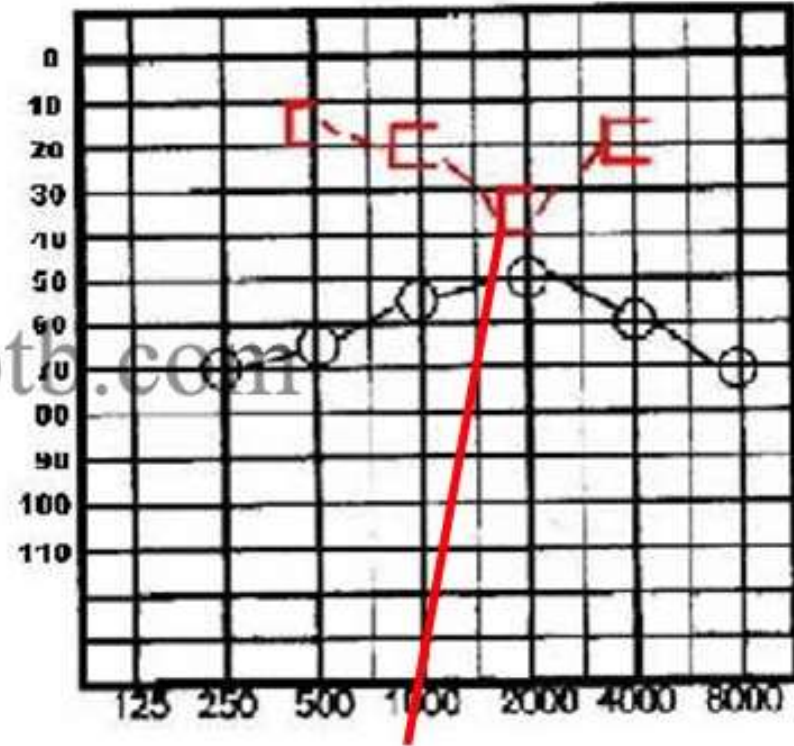
- Diagnosis is usually made by a combination of family history, progressive conductive hearing loss pattern.
- Hearing tests
- Acoustic reflexes may eventually be absent.
- Tympanometry often shows stiffening of the ossicular chain (A,As).
- Dizziness can occur in otosclerosis (in about 15% of patients).
- A CT scan may be the only way to document otosclerosis early in the disease.

- 
- In pure-tone audiometry, this manifests as air-bone gaps on the audiogram (i.e. a difference of more than 10 dB between the air-conduction and bone-conduction thresholds at a given test frequency).
 - the largest increase in bone-conduction threshold (around 15 dB) occurs at 2kHz frequency – the resultant notch is called *Carhart's notch* and is a useful clinical marker for medial ossicular-chain fixation.

Tympanogram



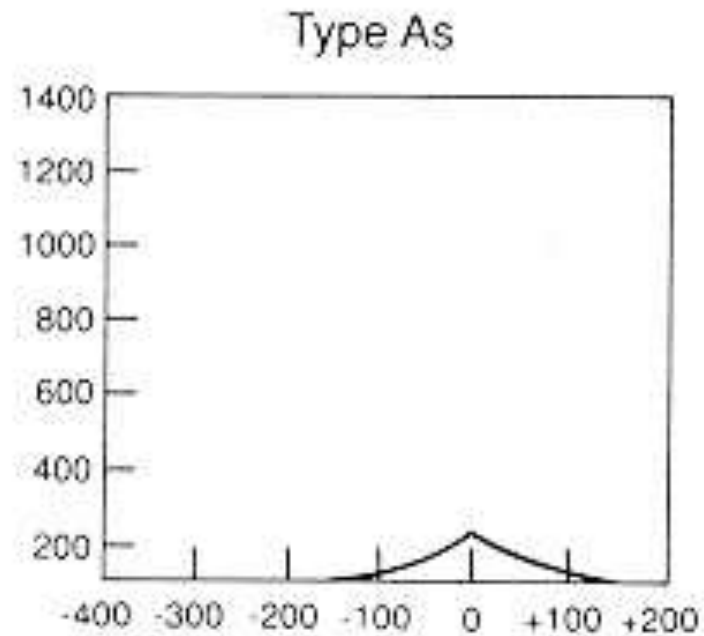
Audiogram



Carhart notch

Audiological investigations in Otosclerosis

- Therefore, otosclerosis may only slightly reduce the admittance, resulting in either a shallow tympanogram (type AS), or a normal tympanogram (type A). Otosclerosis increases in the stiffness of the middle-ear system, raising its resonant frequency.







acoustic reflex


- ▶ Also, a conductive pathology will attenuate the test stimuli, resulting in either elevated reflex thresholds or absent reflexes when the stimulus is presented in the affected ear and measured in the other ear.

Treatment

Treatment for hearing loss resulting from otosclerosis depends in general on the length and severity of the condition :

1. Medicine: sodium fluoride in conjunction with vitamin D is sometimes prescribed by a doctor to help slow the loss of hearing. There is some debate on the effectiveness of this treatment. Often a fluoride treatment will be given in conjunction with another treatment, a hearing aid or as after surgery care instructions.
2. Hormone Inhibition: A less known preventative treatment is to regulate female hormones thought to play a part in the worsening of this condition.

- 
- 
3. Hearing aids: Although hearing aids cannot cure otosclerosis, they can help treat the largest symptom (hearing loss).
 4. Surgery : Surgical operations are widely performed, and it is a relatively simple procedure. Either the part of the stapes with the abnormal bone growth is removed in order to insert a tiny implant (stapedotomy), or the entire stapes bone is replaced by a small prosthesis (stapedectomy). Both surgeries can restore hearing. In many of the cases the symptoms of vertigo and tinnitus will also disappear.

- 
5. Do nothing (conservative approach)
Otosclerosis does not have to be treated. It is usually advisable to have a hearing test repeated once a year (or earlier if hearing worsens).
 6. Cochlear implants : Cochlear implants are used successfully in patients with otosclerosis. Patients with the best preoperative hearing levels are most likely to benefit. Cochlear implants are more difficult to position in otosclerosis due to sclerosis of the inner ear.



Stapedectomy

Involves removal of the anterior and posterior crura of the stapes, replacing it with a prosthesis between the incus and footplate and creating fenestrations in the footplate

