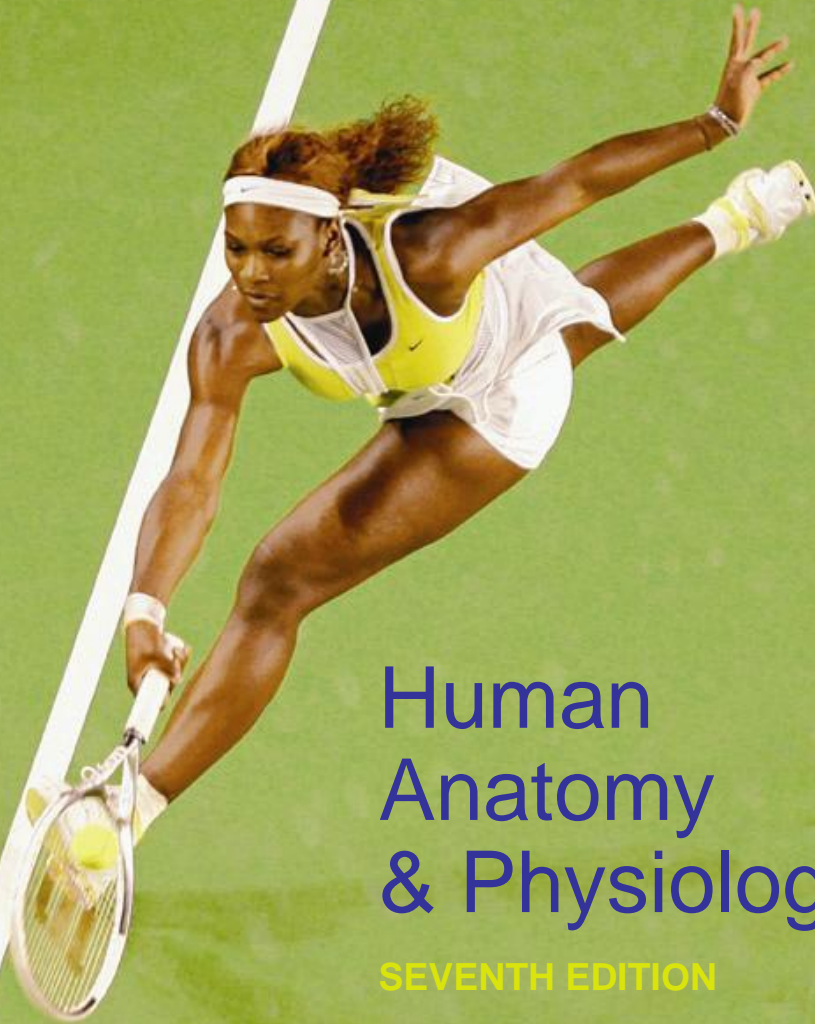

Elaine N. Marieb
Katja Hoehn



Human Anatomy & Physiology

SEVENTH EDITION

Copyright © 2006 Pearson Education, Inc., publishing as Benjamin Cummings

PowerPoint® Lecture Slides
prepared by Vince Austin,
Bluegrass Technical
and Community College

CHAPTER

9

PART A

Muscles and Muscle Tissue

Muscle Overview

- The three types of muscle tissue are skeletal, cardiac, and smooth
- These types differ in structure, location, function, and means of activation



InterActive Physiology ®:
Anatomy Review: Skeletal Muscle Tissue, page 3

Muscle Similarities

- Skeletal and smooth muscle cells are elongated and are called muscle fibers
- Muscle contraction depends on two kinds of myofilaments – actin and myosin
- Muscle terminology is similar
 - Sarcolemma – muscle plasma membrane
 - Sarcoplasm – cytoplasm of a muscle cell
 - Prefixes – myo, mys, and sarco all refer to muscle

Skeletal Muscle Tissue

- Packaged in skeletal muscles that attach to and cover the bony skeleton
- Has obvious stripes called striations
- Is controlled voluntarily (i.e., by conscious control)
- Contracts rapidly but tires easily
- Is responsible for overall body motility
- Is extremely adaptable and can exert forces ranging from a fraction of an ounce to over 70 pounds

Cardiac Muscle Tissue

- Occurs only in the heart
- Is striated like skeletal muscle but is not voluntary
- Contracts at a fairly steady rate set by the heart's pacemaker
- Neural controls allow the heart to respond to changes in bodily needs

Smooth Muscle Tissue

- Found in the walls of hollow visceral organs, such as the stomach, urinary bladder, and respiratory passages
- Forces food and other substances through internal body channels
- It is not striated and is involuntary

Functional Characteristics of Muscle Tissue

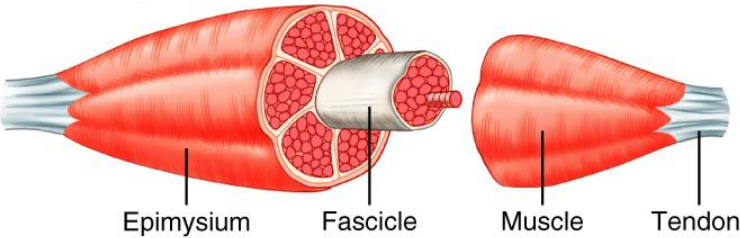
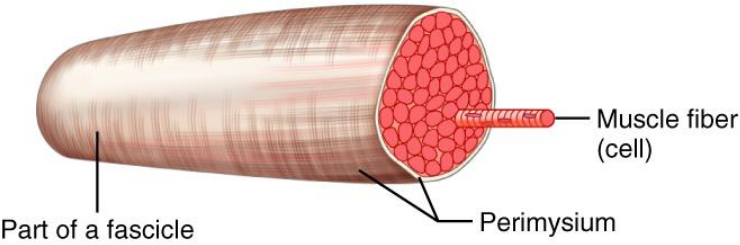
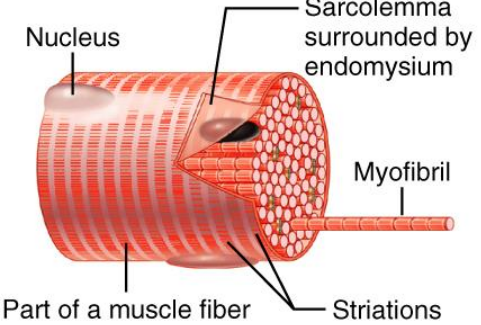
- **Excitability, or irritability** – the ability to receive and respond to stimuli
- **Contractility** – the ability to shorten forcibly
- **Extensibility** – the ability to be stretched or extended
- **Elasticity** – the ability to recoil and resume the original resting length

Muscle Function

- Skeletal muscles are responsible for all locomotion
- Cardiac muscle is responsible for coursing the blood through the body
- Smooth muscle helps maintain blood pressure, and squeezes or propels substances (i.e., food, feces) through organs
- Muscles also maintain posture, stabilize joints, and generate heat

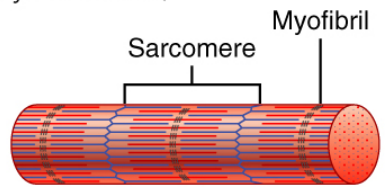
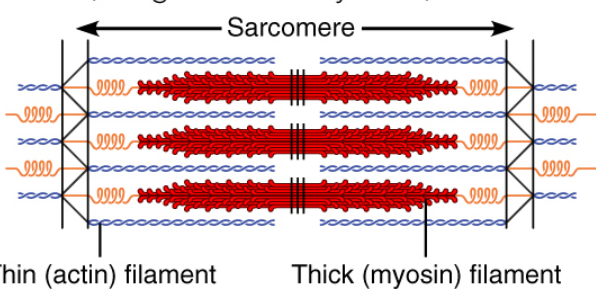
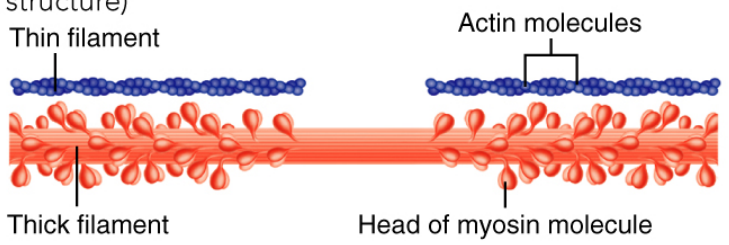
Structure and Organization of Skeletal Muscle

TABLE 9.1 Structure and Organizational Levels of Skeletal Muscle

STRUCTURE AND ORGANIZATIONAL LEVEL	DESCRIPTION	CONNECTIVE TISSUE WRAPPINGS
<p>Muscle (organ)</p> 	<p>Consists of hundreds to thousands of muscle cells, plus connective tissue wrappings, blood vessels, and nerve fibers</p>	<p>Covered externally by the epimysium</p>
<p>Fascicle (a portion of the muscle)</p> 	<p>Discrete bundle of muscle cells, segregated from the rest of the muscle by a connective tissue sheath</p>	<p>Surrounded by a perimysium</p>
<p>Muscle fiber (cell)</p> 	<p>Elongated multinucleate cell; has a banded (striated) appearance</p>	<p>Surrounded by the endomysium</p>

Structure and Organization of Skeletal Muscle

TABLE 9.1 Structure and Organizational Levels of Skeletal Muscle

STRUCTURE AND ORGANIZATIONAL LEVEL	DESCRIPTION	CONNECTIVE TISSUE WRAPPINGS
<p>Myofibril or fibril (complex organelle composed of bundles of myofilaments)</p> 	<p>Rodlike contractile element; myofibrils occupy most of the muscle cell volume; composed of sarcomeres arranged end to end; appear banded, and bands of adjacent myofibrils are aligned</p>	
<p>Sarcomere (a segment of a myofibril)</p> 	<p>The contractile unit, composed of myofilaments made up of contractile proteins</p>	
<p>Myofilament or filament (extended macromolecular structure)</p> 	<p>Contractile myofilaments are of two types—thick and thin: the thick filaments contain bundled myosin molecules; the thin filaments contain actin molecules (plus other proteins); the sliding of the thin filaments past the thick filaments produces muscle shortening. Elastic filaments (not shown here) maintain the organization of the A band and provide for elastic recoil when muscle contraction ends</p>	

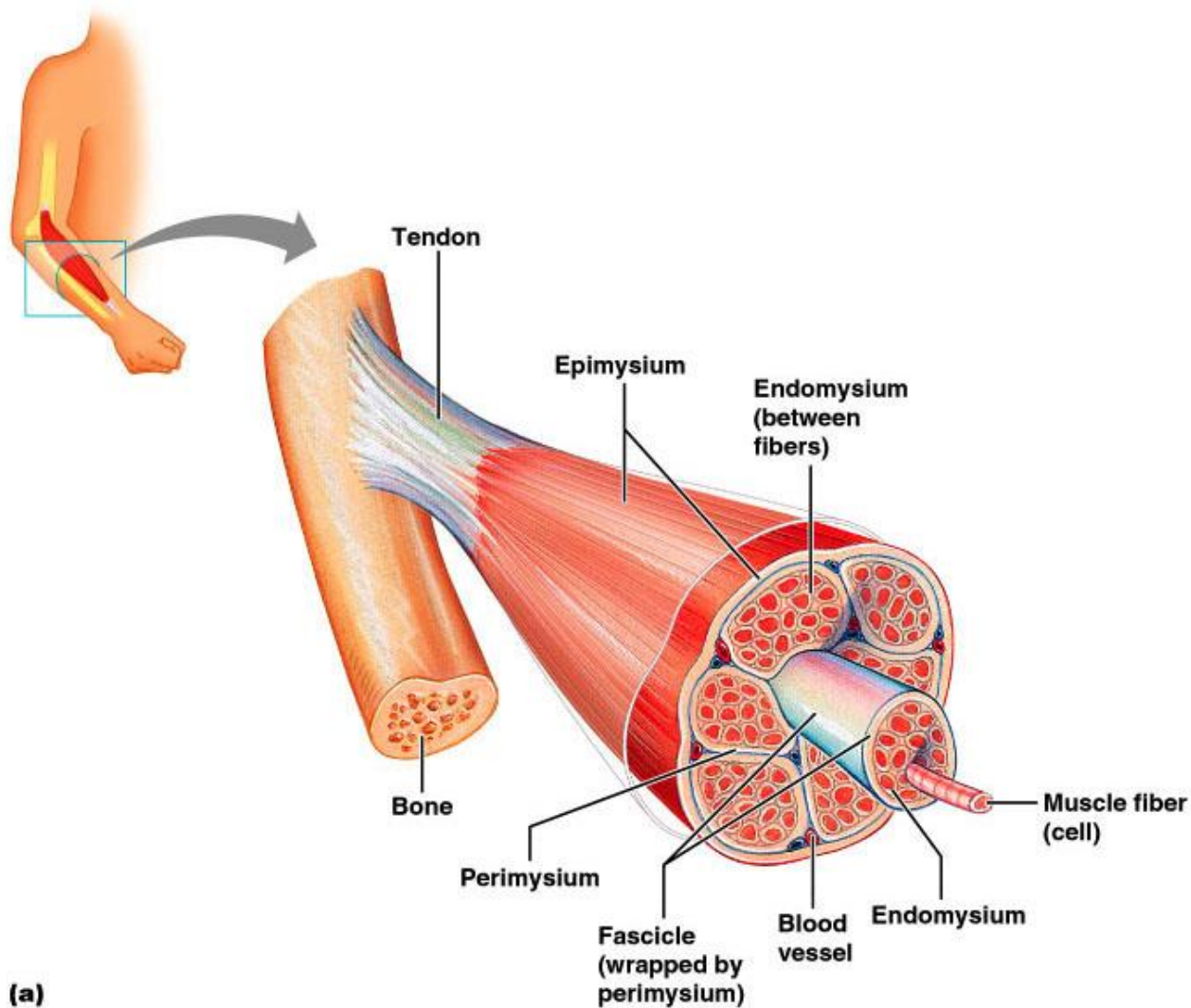
Skeletal Muscle

- Each muscle is a discrete organ composed of muscle tissue, blood vessels, nerve fibers, and connective tissue

Skeletal Muscle

- The three connective tissue sheaths are:
 - **Endomysium** – fine sheath of connective tissue composed of reticular fibers surrounding each muscle fiber
 - **Perimysium** – fibrous connective tissue that surrounds groups of muscle fibers called fascicles
 - **Epimysium** – an overcoat of dense regular connective tissue that surrounds the entire muscle

Skeletal Muscle



(a)



InterActive Physiology®:
Anatomy Review: Skeletal Muscle Tissue, pages 4-6

Figure 9.2a

Skeletal Muscle: Nerve and Blood Supply

- Each muscle is served by one nerve, an artery, and one or more veins
- Each skeletal muscle fiber is supplied with a nerve ending that controls contraction
- Contracting fibers require continuous delivery of oxygen and nutrients via arteries
- Wastes must be removed via veins

Skeletal Muscle: Attachments

- Most skeletal muscles span joints and are attached to bone in at least two places
- When muscles contract the movable bone, the muscle's insertion moves toward the immovable bone, the muscle's origin

Microscopic Anatomy of a Skeletal Muscle Fiber

- Each fiber is a long, cylindrical cell with multiple nuclei just beneath the sarcolemma
- Fibers are 10 to 100 μm in diameter, and up to hundreds of centimeters long

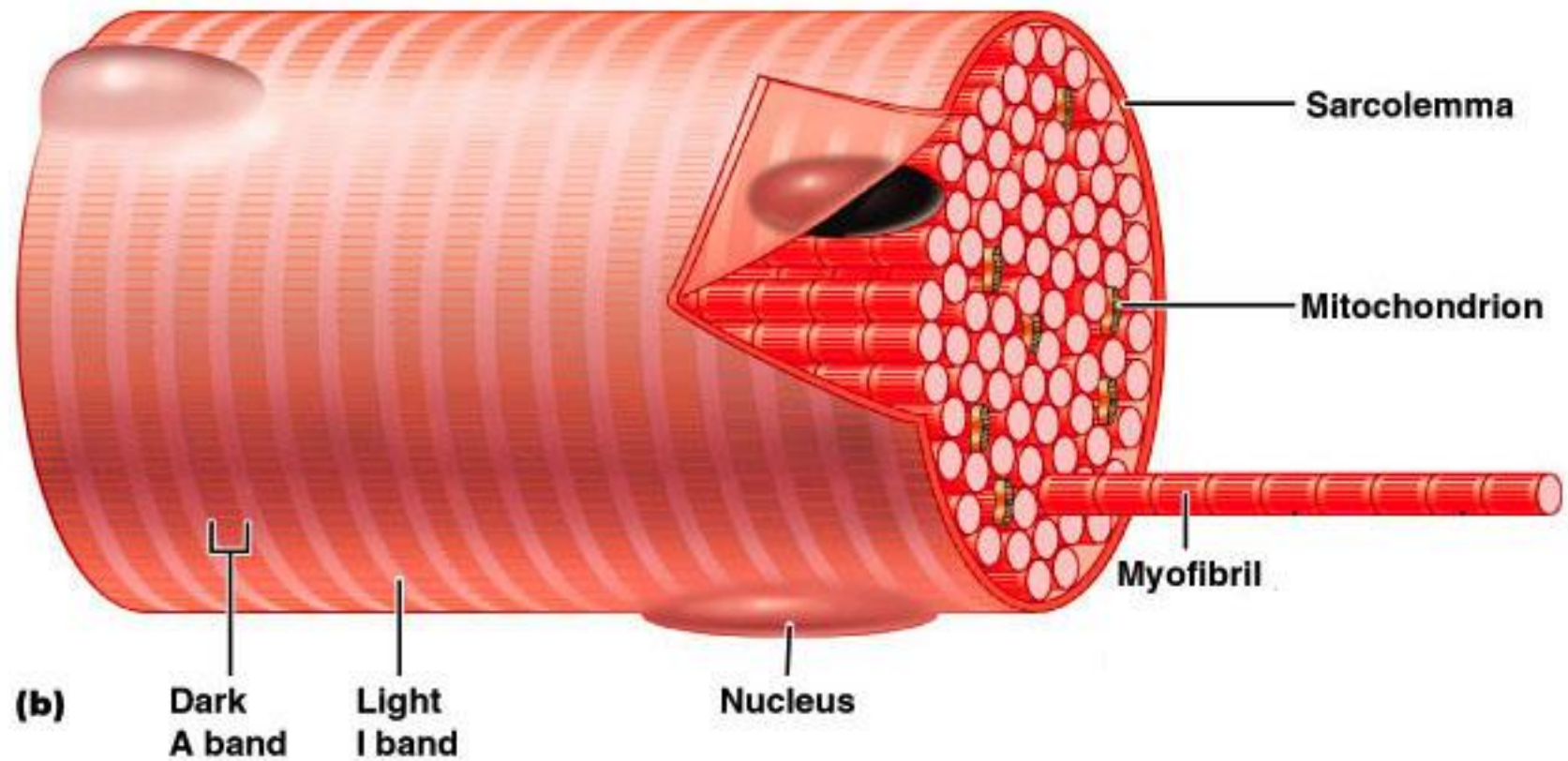
Microscopic Anatomy of a Skeletal Muscle Fiber

- Sarcoplasm has numerous glycosomes and a unique oxygen-binding protein called myoglobin
- Fibers contain the usual organelles, myofibrils, sarcoplasmic reticulum, and T tubules

Myofibrils

- Myofibrils are densely packed, rodlike contractile elements
- They make up most of the muscle volume
- The arrangement of myofibrils within a fiber is such that a perfectly aligned repeating series of dark A bands and light I bands is evident

Myofibrils



PLAY

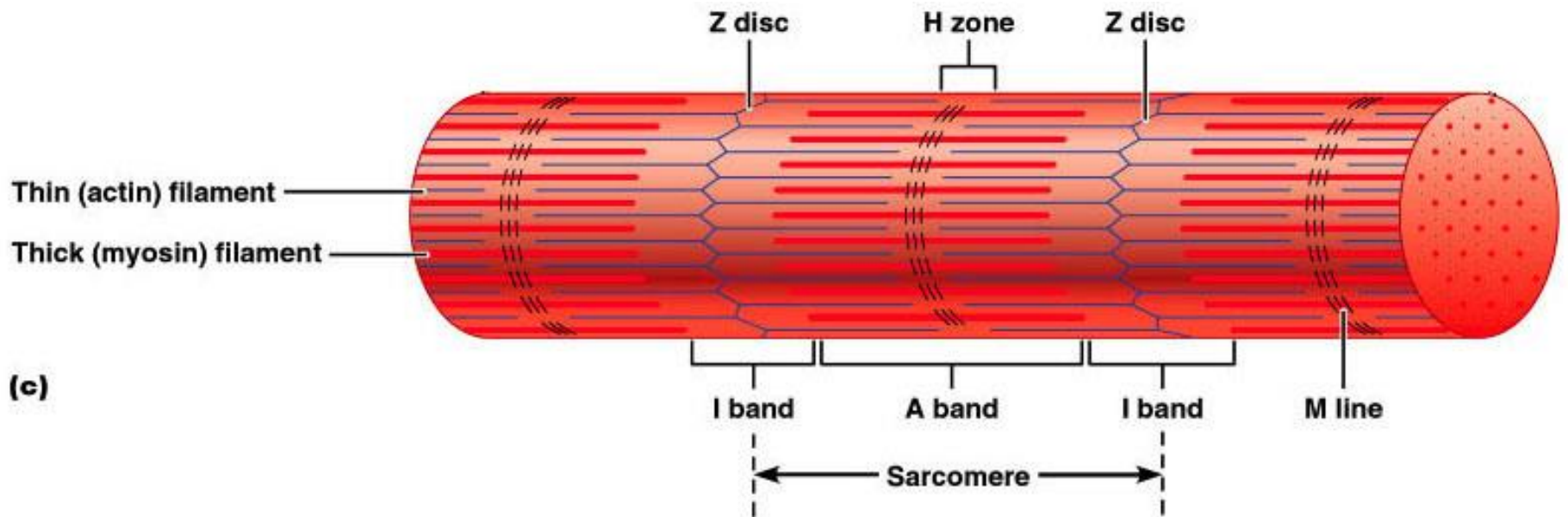
InterActive Physiology®:
Anatomy Review: Skeletal Muscle Tissue, pages 7-8

Figure 9.3b

Sarcomeres

- The smallest contractile unit of a muscle
- The region of a myofibril between two successive Z discs
- Composed of myofilaments made up of contractile proteins
 - Myofilaments are of two types – thick and thin

Sarcomeres



PLAY

InterActive Physiology®:
Anatomy Review: Skeletal Muscle Tissue, page 9

Figure 9.3c

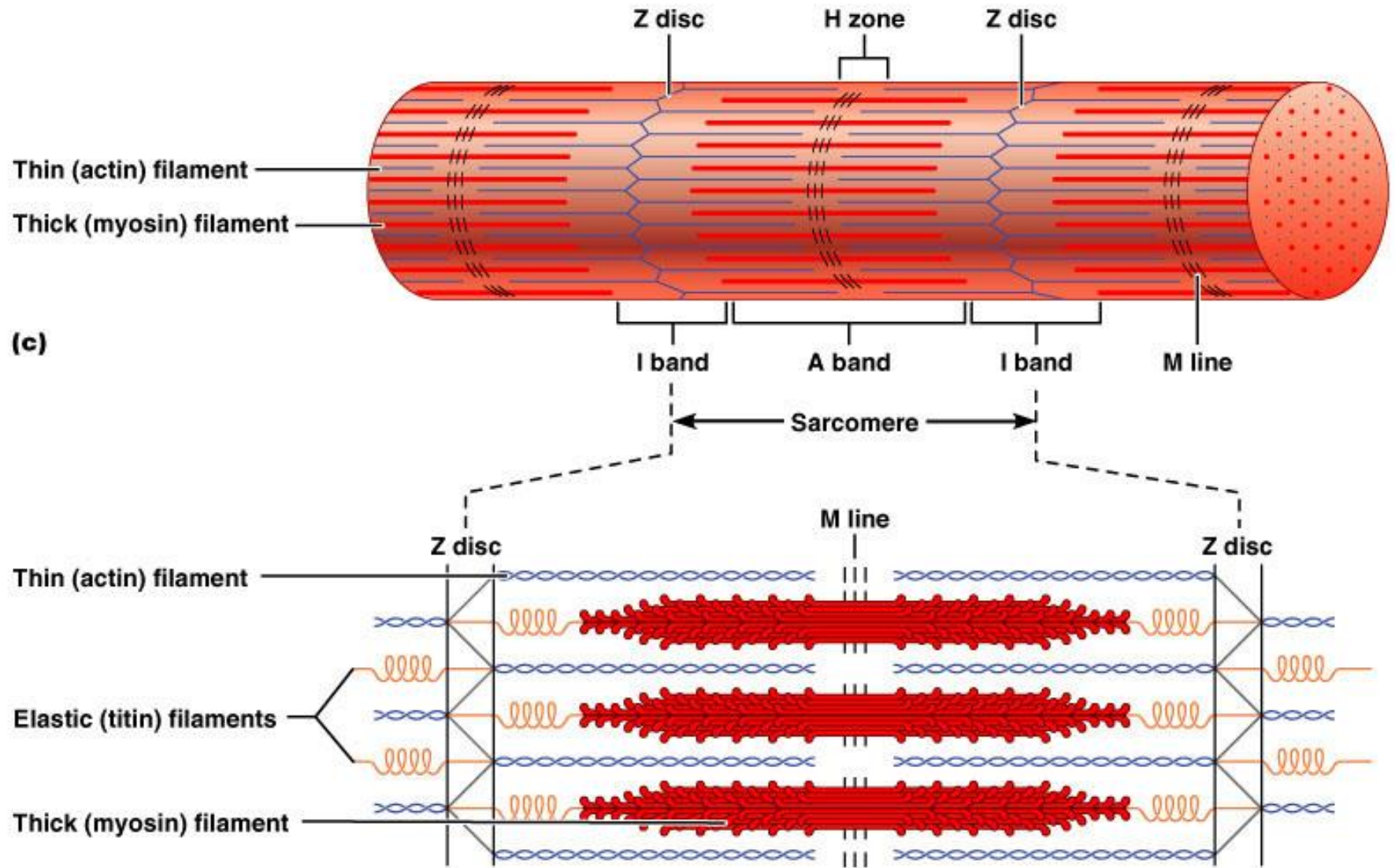
Myofilaments: Banding Pattern

- Thick filaments – extend the entire length of an A band
- Thin filaments – extend across the I band and partway into the A band
- Z-disc – coin-shaped sheet of proteins (connectins) that anchors the thin filaments and connects myofibrils to one another

Myofilaments: Banding Pattern

- Thin filaments do not overlap thick filaments in the lighter H zone
- M lines appear darker due to the presence of the protein desmin

Myofilaments: Banding Pattern



(c)

(d)

Figure 9.3c,d

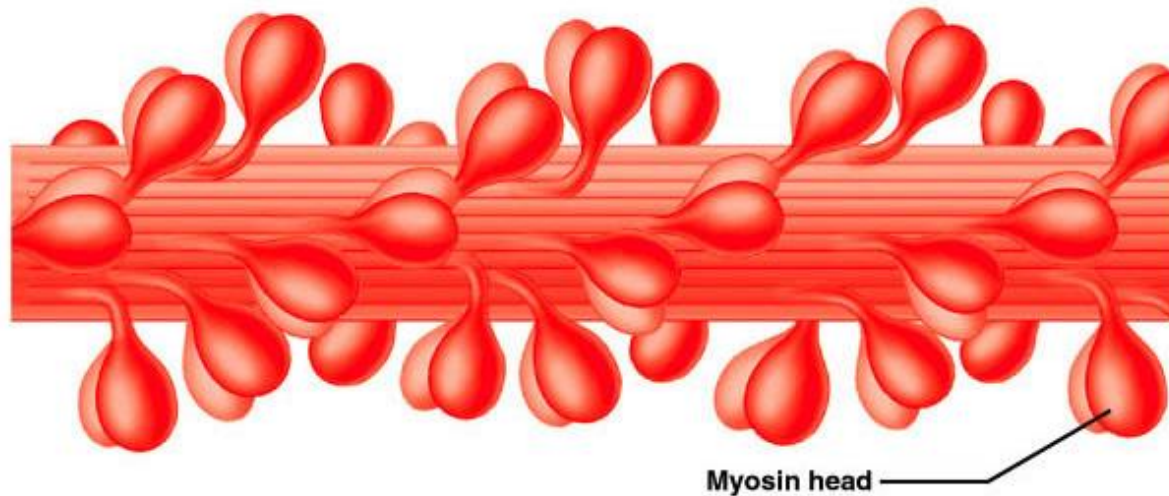
Ultrastructure of Myofilaments: Thick Filaments

- Thick filaments are composed of the protein myosin
- Each myosin molecule has a rod-like tail and two globular heads
 - Tails – two interwoven, heavy polypeptide chains
 - Heads – two smaller, light polypeptide chains called cross bridges

Ultrastructure of Myofilaments: Thick Filament



(a) Myosin molecule



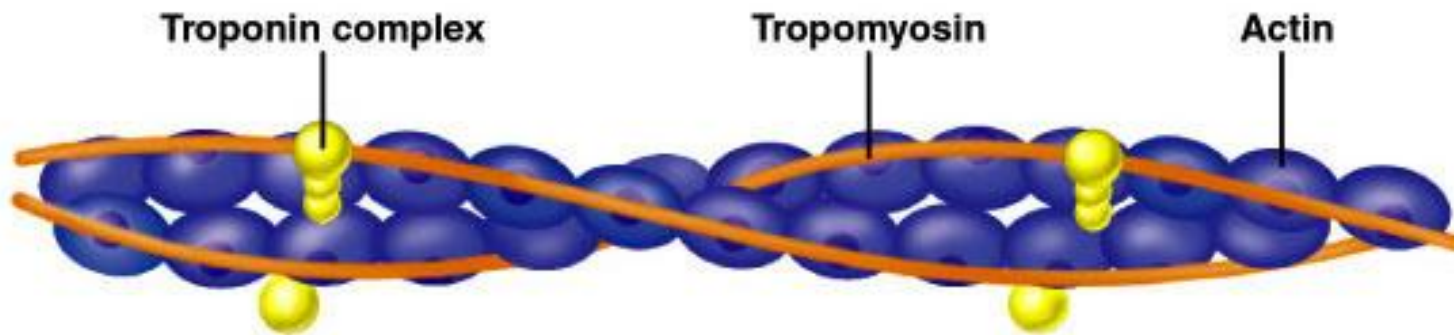
(b) Portion of a thick filament

Figure 9.4a,b

Ultrastructure of Myofilaments: Thin Filaments

- Thin filaments are chiefly composed of the protein actin
- Each actin molecule is a helical polymer of globular subunits called G actin
- The subunits contain the active sites to which myosin heads attach during contraction
- Tropomyosin and troponin are regulatory subunits bound to actin

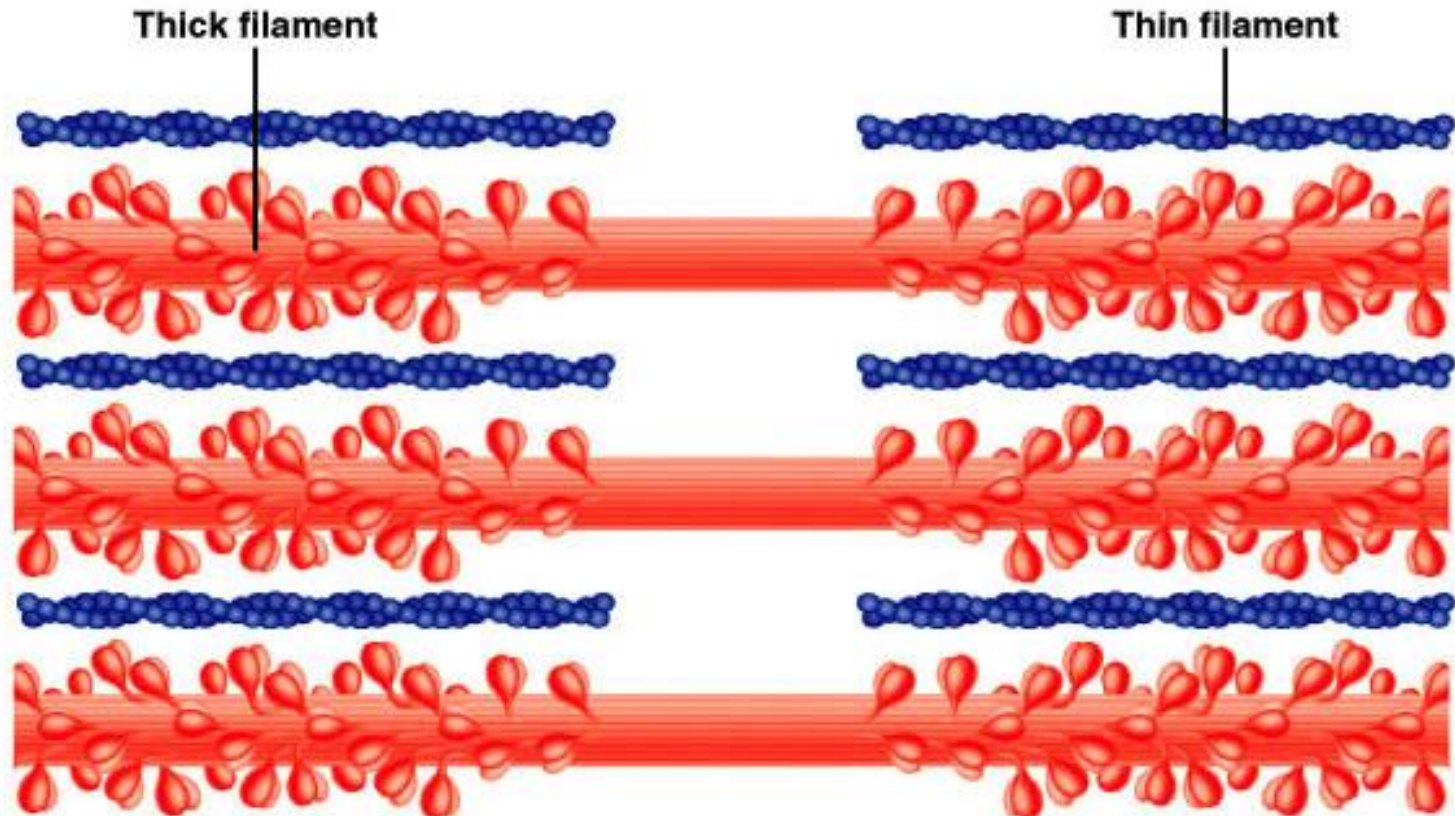
Ultrastructure of Myofilaments: Thin Filaments



(c) Portion of a thin filament

Arrangement of the Filaments in a Sarcomere

- Longitudinal section within one sarcomere



(d) Longitudinal section of filaments within one sarcomere of a myofibril

Sarcoplasmic Reticulum (SR)

- SR is an elaborate, smooth endoplasmic reticulum that mostly runs longitudinally and surrounds each myofibril
- Paired terminal cisternae form perpendicular cross channels
- Functions in the regulation of intracellular calcium levels

Sarcoplasmic Reticulum (SR)

- Elongated tubes called T tubules penetrate into the cell's interior at each A band–I band junction
- T tubules associate with the paired terminal cisternae to form triads

Sarcoplasmic Reticulum (SR)

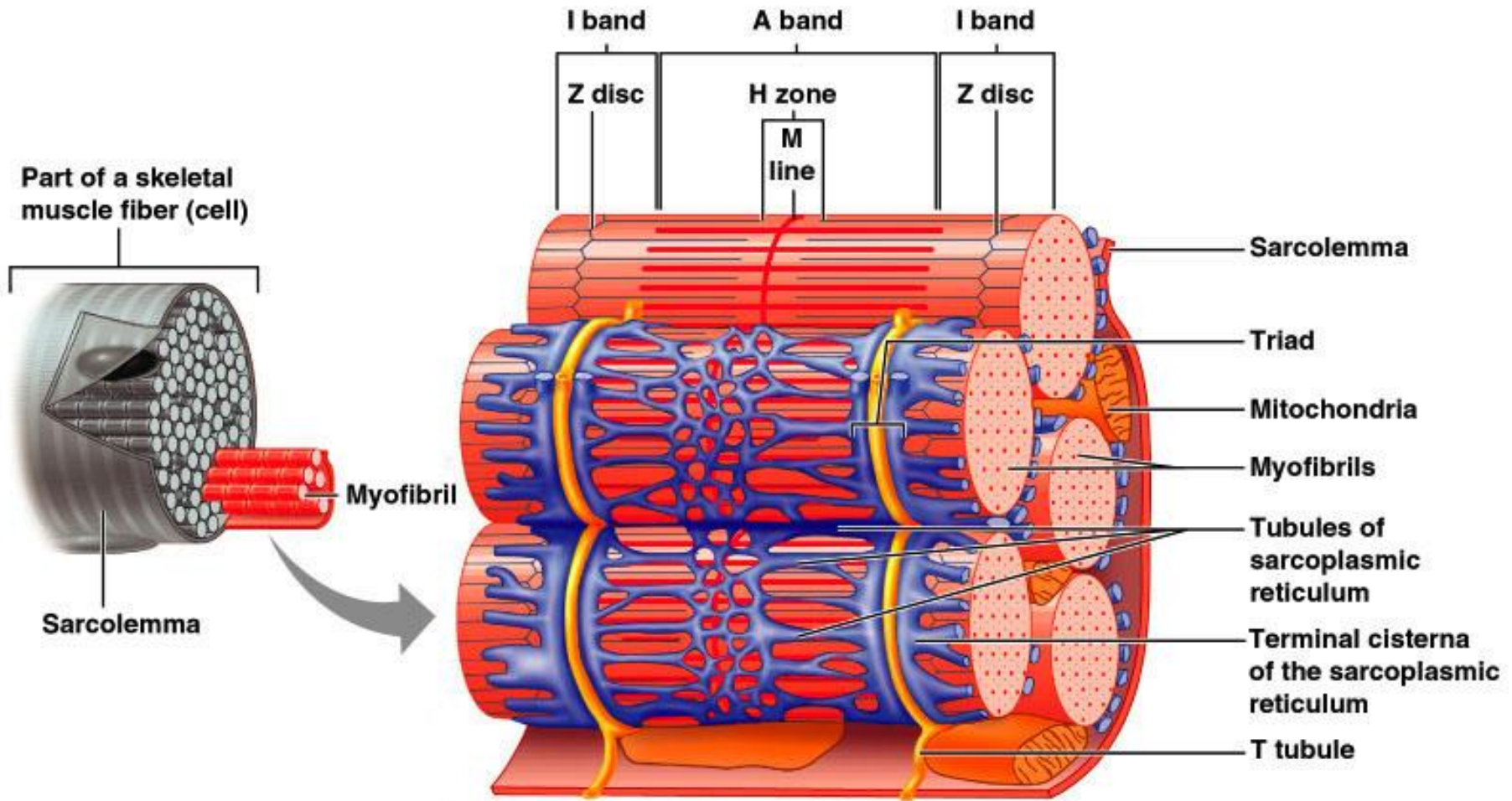


Figure 9.5

T Tubules

- T tubules are continuous with the sarcolemma
- They conduct impulses to the deepest regions of the muscle
- These impulses signal for the release of Ca^{2+} from adjacent terminal cisternae

Triad Relationships

- T tubules and SR provide tightly linked signals for muscle contraction
- A double zipper of integral membrane proteins protrudes into the intermembrane space
- T tubule proteins act as voltage sensors
- SR foot proteins are receptors that regulate Ca^{2+} release from the SR cisternae



InterActive Physiology ®:

Anatomy Review: Skeletal Muscle Tissue, page 10

Sliding Filament Model of Contraction

- Thin filaments slide past the thick ones so that the actin and myosin filaments overlap to a greater degree
- In the relaxed state, thin and thick filaments overlap only slightly
- Upon stimulation, myosin heads bind to actin and sliding begins

Sliding Filament Model of Contraction

- Each myosin head binds and detaches several times during contraction, acting like a ratchet to generate tension and propel the thin filaments to the center of the sarcomere
- As this event occurs throughout the sarcomeres, the muscle shortens

Skeletal Muscle Contraction

- In order to contract, a skeletal muscle must:
 - Be stimulated by a nerve ending
 - Propagate an electrical current, or action potential, along its sarcolemma
 - Have a rise in intracellular Ca^{2+} levels, the final trigger for contraction
- Linking the electrical signal to the contraction is excitation-contraction coupling

Nerve Stimulus of Skeletal Muscle

- Skeletal muscles are stimulated by motor neurons of the somatic nervous system
- Axons of these neurons travel in nerves to muscle cells
- Axons of motor neurons branch profusely as they enter muscles
- Each axonal branch forms a neuromuscular junction with a single muscle fiber

Neuromuscular Junction

- The neuromuscular junction is formed from:
 - Axonal endings, which have small membranous sacs (synaptic vesicles) that contain the neurotransmitter acetylcholine (ACh)
 - The motor end plate of a muscle, which is a specific part of the sarcolemma that contains ACh receptors and helps form the neuromuscular junction
- Though exceedingly close, axonal ends and muscle fibers are always separated by a space called the synaptic cleft

Neuromuscular Junction

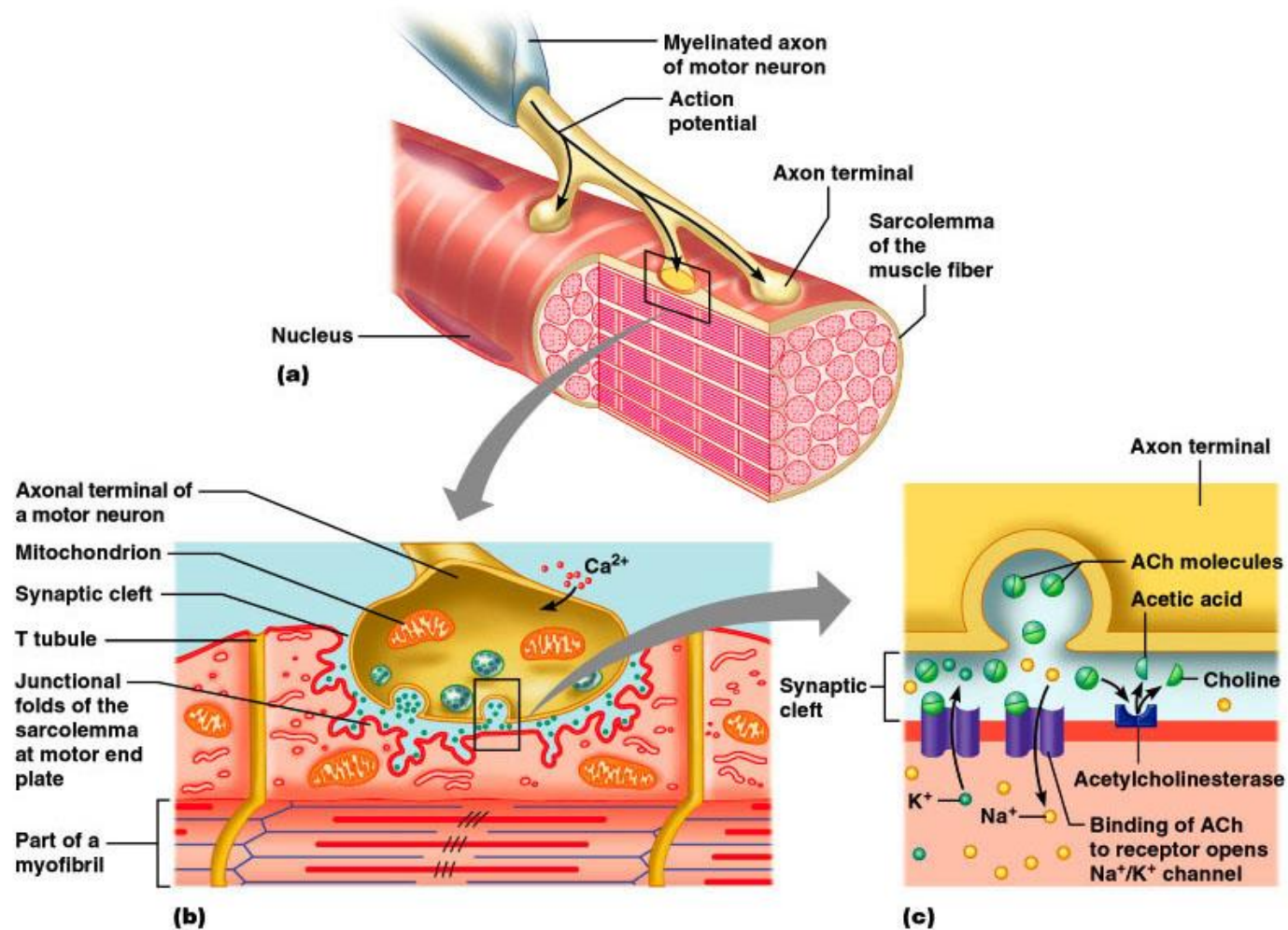


Figure 9.7 (a-c)

Neuromuscular Junction

- When a nerve impulse reaches the end of an axon at the neuromuscular junction:
 - Voltage-regulated calcium channels open and allow Ca^{2+} to enter the axon
 - Ca^{2+} inside the axon terminal causes axonal vesicles to fuse with the axonal membrane



InterActive Physiology ®:
The Neuromuscular Junction, pages 3-5

Neuromuscular Junction

- This fusion releases ACh into the synaptic cleft via exocytosis
- ACh diffuses across the synaptic cleft to ACh receptors on the sarcolemma
- Binding of ACh to its receptors initiates an action potential in the muscle

Destruction of Acetylcholine

- ACh bound to ACh receptors is quickly destroyed by the enzyme acetylcholinesterase
- This destruction prevents continued muscle fiber contraction in the absence of additional stimuli



InterActive Physiology ®:
The Neuromuscular Junction, pages 6-10

Action Potential

- A transient depolarization event that includes polarity reversal of a sarcolemma (or nerve cell membrane) and the propagation of an action potential along the membrane

Role of Acetylcholine (ACh)

- ACh binds its receptors at the motor end plate
- Binding opens chemically (ligand) gated channels
- Na^+ diffuse **in** and the interior of the sarcolemma becomes less negative
- This event is called depolarization

Depolarization

- Initially, this is a local electrical event called end plate potential
- Later, it ignites an action potential that spreads in all directions across the sarcolemma

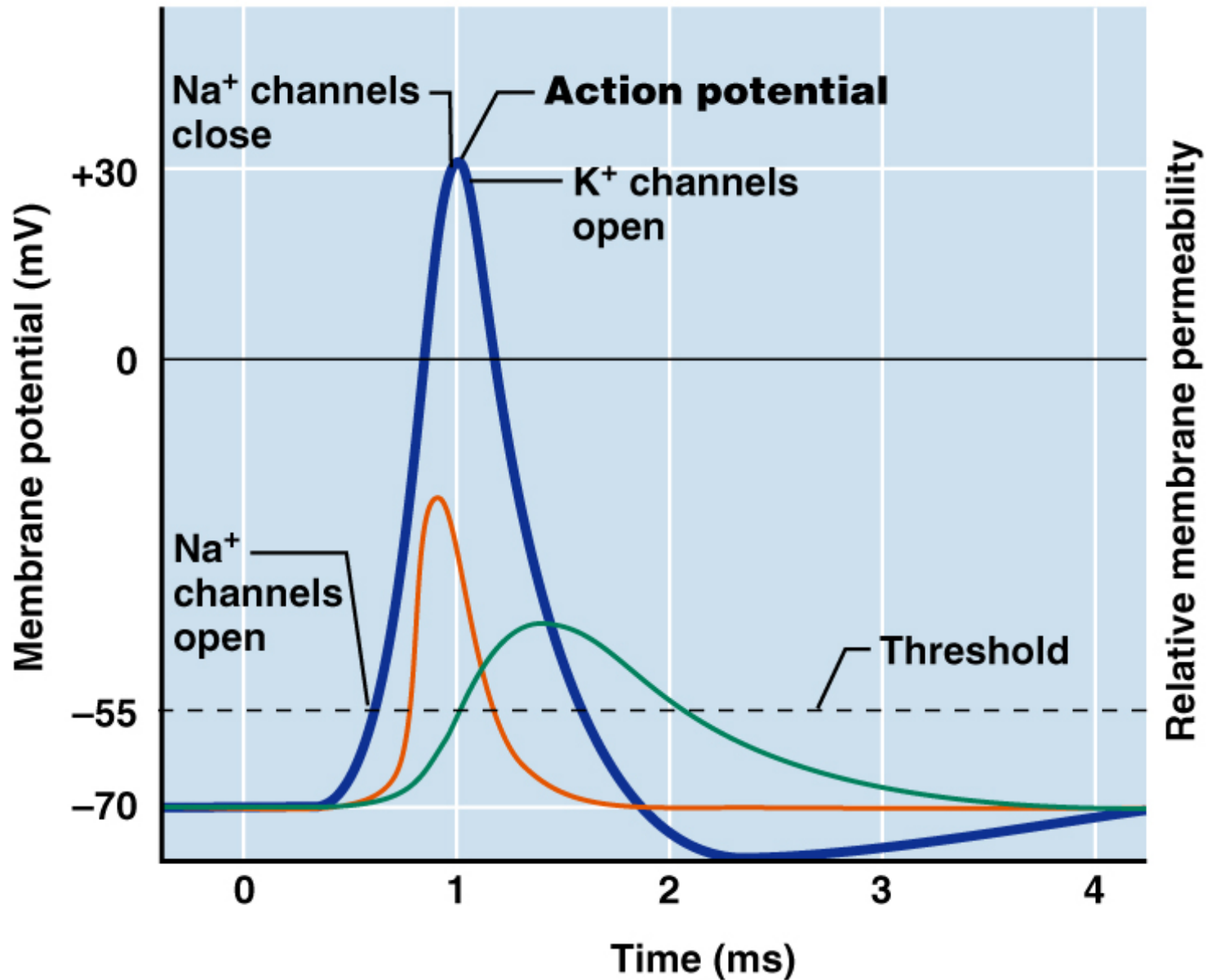
Excitation-Contraction Coupling

- Once generated, the action potential:
 - Is propagated along the sarcolemma
 - Travels down the T tubules
 - Triggers Ca^{2+} release from terminal cisternae
- Ca^{2+} binds to troponin and causes:
 - The blocking action of tropomyosin to cease
 - Actin active binding sites to be exposed

Excitation-Contraction Coupling

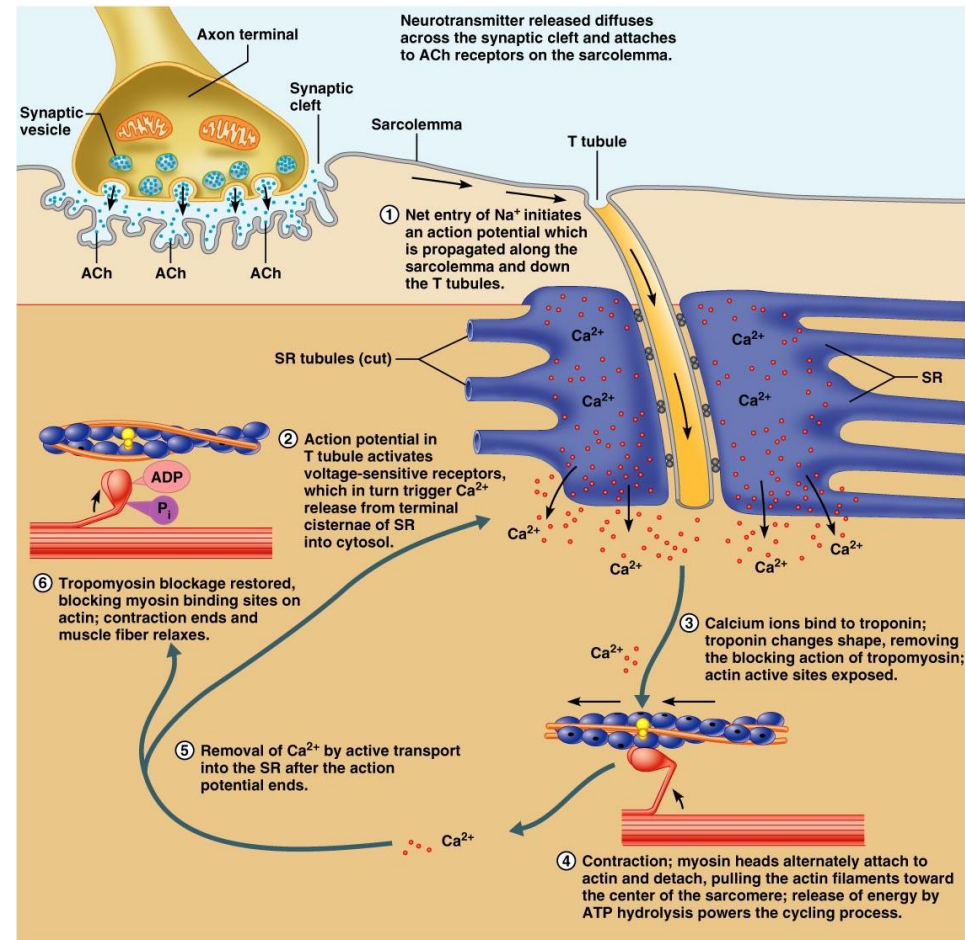
- Myosin cross bridges alternately attach and detach
- Thin filaments move toward the center of the sarcomere
- Hydrolysis of ATP powers this cycling process
- Ca^{2+} is removed into the SR, tropomyosin blockage is restored, and the muscle fiber relaxes

Action Potential Scan



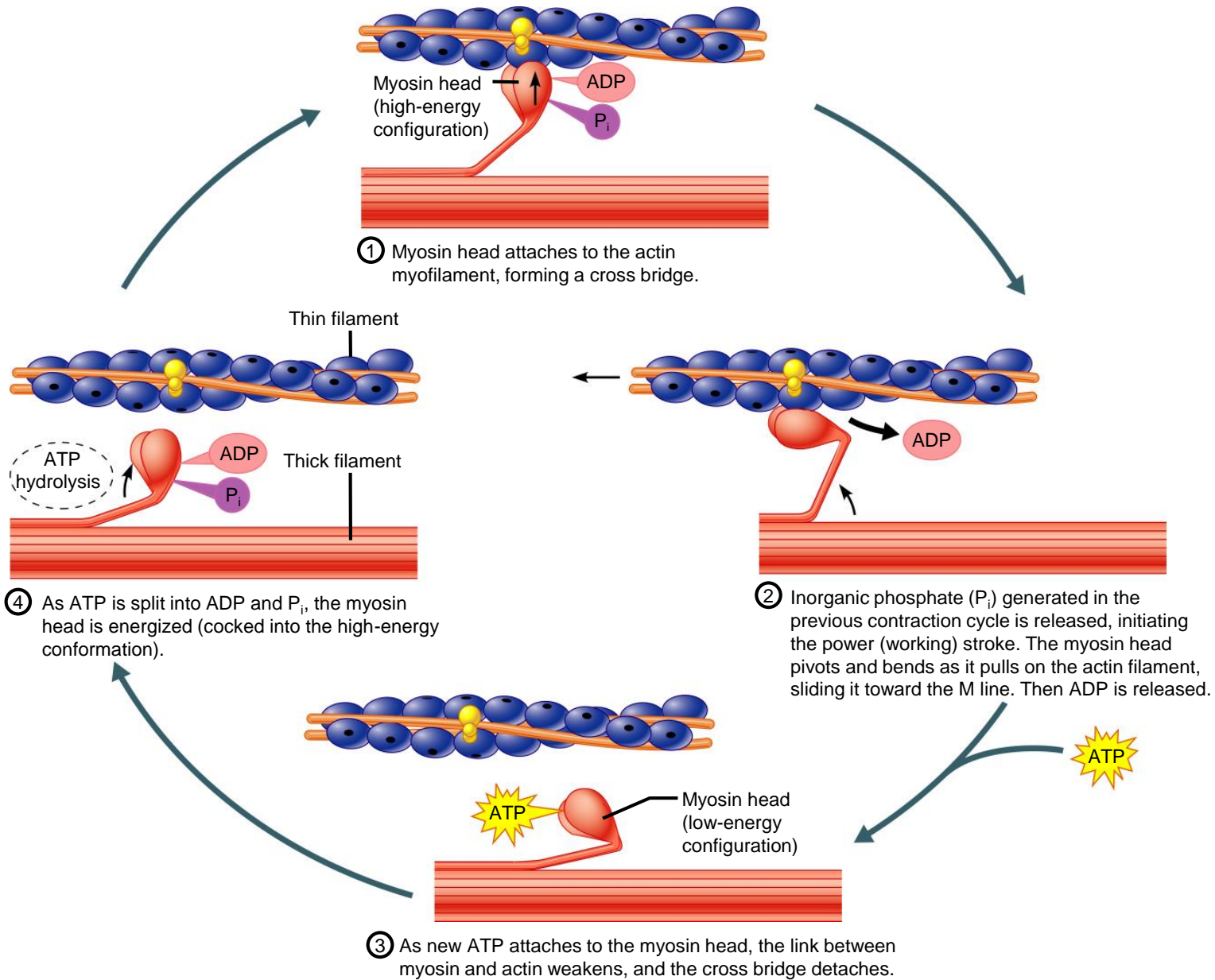
Excitation-Contraction (EC) Coupling

1. Action potential generated and propagated along sarcomere to T-tubules
2. Action potential triggers Ca^{2+} release
3. Ca^{++} bind to troponin; blocking action of tropomyosin released
4. contraction via crossbridge formation; ATP hydrolysis
5. Removal of Ca^{+2} by active transport
6. tropomyosin blockage restored; contraction ends



Sequential Events of Contraction

- Cross bridge formation – myosin cross bridge attaches to actin filament
- Working (power) stroke – myosin head pivots and pulls actin filament toward M line
- Cross bridge detachment – ATP attaches to myosin head and the cross bridge detaches
- “Cocking” of the myosin head – energy from hydrolysis of ATP cocks the myosin head into the high-energy state



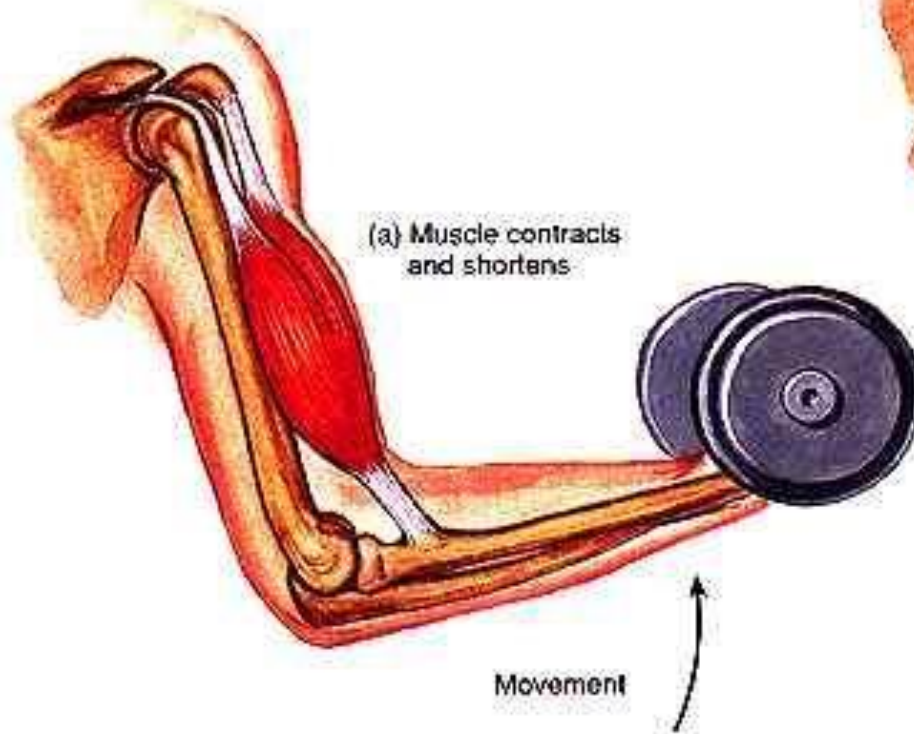
Contraction of Skeletal Muscle Fibers

- Contraction – refers to the activation of myosin's cross bridges (force-generating sites)
- Shortening occurs when the tension generated by the cross bridge exceeds forces opposing shortening
- Contraction ends when cross bridges become inactive, the tension generated declines, and relaxation is induced

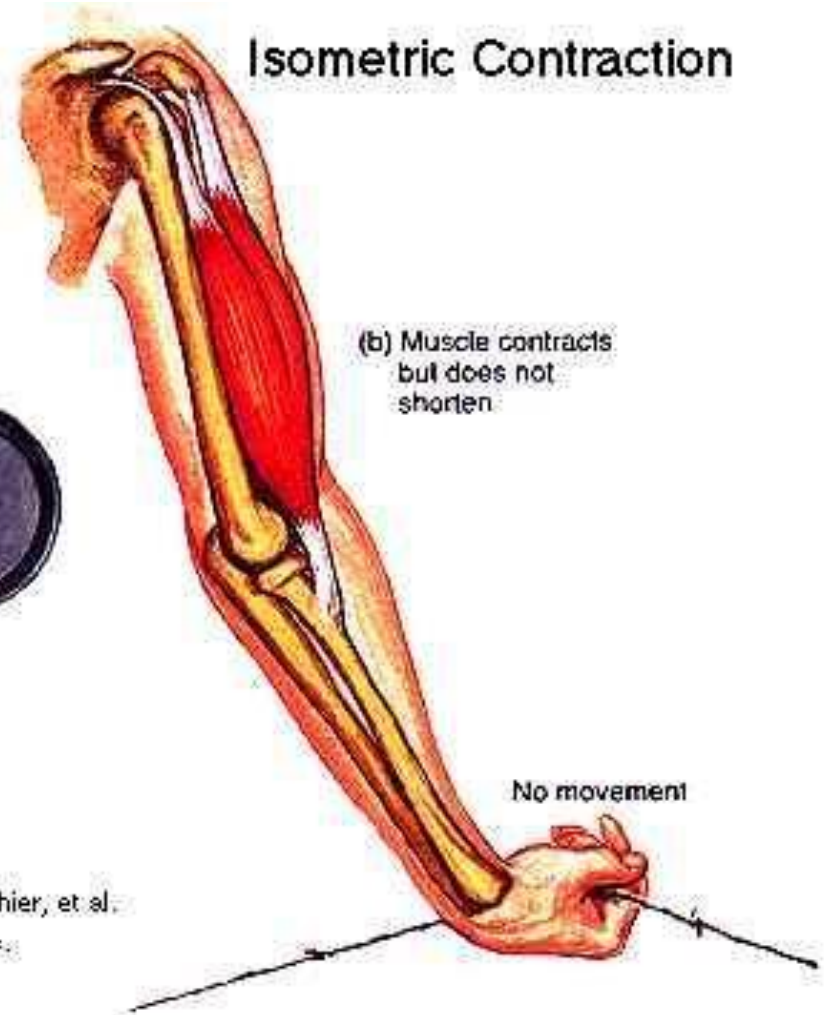Contraction of Skeletal Muscle (Organ Level)

- Contraction of muscle fibers (cells) and muscles (organs) is similar
- The two types of muscle contractions are:
 - **Isometric contraction** – increasing muscle tension (muscle does not shorten during contraction)
 - **Isotonic contraction** – decreasing muscle length (muscle shortens during contraction)

Isotonic Contraction



Isometric Contraction



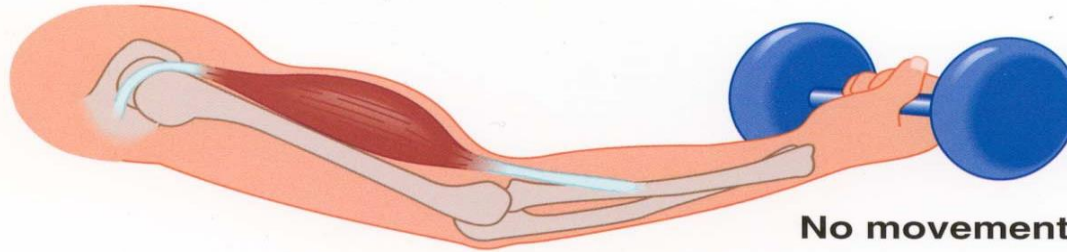
Hole's Human Anatomy and Physiology, 7th edition, by Shier, et al.
copyright ©1996 TM Higher Education Group, Inc.

Isotonic Contractions

- In isotonic contractions, the muscle changes in length (decreasing the angle of the joint) and moves the load
- The two types of isotonic contractions are concentric and eccentric
 - **Concentric contractions** – the muscle shortens and does work
 - **Eccentric contractions** – the muscle contracts as it lengthens

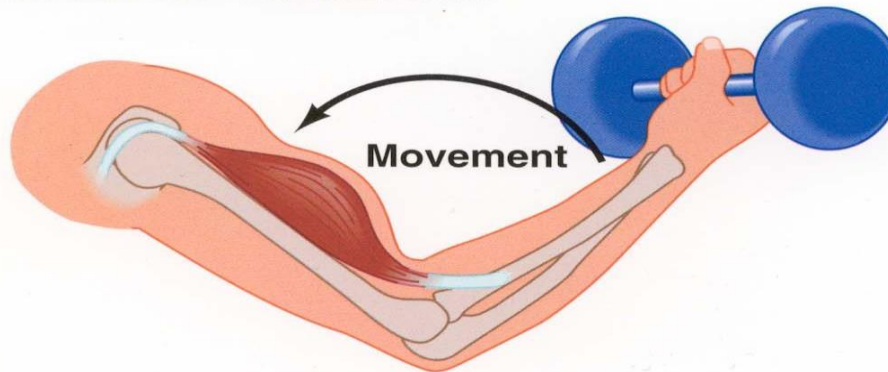
Isometric contraction

Muscle contracts
but does not shorten



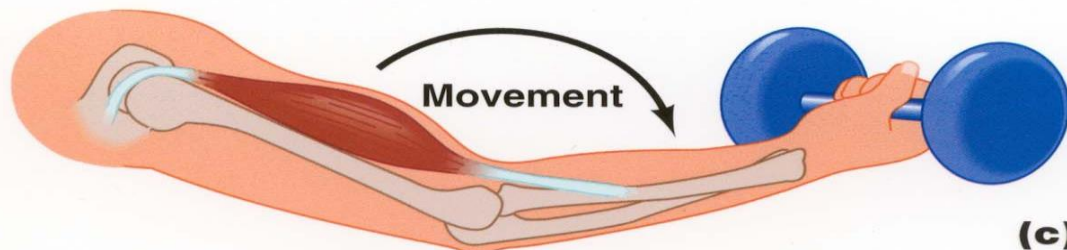
(a)

Concentric contraction



(b)

Eccentric contraction



(c)

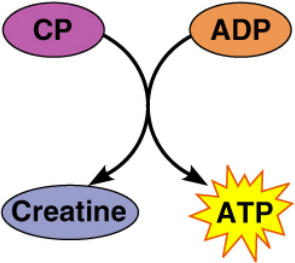
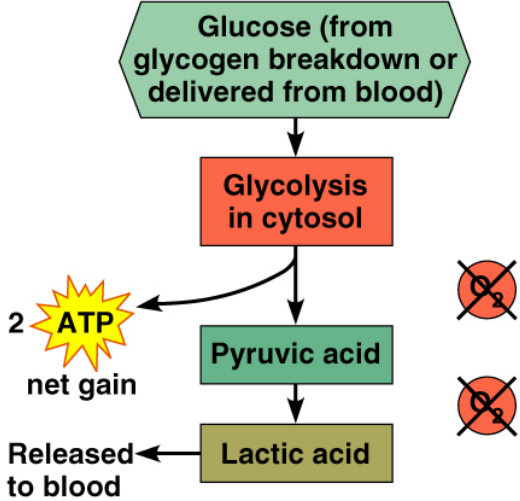
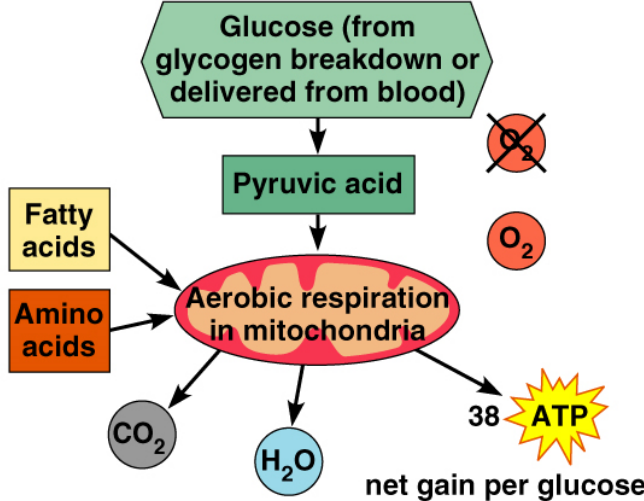
Muscle Metabolism: Energy for Contraction

- ATP is the only source used directly for contractile activity
- As soon as available stores of ATP are hydrolyzed (4-6 seconds), they are regenerated by:
 - The interaction of ADP with creatine phosphate (CP)
 - Anaerobic glycolysis
 - Aerobic respiration



InterActive Physiology®:
Muscle Metabolism, pages 3-15

Muscle Metabolism: Energy for Contraction

		
<p>(a) Direct phosphorylation [coupled reaction of creatine phosphate (CP) and ADP]</p>	<p>(b) Anaerobic mechanism (glycolysis and lactic acid formation)</p>	<p>(c) Aerobic mechanism (aerobic cellular respiration)</p>
<p>Energy source: CP</p>	<p>Energy source: glucose</p>	<p>Energy source: glucose; pyruvic acid; free fatty acids from adipose tissue; amino acids from protein catabolism</p>
<p>Oxygen use: None Products: 1 ATP per CP, creatine Duration of energy provision: 15 s.</p>	<p>Oxygen use: None Products: 2 ATP per glucose, lactic acid Duration of energy provision: 30–60 s.</p>	<p>Oxygen use: Required Products: 38 ATP per glucose, CO₂, H₂O Duration of energy provision: Hours</p>

36 - 38 ATP

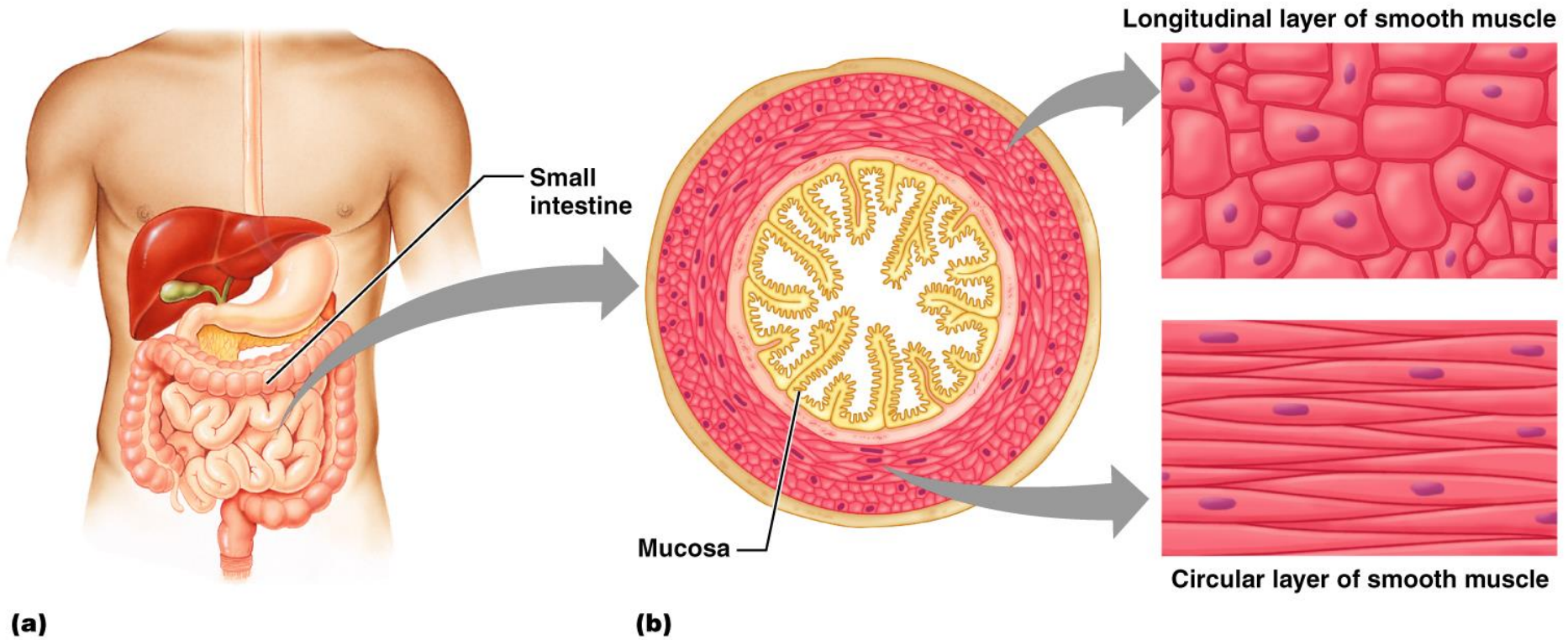
Smooth Muscle

- Composed of spindle-shaped fibers with a diameter of 2-10 μm and lengths of several hundred μm
- Lack the coarse connective tissue sheaths of skeletal muscle, but have fine endomysium
- Organized into two layers (longitudinal and circular) of closely apposed fibers

Smooth Muscle

- Found in walls of hollow organs (except the heart)
- Have essentially the same contractile mechanisms as skeletal muscle

Smooth Muscle



Microscopic Anatomy of Smooth Muscle

- SR is less developed than in skeletal muscle and lacks a specific pattern
- T tubules are absent
- Plasma membranes have pouchlike infoldings called caveoli

Microscopic Anatomy of Smooth Muscle

- Ca^{2+} is sequestered in the extracellular space near the caveoli, allowing rapid influx when channels are opened
- There are no visible striations and no sarcomeres
- Thin and thick filaments are present

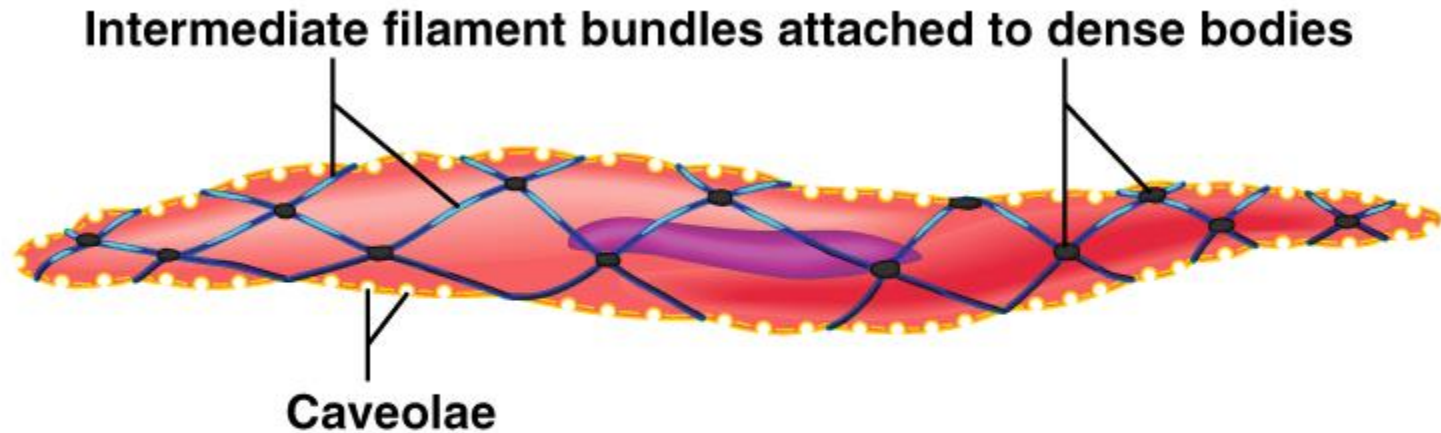
Proportion and Organization of Myofilaments in Smooth Muscle

- Ratio of thick to thin filaments is much lower than in skeletal muscle
- Thick filaments have heads along their entire length
- There is no troponin complex

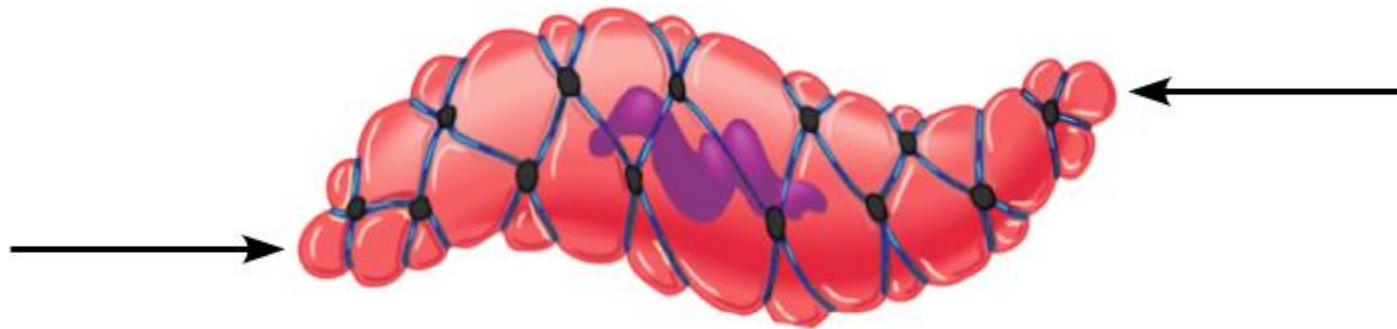
Proportion and Organization of Myofilaments in Smooth Muscle

- Thick and thin filaments are arranged diagonally, causing smooth muscle to contract in a corkscrew manner
- Noncontractile intermediate filament bundles attach to dense bodies (analogous to Z discs) at regular intervals

Proportion and Organization of Myofilaments in Smooth Muscle



(a) Relaxed smooth muscle cell



(b) Contracted smooth muscle cell

Contraction of Smooth Muscle

- Whole sheets of smooth muscle exhibit slow, synchronized contraction
- They contract in union, reflecting their electrical coupling with gap junctions
- Action potentials are transmitted from cell to cell

Contraction of Smooth Muscle

- Some smooth muscle cells:
 - Act as pacemakers and set the contractile pace for whole sheets of muscle
 - Are self-excitatory and depolarize without external stimuli

Contraction Mechanism

- Actin and myosin interact according to the sliding filament mechanism
- The final trigger for contractions is a rise in intracellular Ca^{2+}
- Ca^{2+} is released from the SR and from the extracellular space
- Ca^{2+} interacts with calmodulin and myosin light chain kinase to activate myosin

Role of Calcium Ion

- Ca^{2+} binds to calmodulin and activates it
- Activated calmodulin activates the kinase enzyme
- Activated kinase transfers phosphate from ATP to myosin cross bridges
- Phosphorylated cross bridges interact with actin to produce shortening
- Smooth muscle relaxes when intracellular Ca^{2+} levels drop

TABLE 9.3 Comparison of Skeletal, Cardiac, and Smooth Muscle

CHARACTERISTIC

SKELETAL

CARDIAC

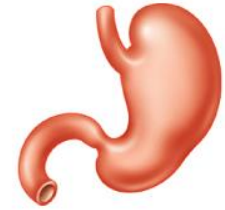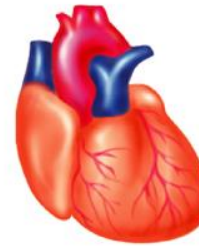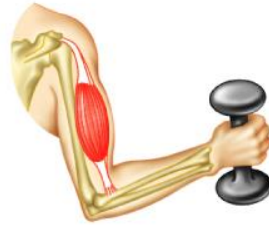SMOOTH

Body location

Attached to bones or (some facial muscles) to skin

Walls of the heart

Single-unit muscle in walls of hollow visceral organs (other than the heart); multiunit muscle in intrinsic eye muscles, airways, large arteries



Cell shape and appearance

Single, very long, cylindrical, multinucleate cells with obvious striations

Branching chains of cells; uni- or binucleate; striations

Single, fusiform, uninucleate; no striations

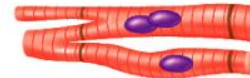

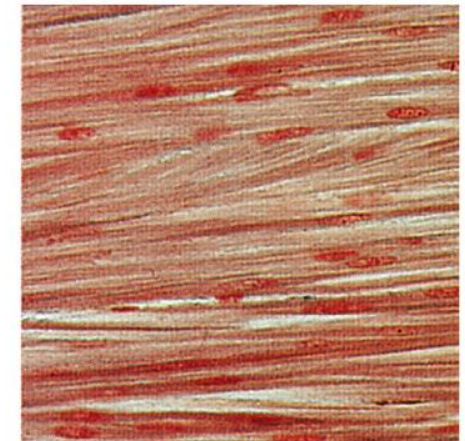
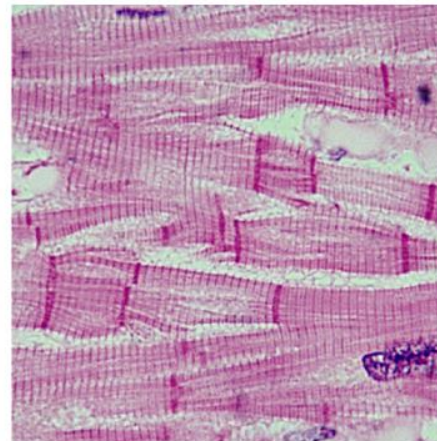
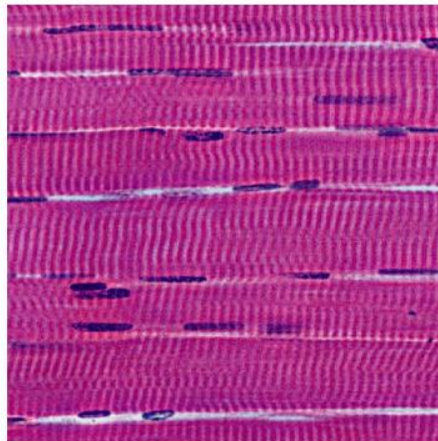


TABLE 9.3 Comparison of Skeletal, Cardiac, and Smooth Muscle

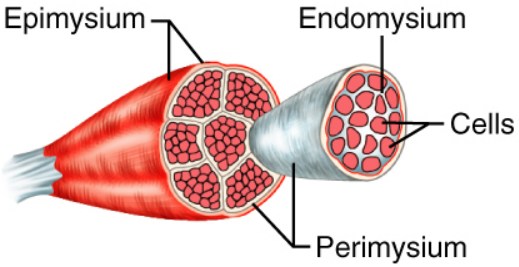
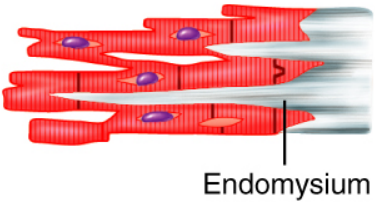
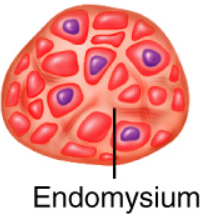
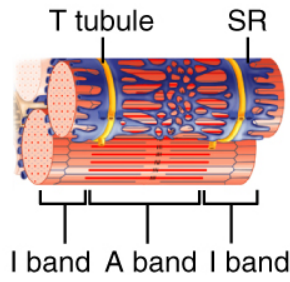
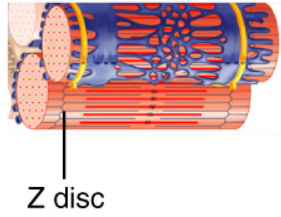
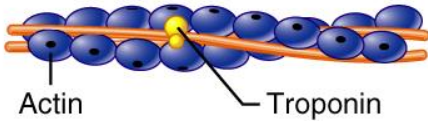
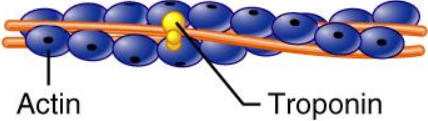
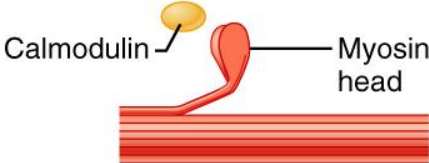



CHARACTERISTIC	SKELETAL	CARDIAC	SMOOTH
Connective tissue components	Epimysium, perimysium, and endomysium 	Endomysium attached to fibrous skeleton of heart 	Endomysium 
Presence of myofibrils composed of sarcomeres	Yes	Yes, but myofibrils are of irregular thickness	No, but actin and myosin filaments are present throughout; dense bodies anchor actin filaments
Presence of T tubules and site of invagination	Yes; two in each sarcomere at A-I junctions 	Yes; one in each sarcomere at Z disc; larger diameter than those of skeletal muscle 	No; only caveolae
Elaborate sarcoplasmic reticulum	Yes	Less than skeletal muscle (1–8% of cell volume); scant terminal cisternae	Equivalent to cardiac muscle (1–8% of cell volume); some SR contacts the sarcolemma

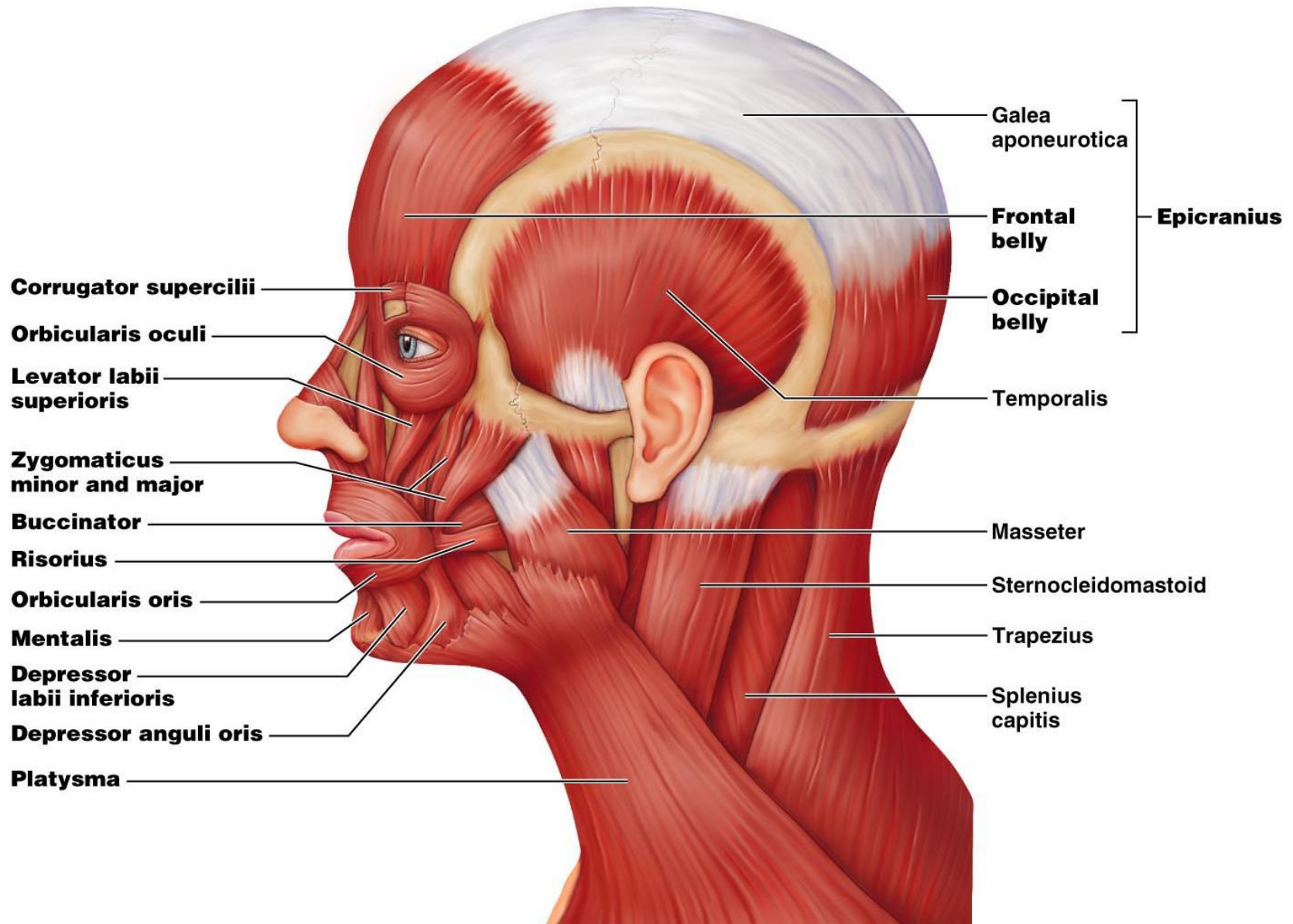
TABLE 9.3 Comparison of Skeletal, Cardiac, and Smooth Muscle

CHARACTERISTIC	SKELETAL	CARDIAC	SMOOTH
Site of calcium regulation	Troponin on actin-containing thin filaments 	Troponin on actin-containing thin filaments 	Calmodulin in the sarcoplasm 
Presence of pacemaker(s)	No	Yes	Yes (in single-unit muscle only)
Effect of nervous system stimulation	Excitation	Excitation or inhibition	Excitation or inhibition
Speed of contraction	Slow to fast 	Slow 	Very slow 
Rhythmic contraction	No	Yes	Yes in single-unit muscle
Response to stretch	Contractile strength increases with degree of stretch (to a point)	Contractile strength increases with degree of stretch	Stress-relaxation response
Respiration	Aerobic and anaerobic	Aerobic	Mainly aerobic

Muscles of the Face

- 11 muscles are involved in lifting the eyebrows, flaring the nostrils, opening and closing the eyes and mouth, and smiling
- All are innervated by cranial nerve VII (facial nerve)
- Usually insert in skin (rather than bone), and adjacent muscles often fuse

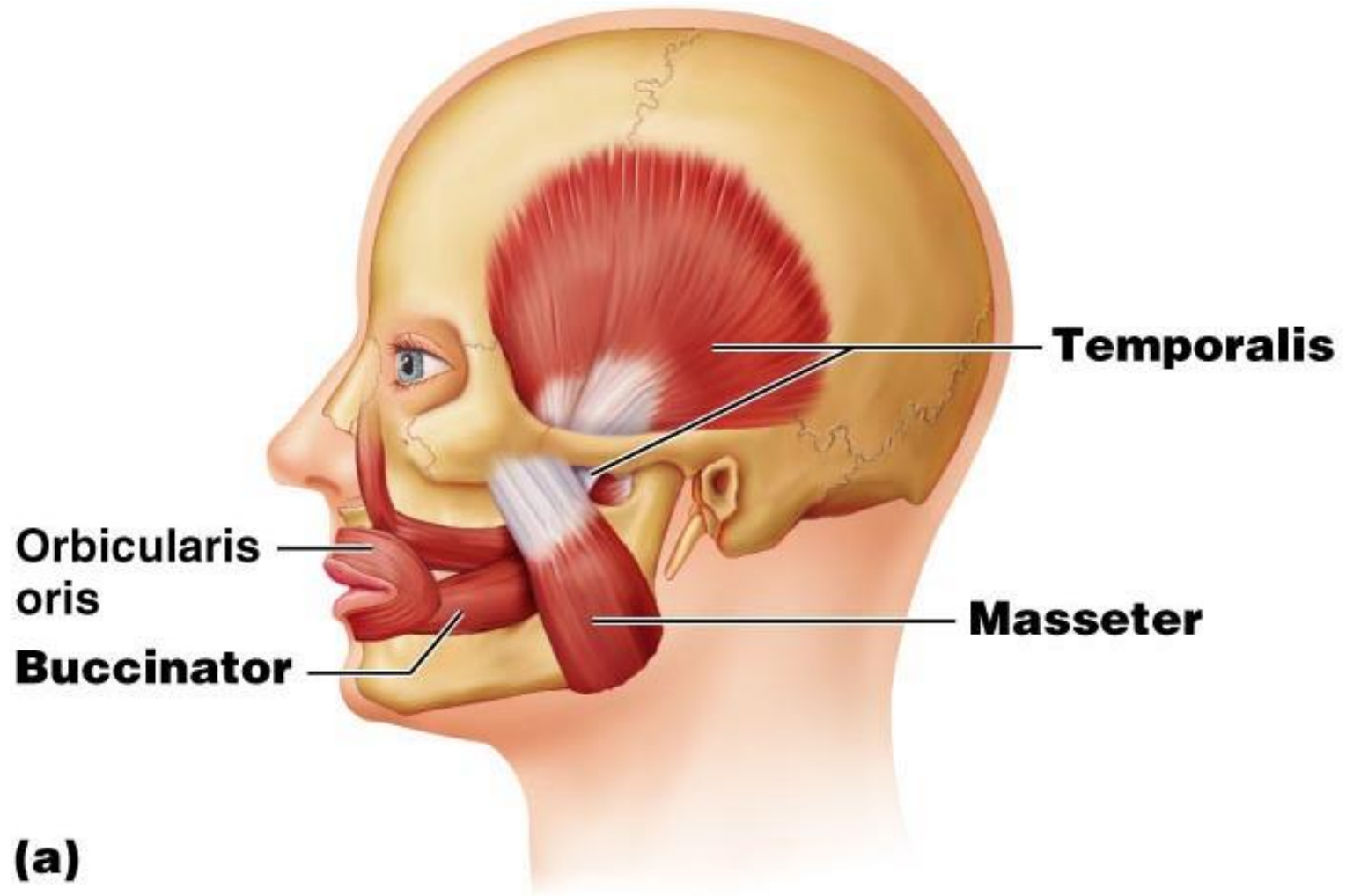
Muscles of the Scalp, Face, and Neck



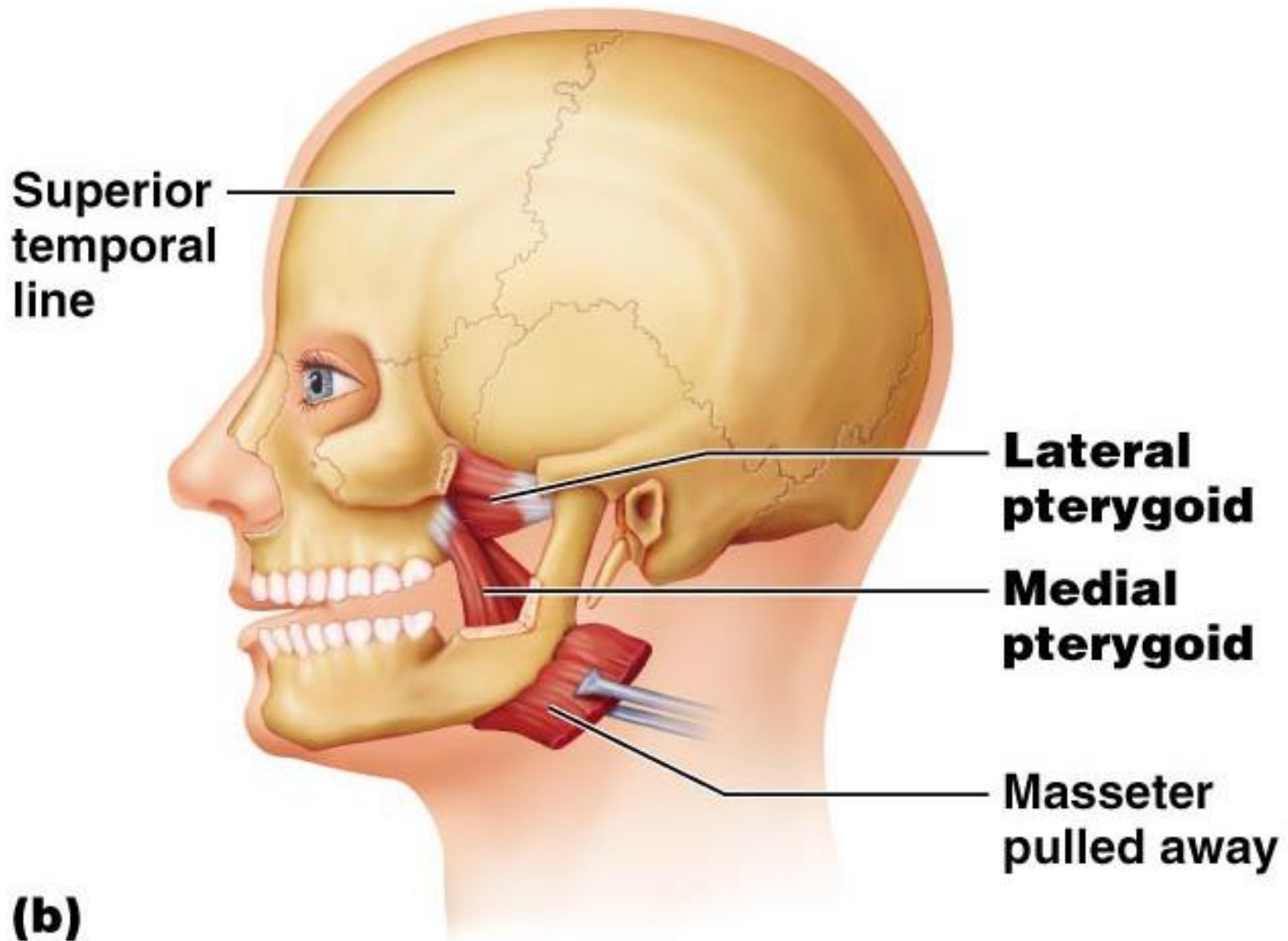
Muscles of Mastication

- There are four pairs of muscles involved in mastication
 - Prime movers – temporalis and masseter
 - Grinding movements – pterygoids and buccinators
- All are innervated by cranial nerve V (trigeminal nerve)

Muscles of Mastication



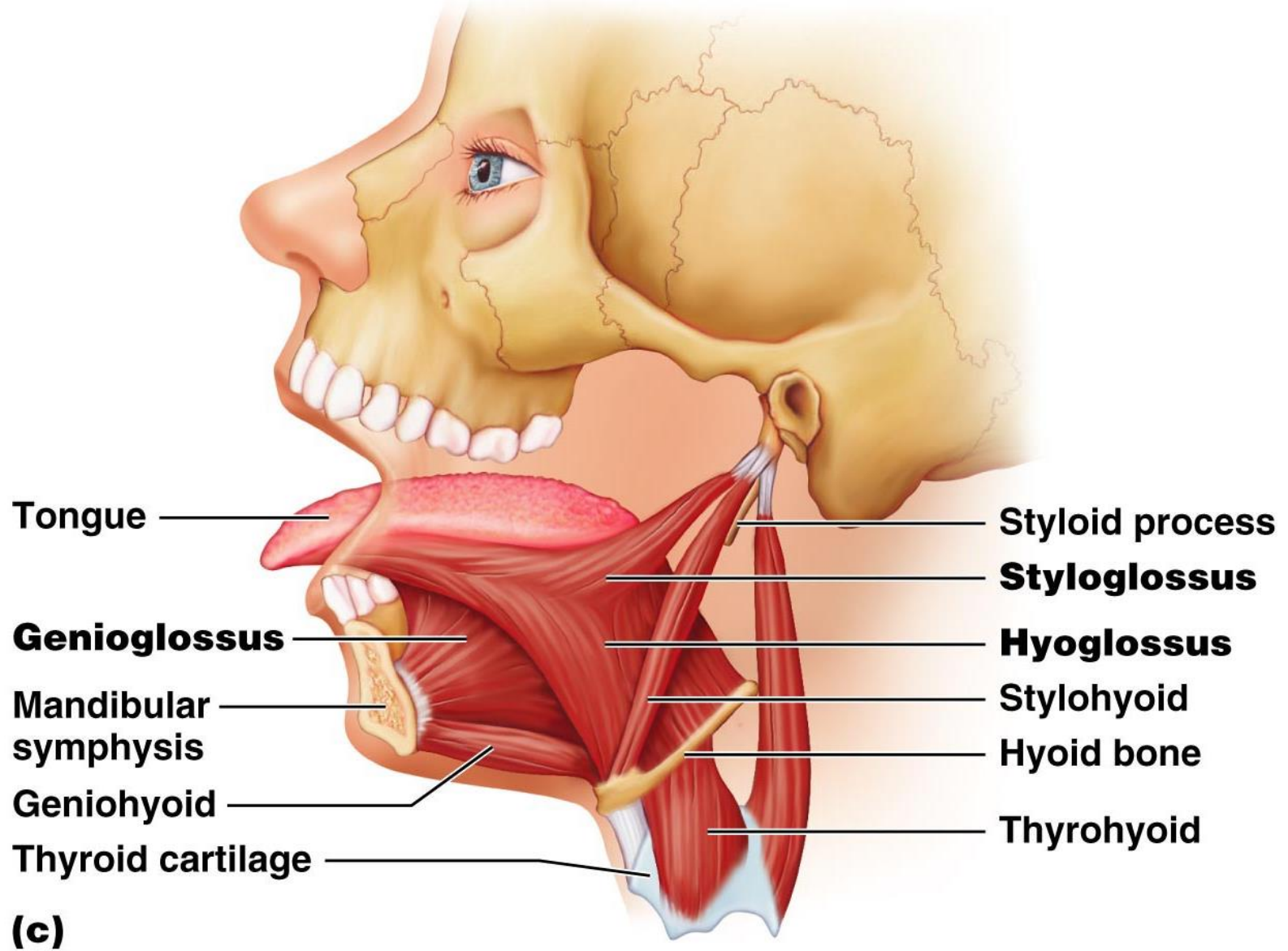
Muscles of Mastication



Extrinsic Tongue Muscles

- Three major muscles that anchor and move the tongue
- All are innervated by cranial nerve XII (hypoglossal nerve)

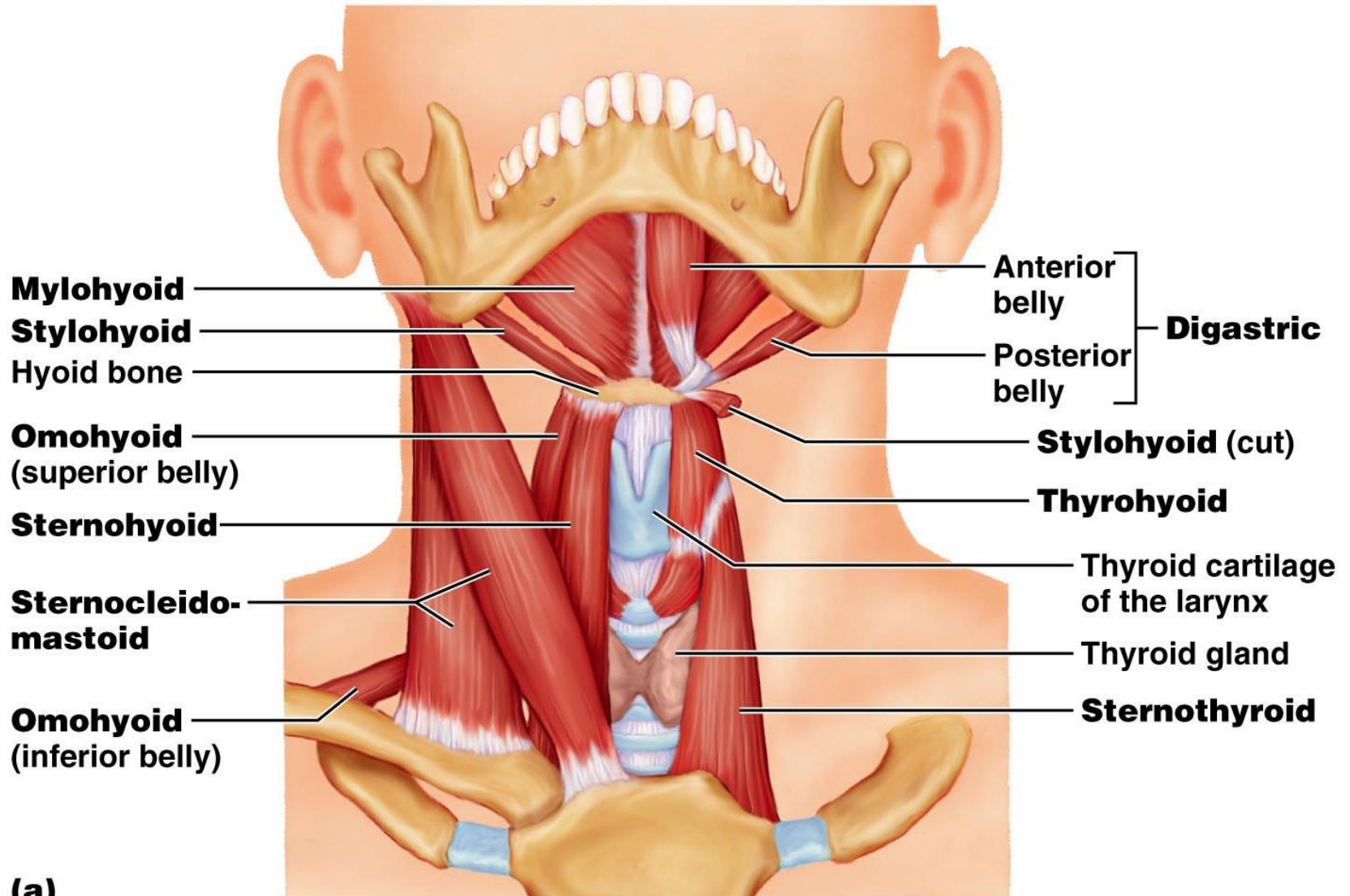
Extrinsic Tongue Muscles



Muscles of the Anterior Neck and Throat: Suprahyoid

- Four deep throat muscles
 - Form the floor of the oral cavity
 - Anchor the tongue
 - Elevate the hyoid
 - Move the larynx superiorly during swallowing

Muscles of the Anterior Neck and Throat: Suprahyoid

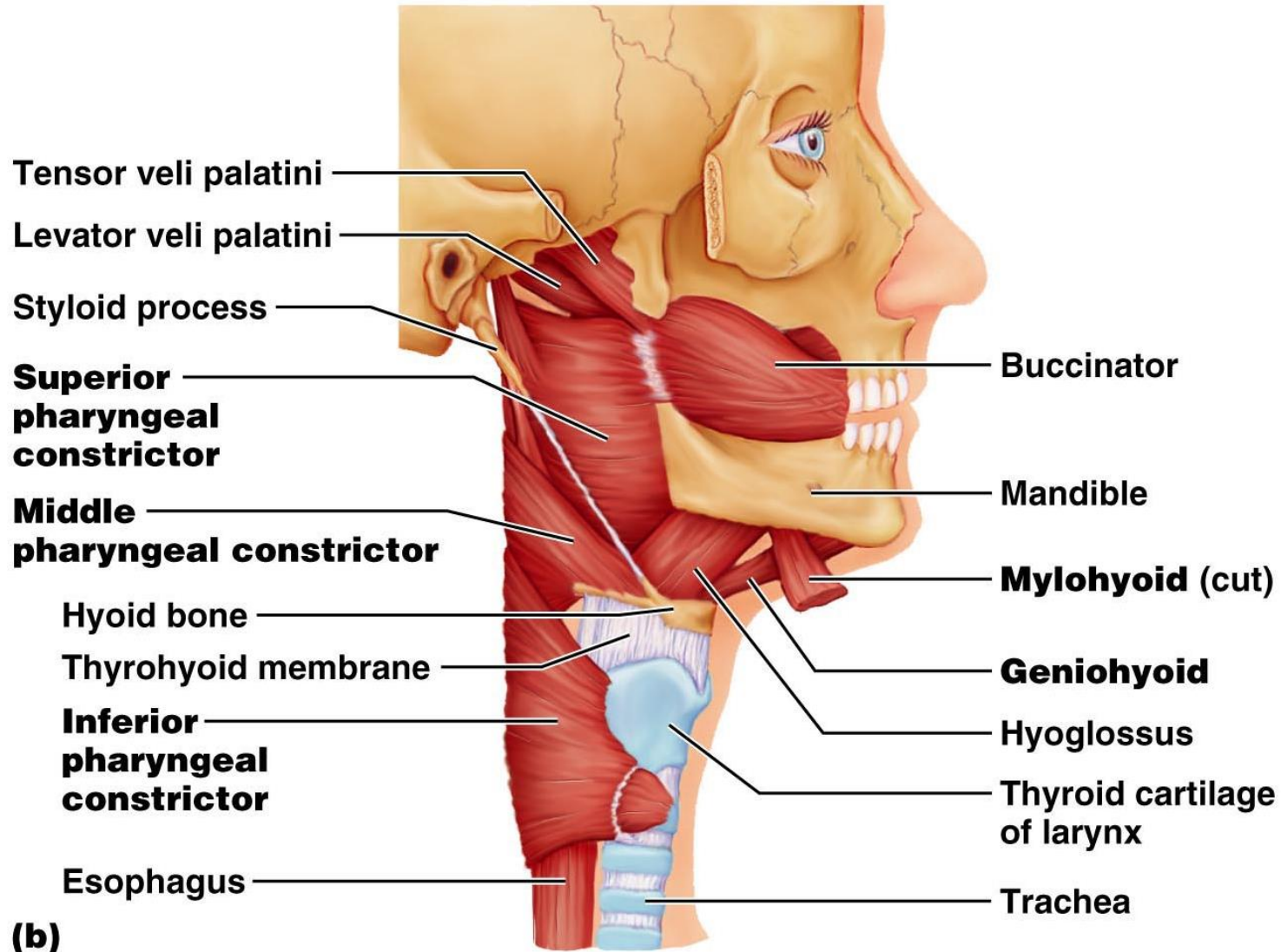


(a)

Muscles of the Anterior Neck and Throat: Infrahyoid

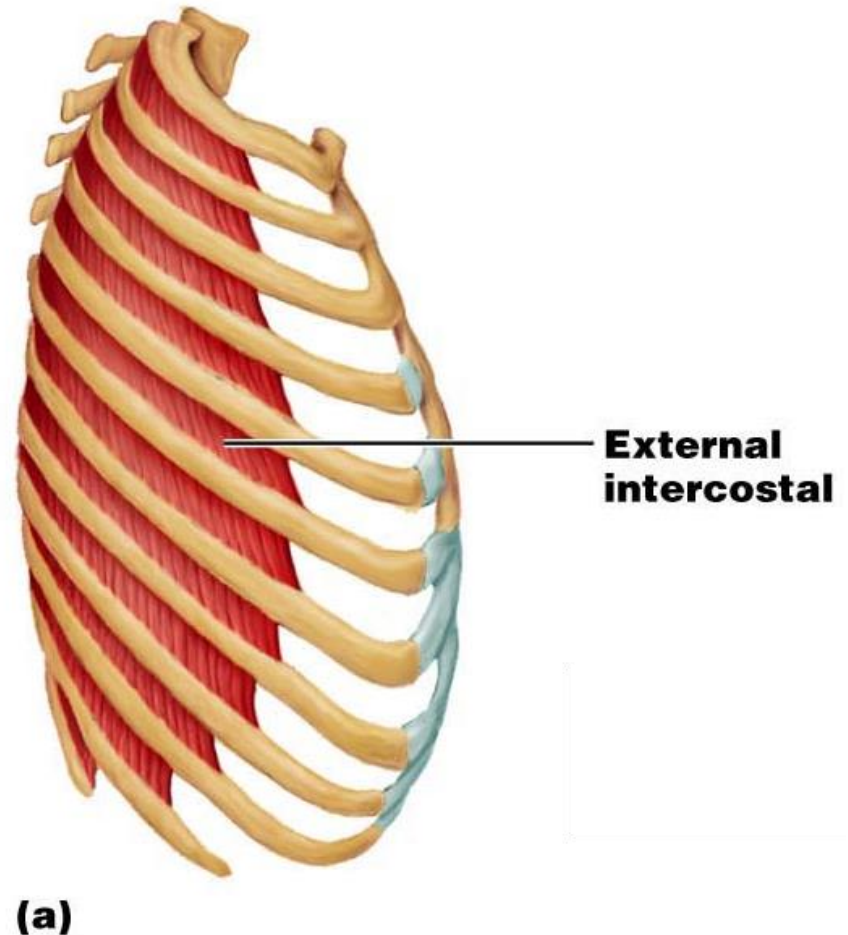
- Straplike muscles that depress the hyoid and larynx during swallowing and speaking

Muscles of the Anterior Neck and Throat: Infrahyoid



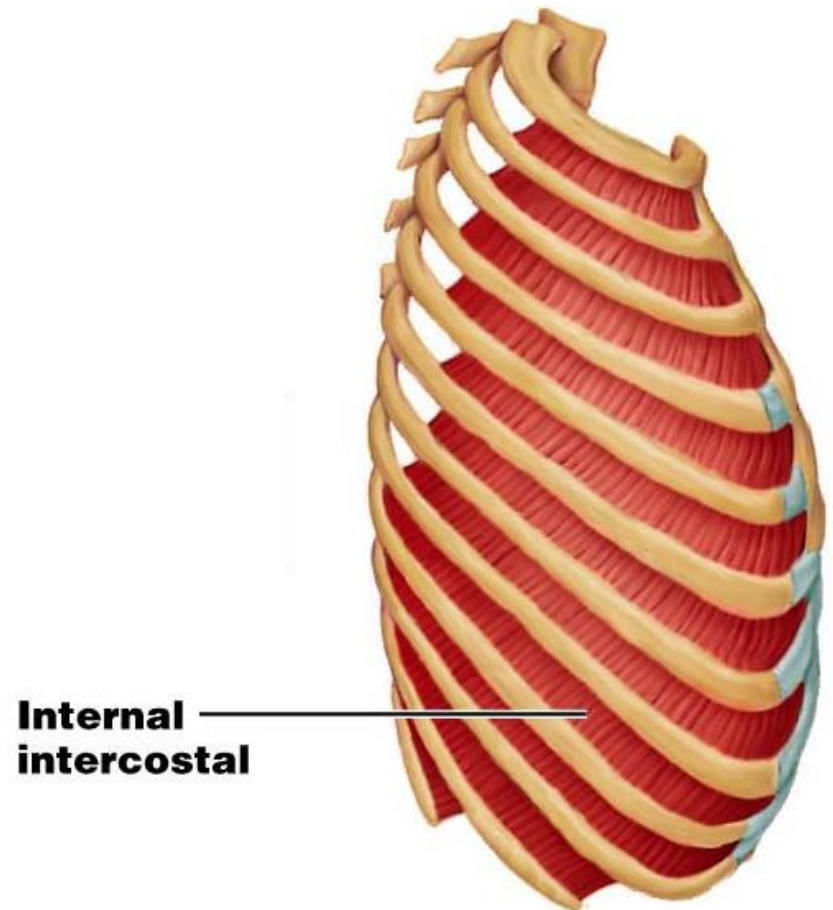
Muscles of Respiration: External Intercostals

- The primary function of deep thoracic muscles is to promote movement for breathing
- External intercostals – more superficial layer that lifts the rib cage and increases thoracic volume to allow inspiration



Muscles of Respiration: Internal Intercostals

- Internal intercostals – deeper layer that aids in forced expiration
- Diaphragm – most important muscle in inspiration



Muscles of Respiration: The Diaphragm

